Getting Started with Upper Gastrointestinal Tract Biopsies

Elizabeth Montgomery, MD

University of Miami Miller School of Medicine

Vice Chair, Academic Development

Outline/Objectives

- To discuss a simple consistent approach to biopsies from the upper gastrointestinal tract.
- To point out some “rookie” mistakes, artifacts, and pitfalls in each location

What is considered “upper”?

- Esophagus
- Stomach
- Small intestine (usually duodenum)

What is special about the upper tract?

- The lamina propria of the esophagus, stomach, and small intestine contains lymphatic vessels so carcinomas invading the lamina propria are staged as T1a
- Carcinomas invading the colorectal lamina propria are staged as Tis

Esophagus

- Esophageal biopsies often lack lamina propria because the normal esophageal mucosa is smooth, slippery and quite resilient thus making it difficult to biopsy
- If lamina propria is present, don’t mistake it for submucosa - This can lead to errors in determining the depth of invasion when confronted with an early invasive carcinoma!
- In general, lamina propria is only present on biopsies of esophageal squamous mucosa that is damaged (e.g. esophageal Crohn’s disease) and there is often only epithelium present in biopsies.

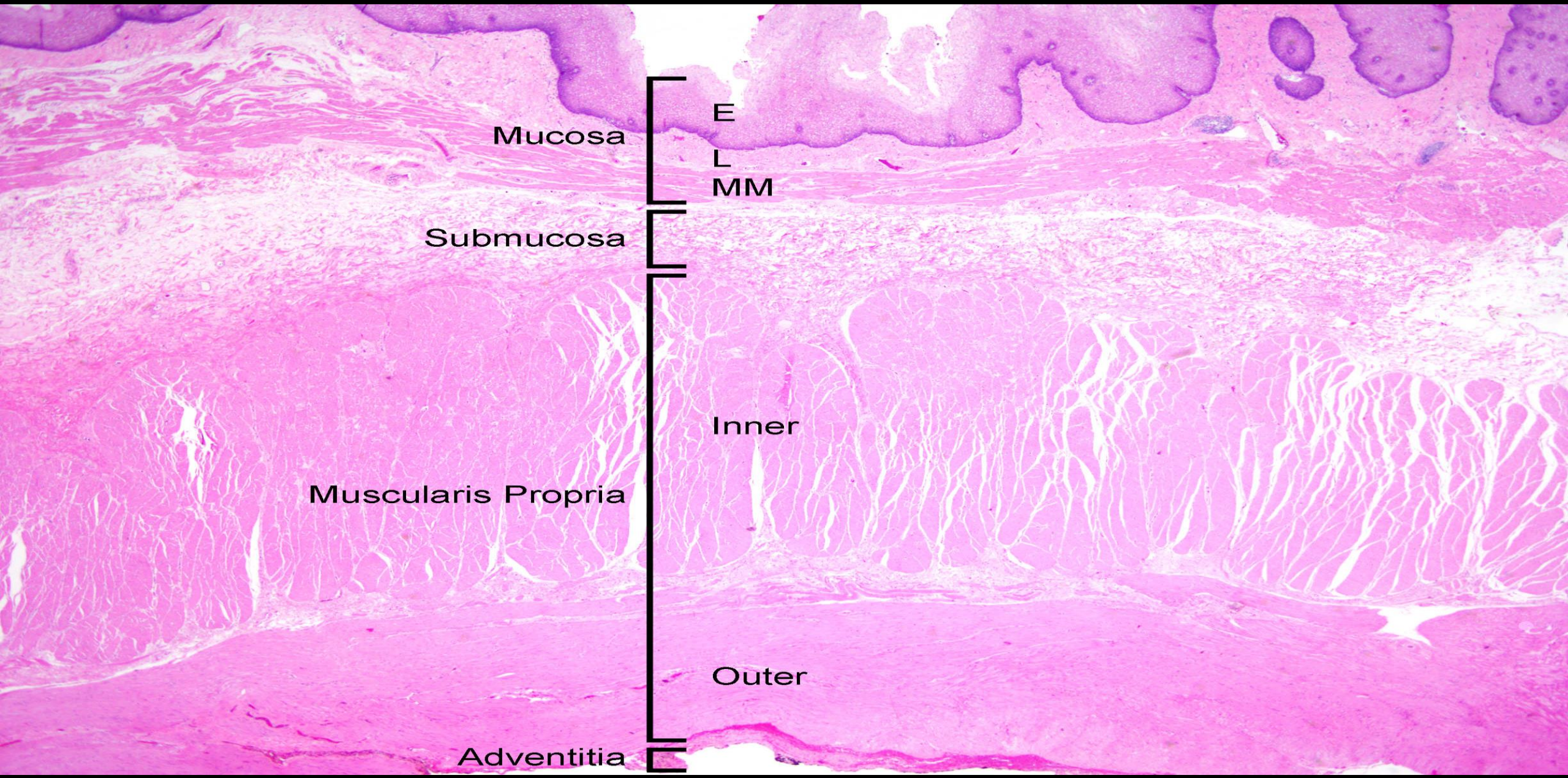
Mucosa
E
L
MM
Submucosa
Inner
Muscularis Propria
Outer
Adventitia

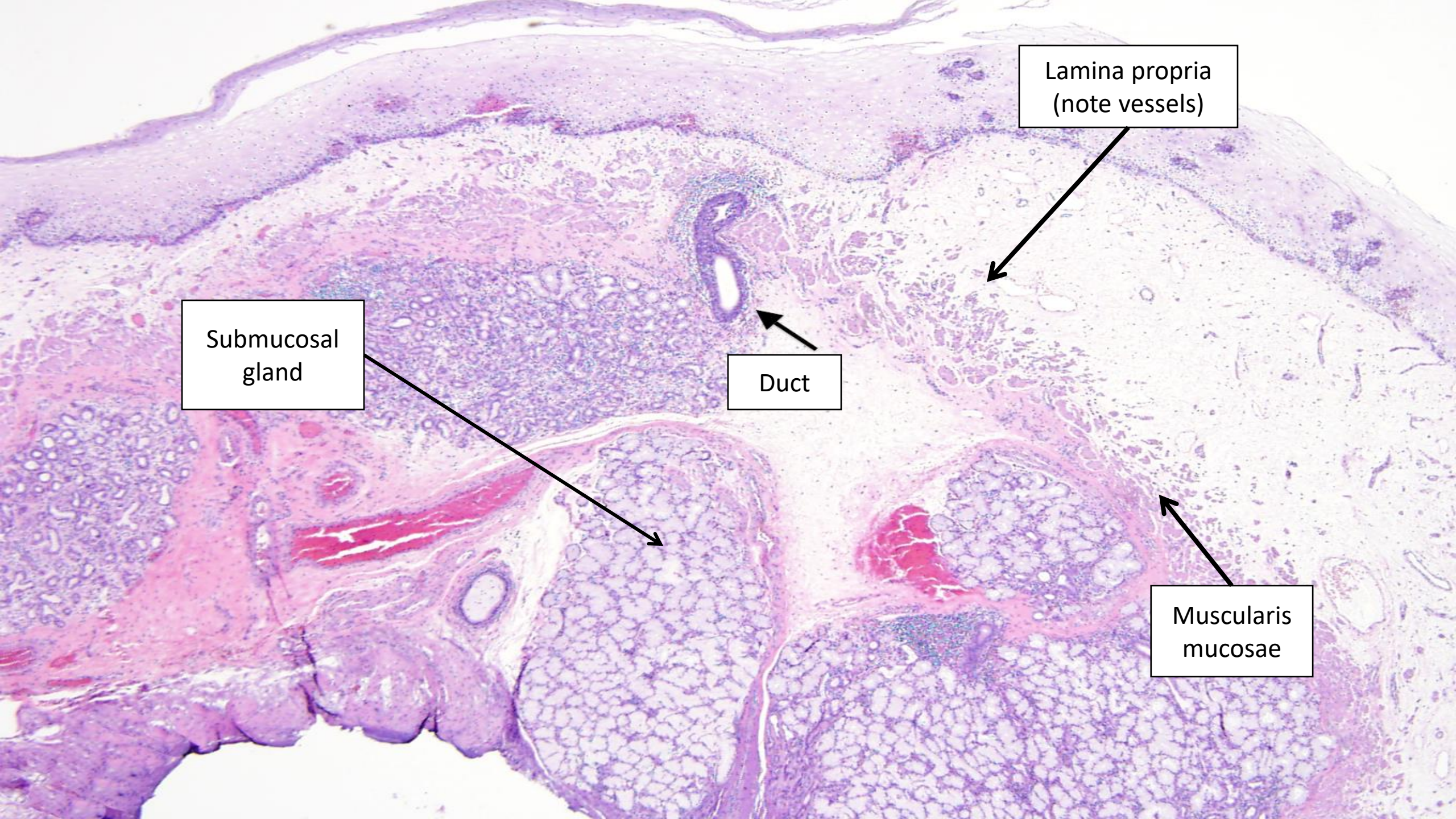
Lamina propria
(note vessels)
Submucosal
gland
Duct
Muscularis
mucosae

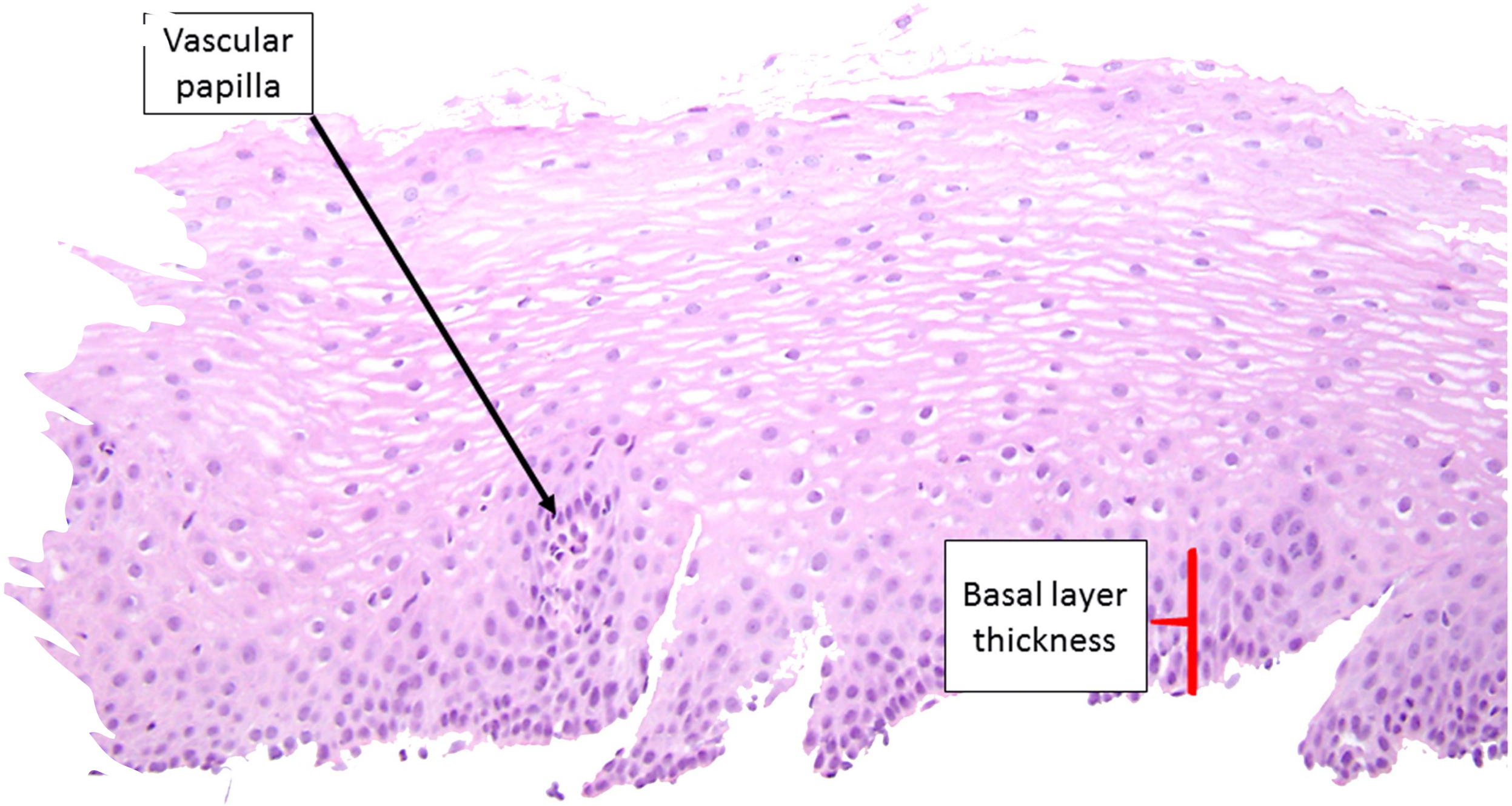
Vascular papilla
Basal layer thickness

This sample shows gastric cardiac type mucosa but we know that it is from the tubular esophagus (and thus metaplastic) because of the presence of esophageal ducts and submucosal glands

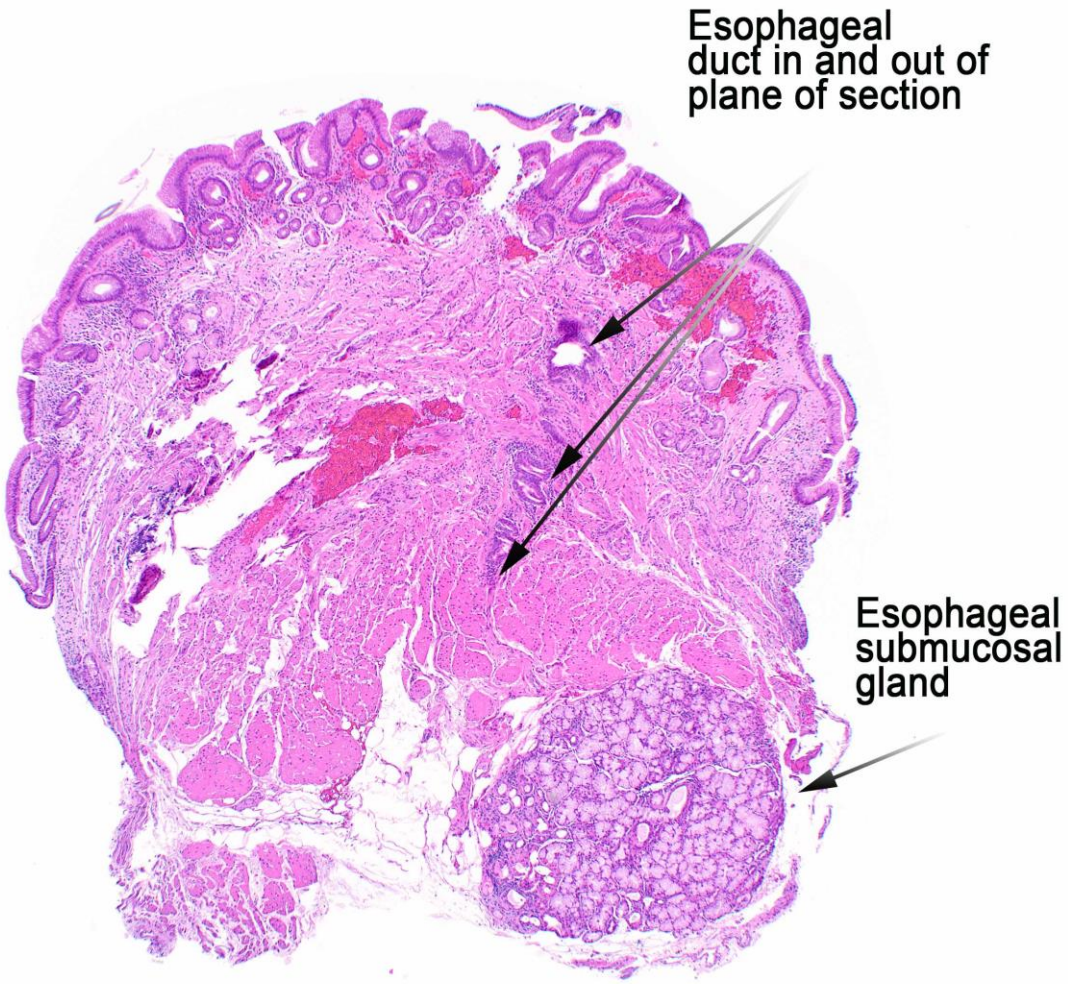

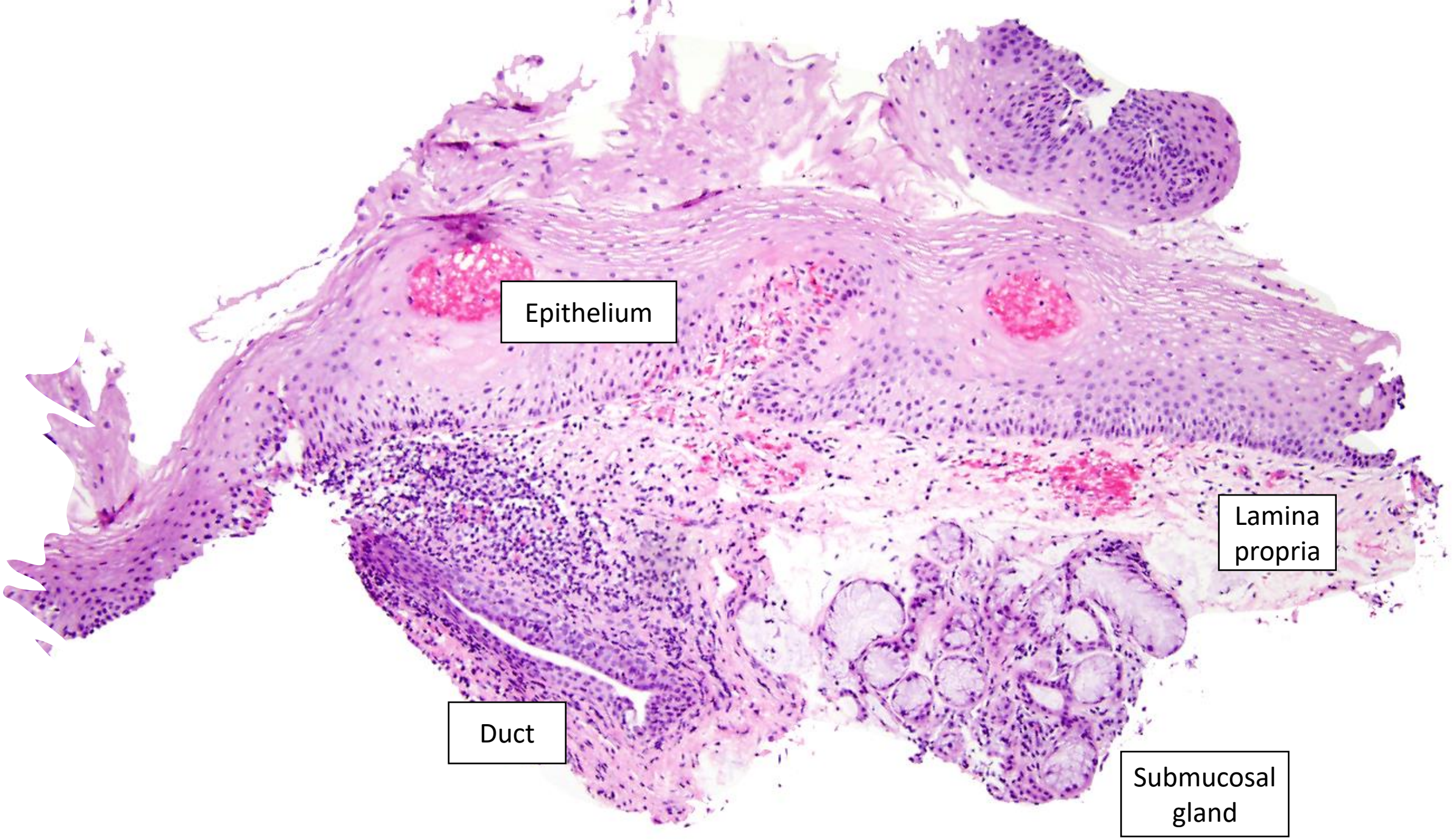
Epithelium
Lamina propria
Duct
Submucosal gland

Pancreatic heterotopia and multilayered epithelium

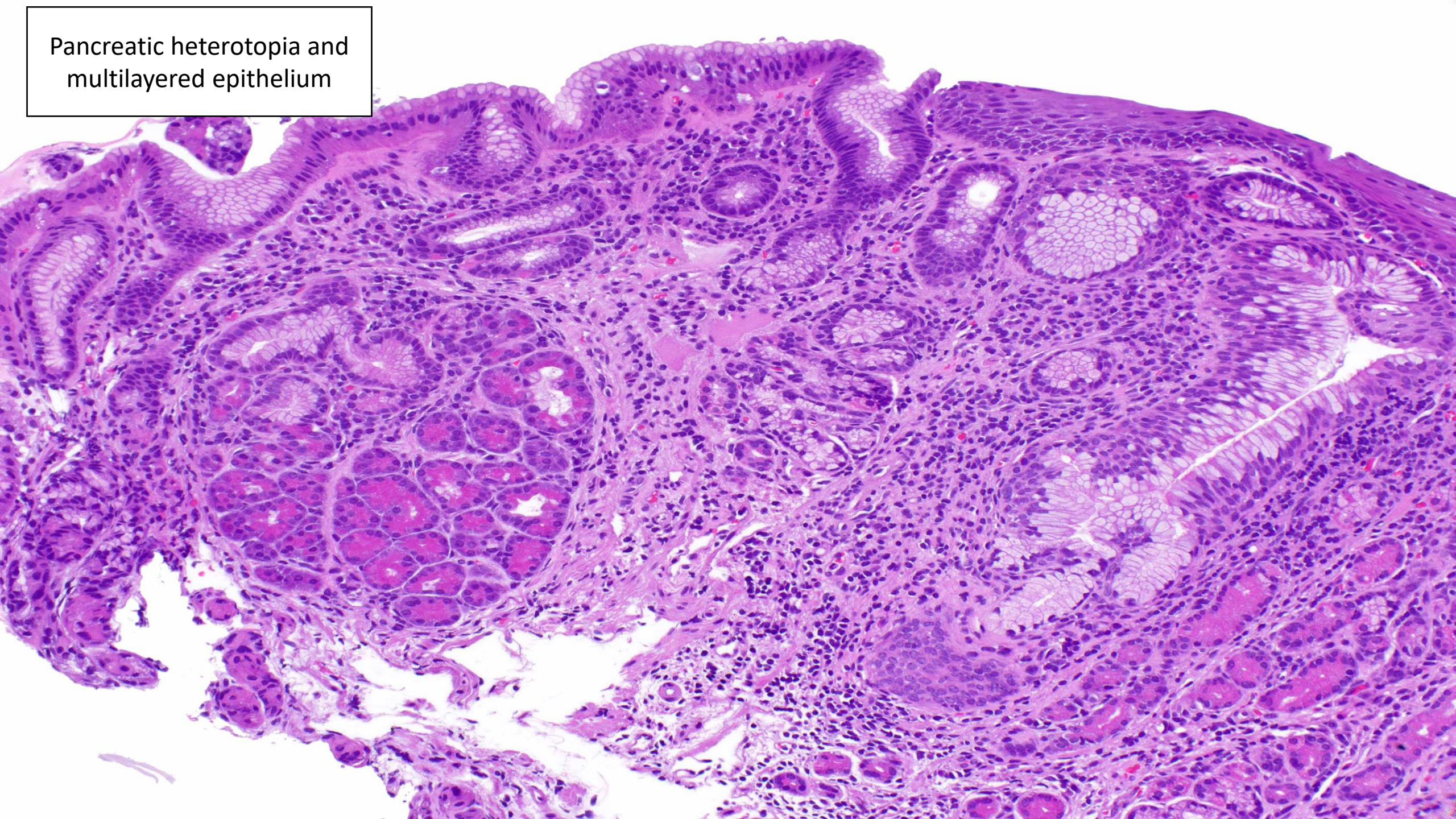

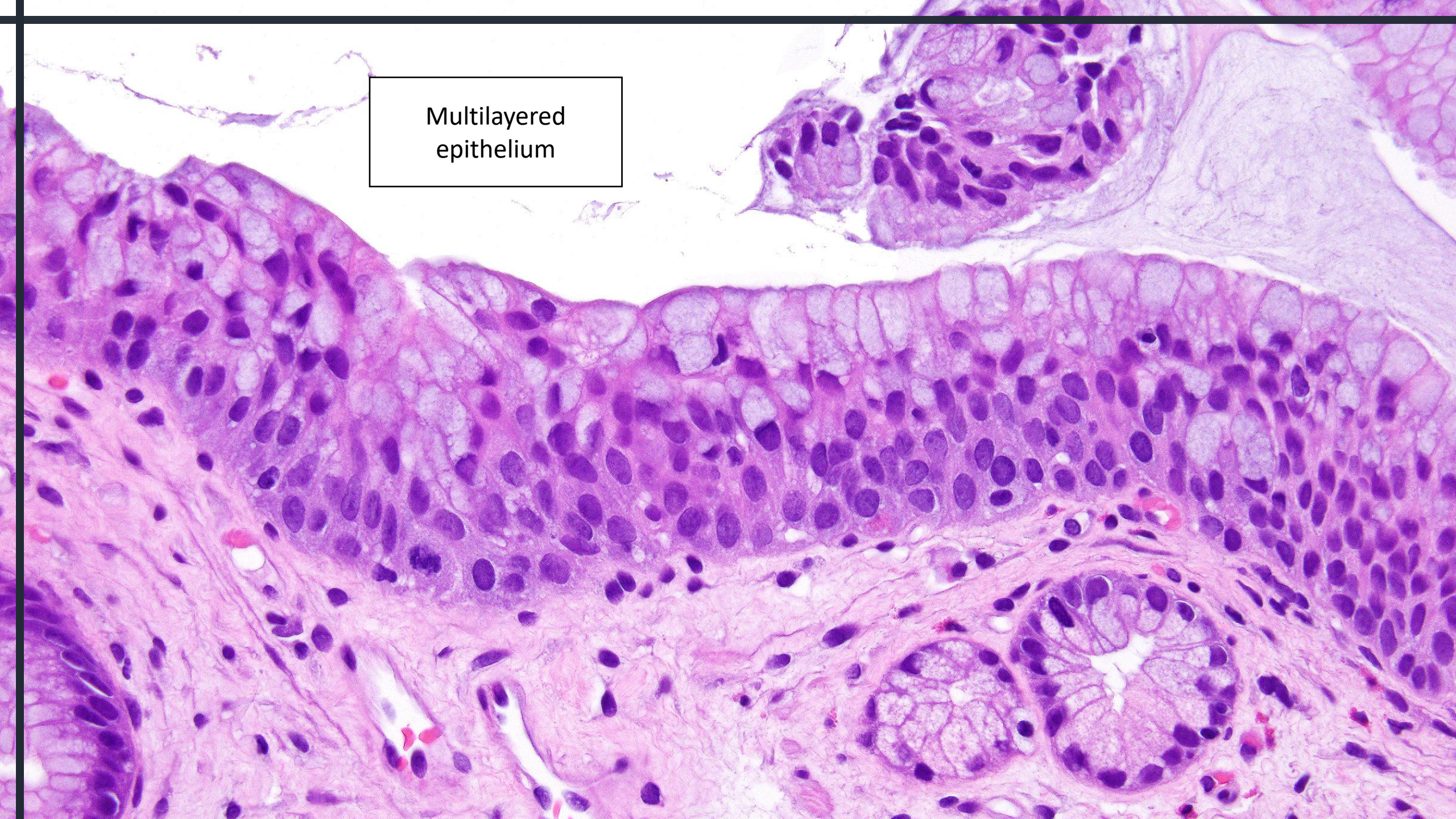
Multilayered epithelium

Esophageal Injury

1. Intraepithelial eosinophils
2. Intraepithelial lymphocytes with or without apoptotic bodies
3. Ulcers and erosions (often with neutrophils)
4. Apoptotic injury
5. Hyperkeratosis
6. Acanthosis
7. Proliferation

Eosinophils

- Eosinophils should be absent in esophageal epithelium
- Of course the issue is always reflux versus eosinophilic esophagitis (allergic disease).
- If there is striking basal cell hyperplasia at low magnification and eosinophils are numerous (generally no need to count them, although some institutions and guidelines require a number per mm^2), the patient has eosinophilic esophagitis.
- The diagnosis of eosinophilic esophagitis is further confirmed if there are any eosinophils in the middle or upper esophagus, eosinophilic micro-abscesses or eosinophils within the most apical epithelial layers.

14/2007
33:35
-17

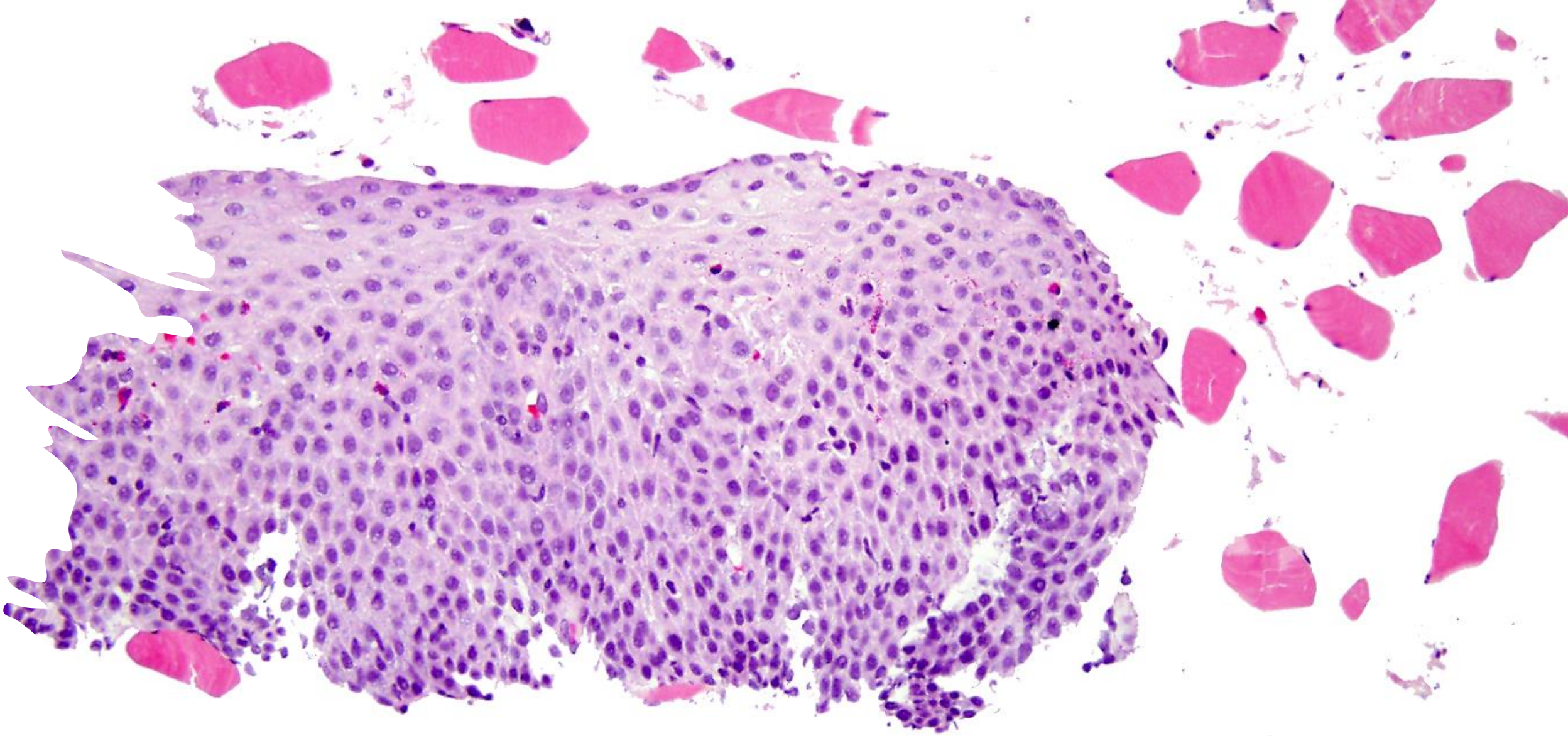

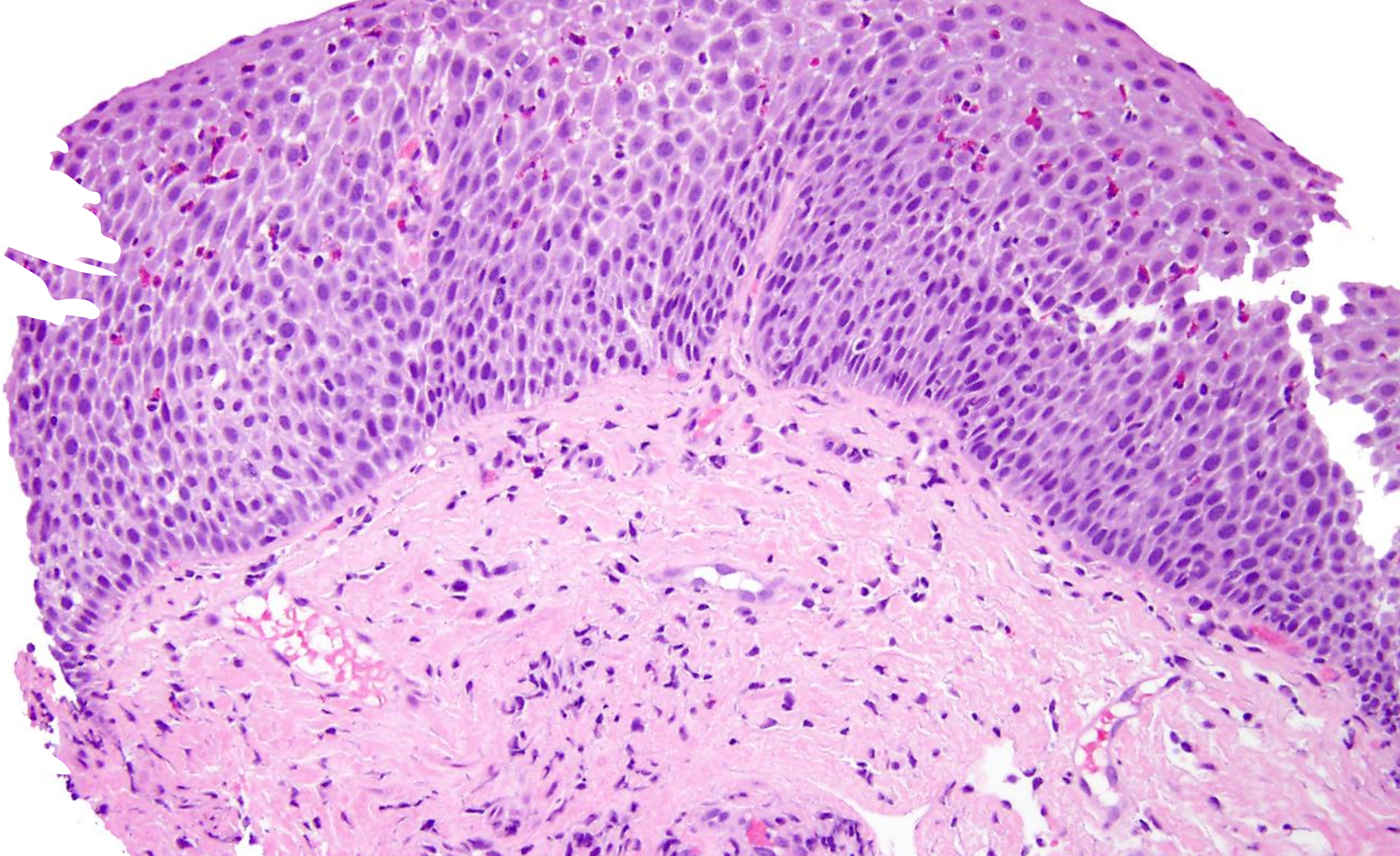

Eosinophils

- If there is only slight basal cell hyperplasia and a search is required to find eosinophils, the patient has reflux disease.
- In the mid and upper esophagus, even a single eosinophil is abnormal and probably a sign of eosinophilic esophagitis with patchy eosinophil distribution.
- If the endoscopist has sampled all three locations: the upper, mid and distal esophagus and eosinophils are plentiful, the patient probably has eosinophilic esophagitis.
- Society guidelines suggest 15 eosinophils per high power field or 60 per mm^2 as a cutoff for eosinophilic esophagitis **in the correct clinical setting (with symptoms and characteristic endoscopic findings.**
- More recently, a correlation between accompanying mast cells in patients with eosinophilic esophagitis and persistent symptoms has been noted; This also correlated with lamina propria fibrosis, which persists for some time after a treatment-associated reduction in the patient's esophageal eosinophils

Eosinophils

- Sometimes there is no information! The following style of report can be offered:
- "Squamous mucosa with reactive epithelial changes with up to X eosinophils per high power field/mm^2. Please consider obtaining biopsies from the upper, mid and distal esophagus in three separate containers during the next endoscopic follow-up to confirm or exclude eosinophilic esophagitis if symptoms or characteristic endoscopic features are present."

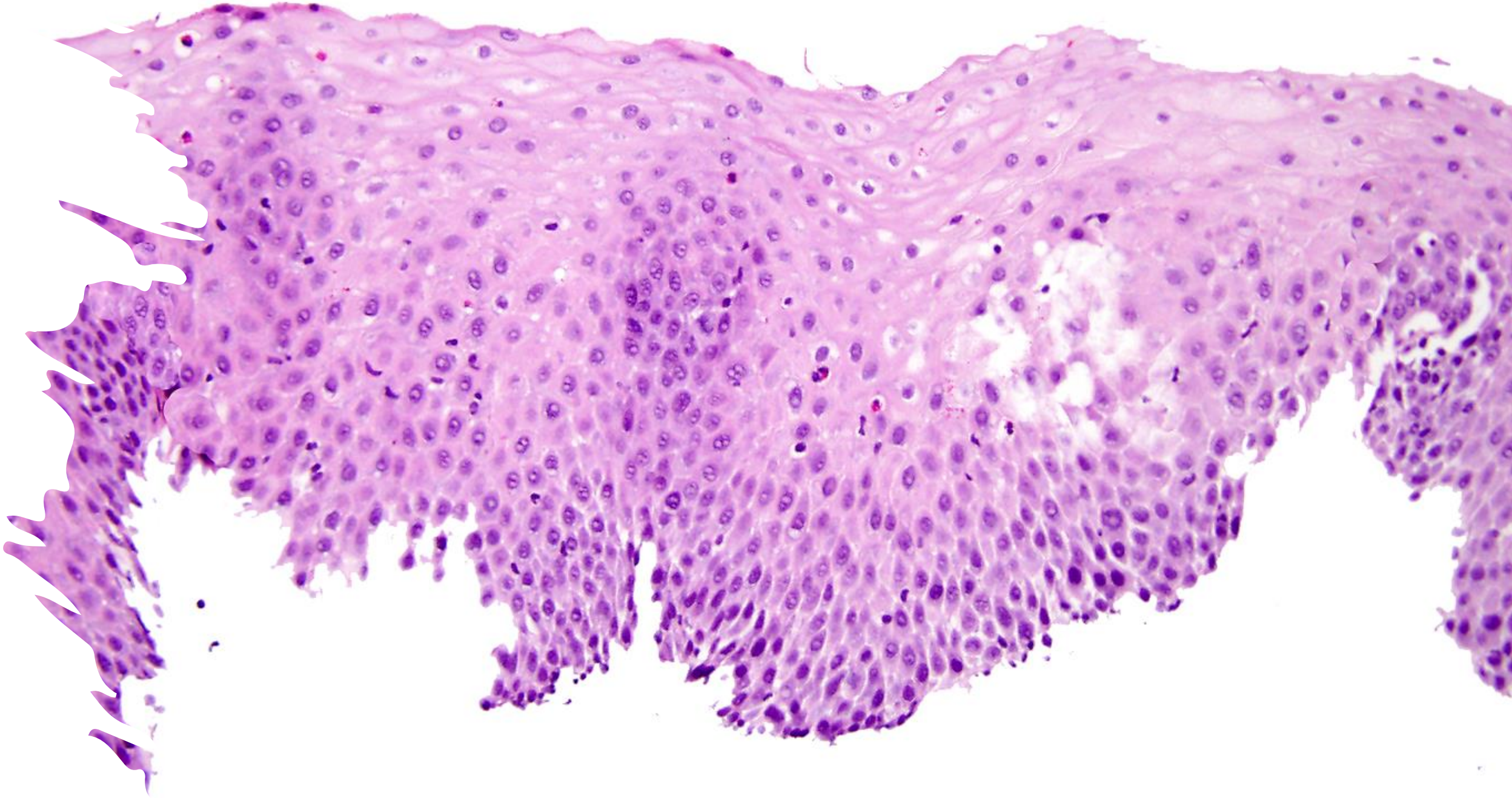

Lymphocytes!

- Usually attributable to reflux in adults!
- Commonly associated with Crohn's disease in children.

- Dunbar KB, Agoston AT, Odze RD, et al. Association of Acute Gastroesophageal Reflux Disease With Esophageal Histologic Changes. *JAMA*. 2016;315(19):2104-2112.

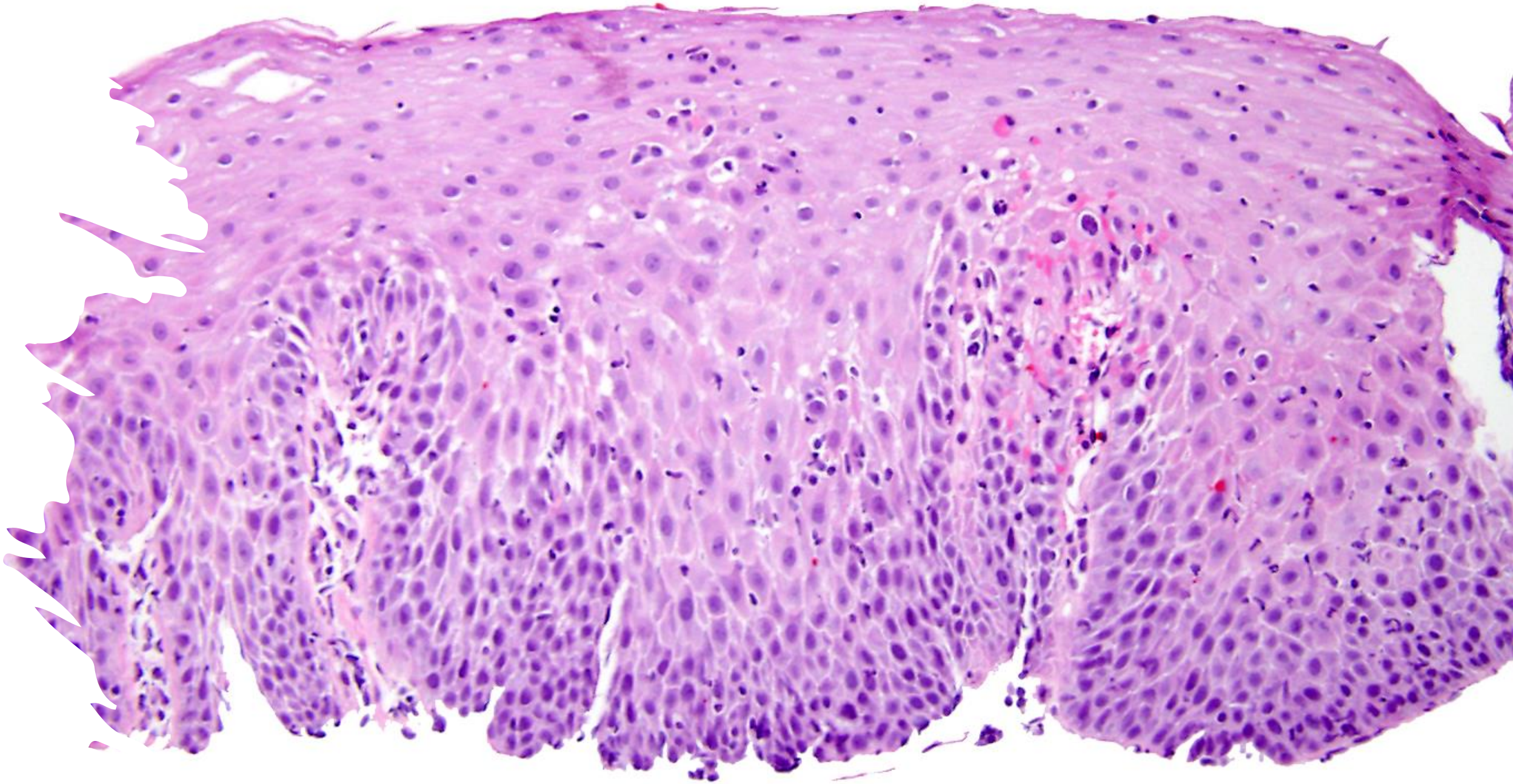

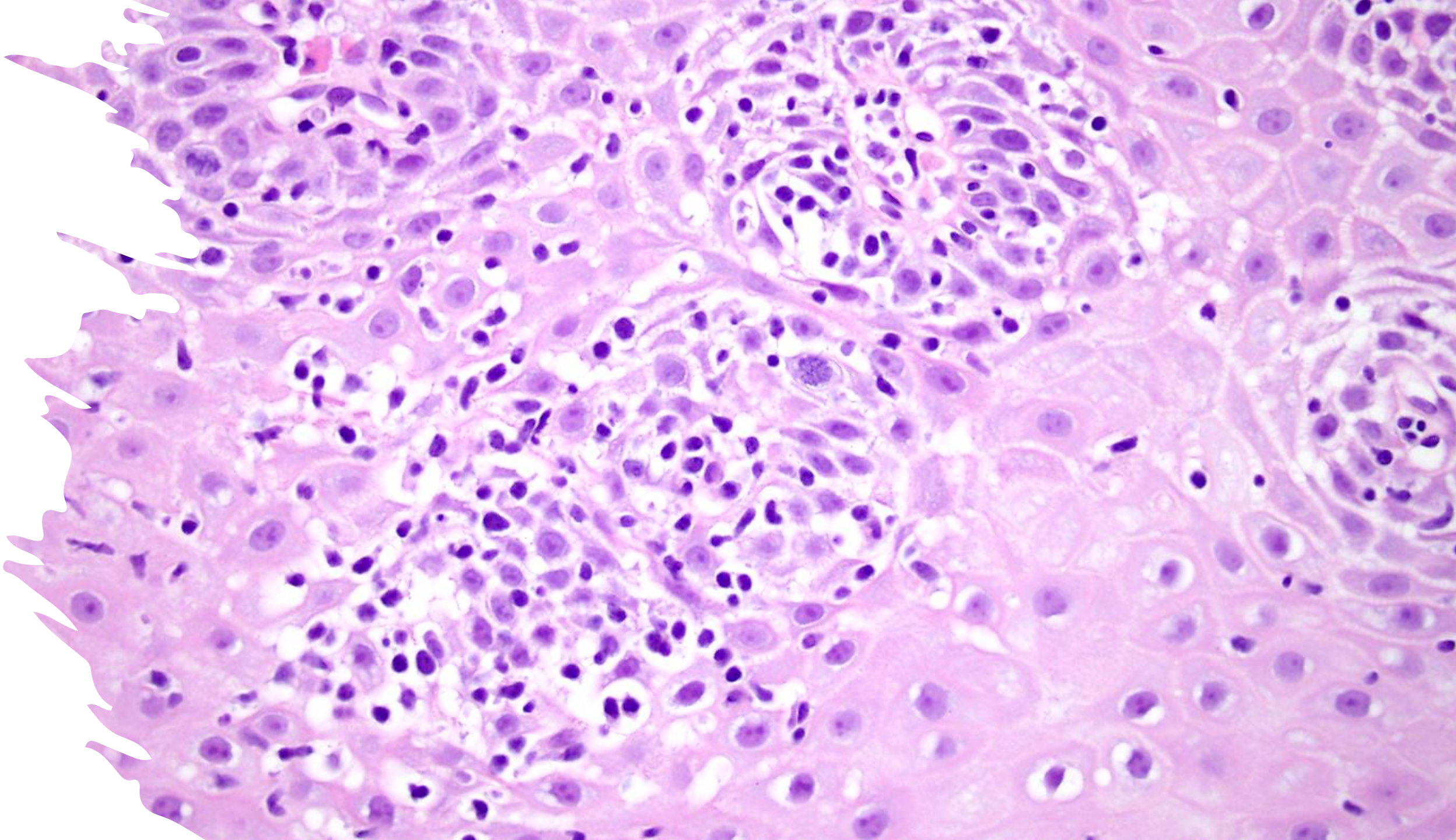

Lymphocytosis with apoptosis

- Invariably in adults
- Lichen planus
- Immune disorders
- Immunotherapy

- Pittman ME, Hissong E, Katz PO, Yantiss RK. Lymphocyte-predominant Esophagitis: A Distinct and Likely Immune-mediated Disorder Encompassing Lymphocytic and Lichenoid Esophagitis. *Am J Surg Pathol.* 2020;44(2):198-205.
- Salaria SN, Abu Alfa AK, Cruise MW, Wood LD, Montgomery EA. Lichenoid esophagitis: clinicopathologic overlap with established esophageal lichen planus. Am J Surg Pathol. 2013 Dec;37(12):1889-94. PMID: 24061525.

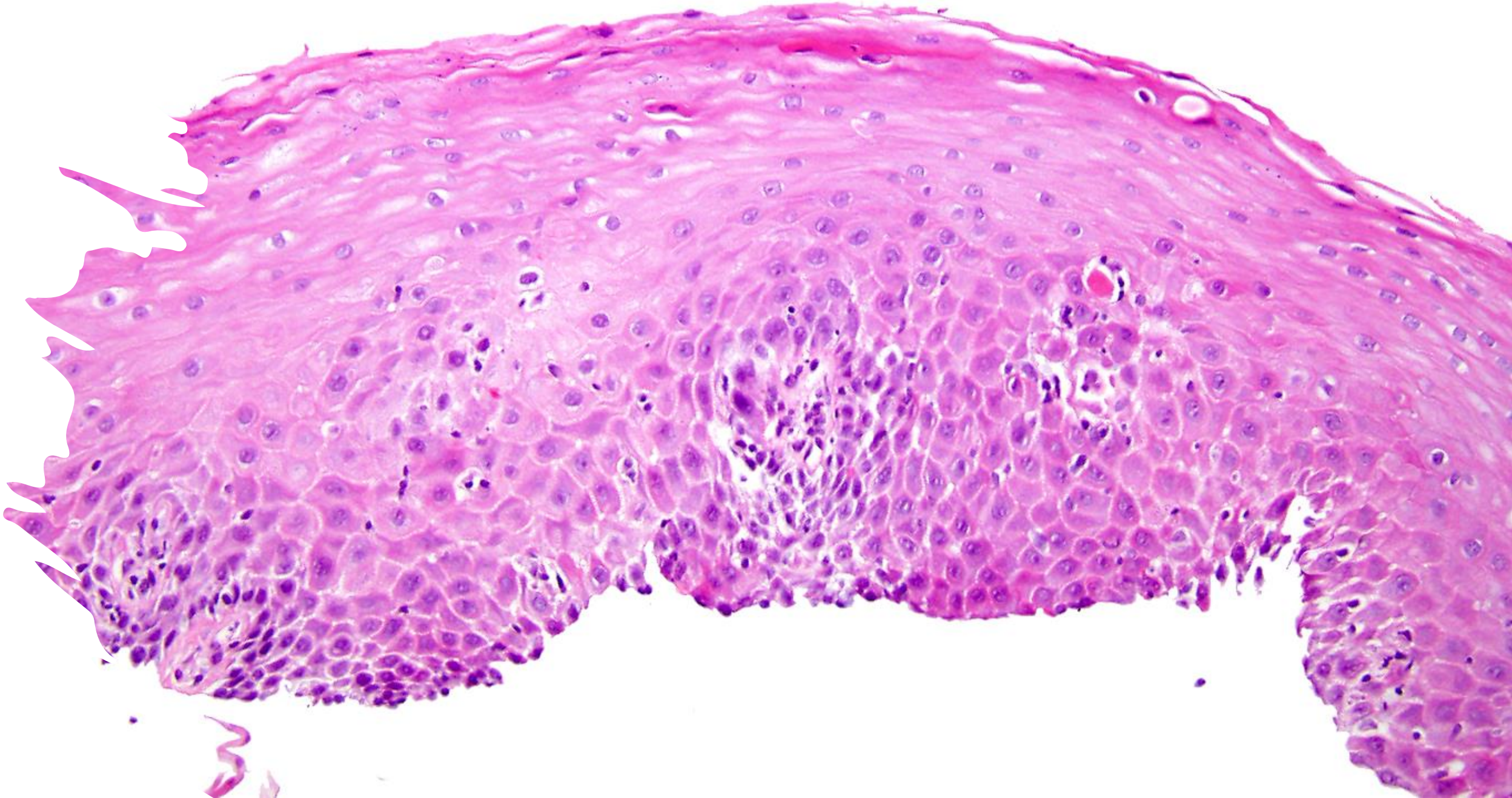

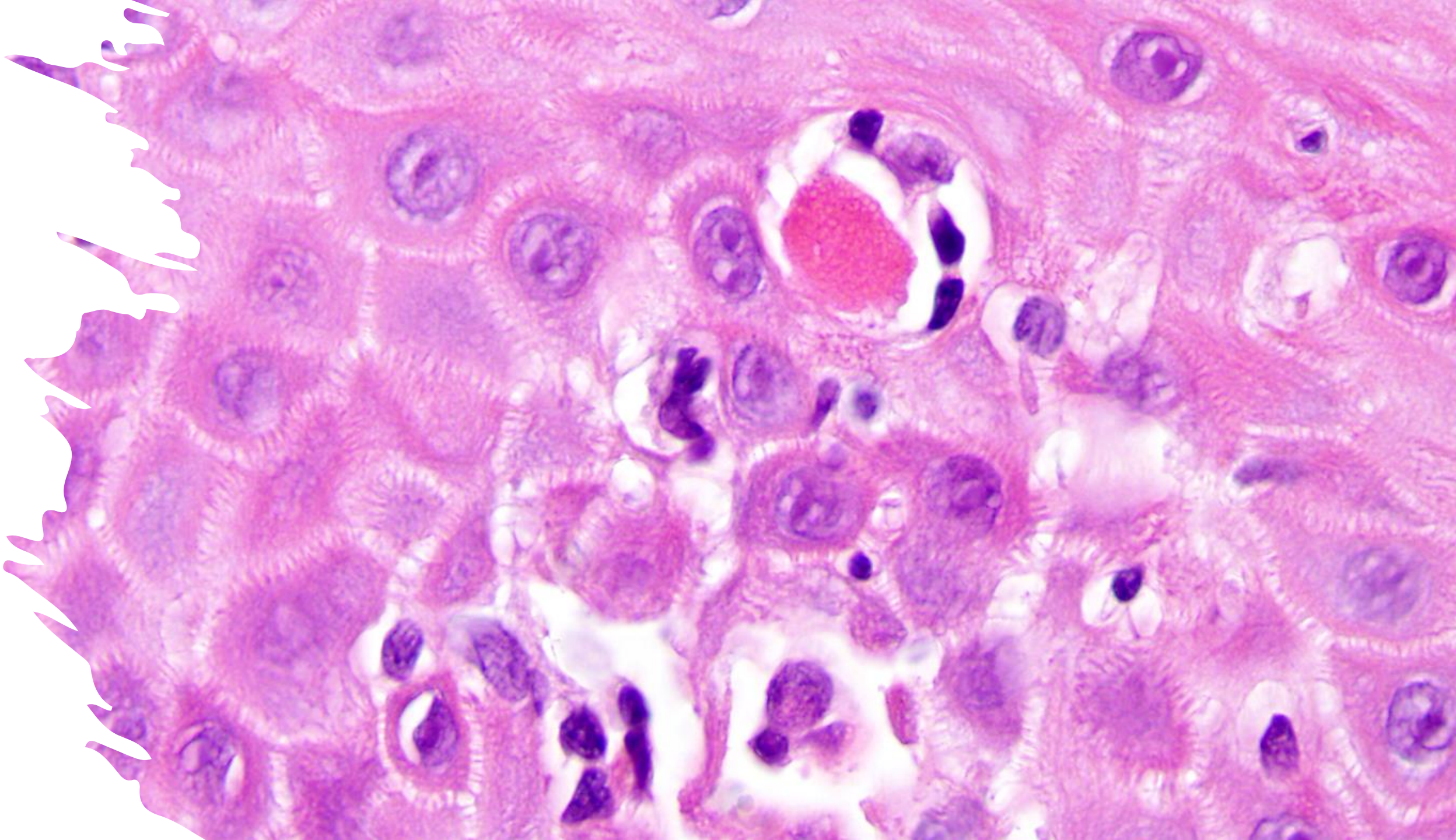

Ulcers and Erosions

- Infections –
- *Candida*
- viral diseases
- Medications (iron, kayexalate, doxycycline, pills themselves)

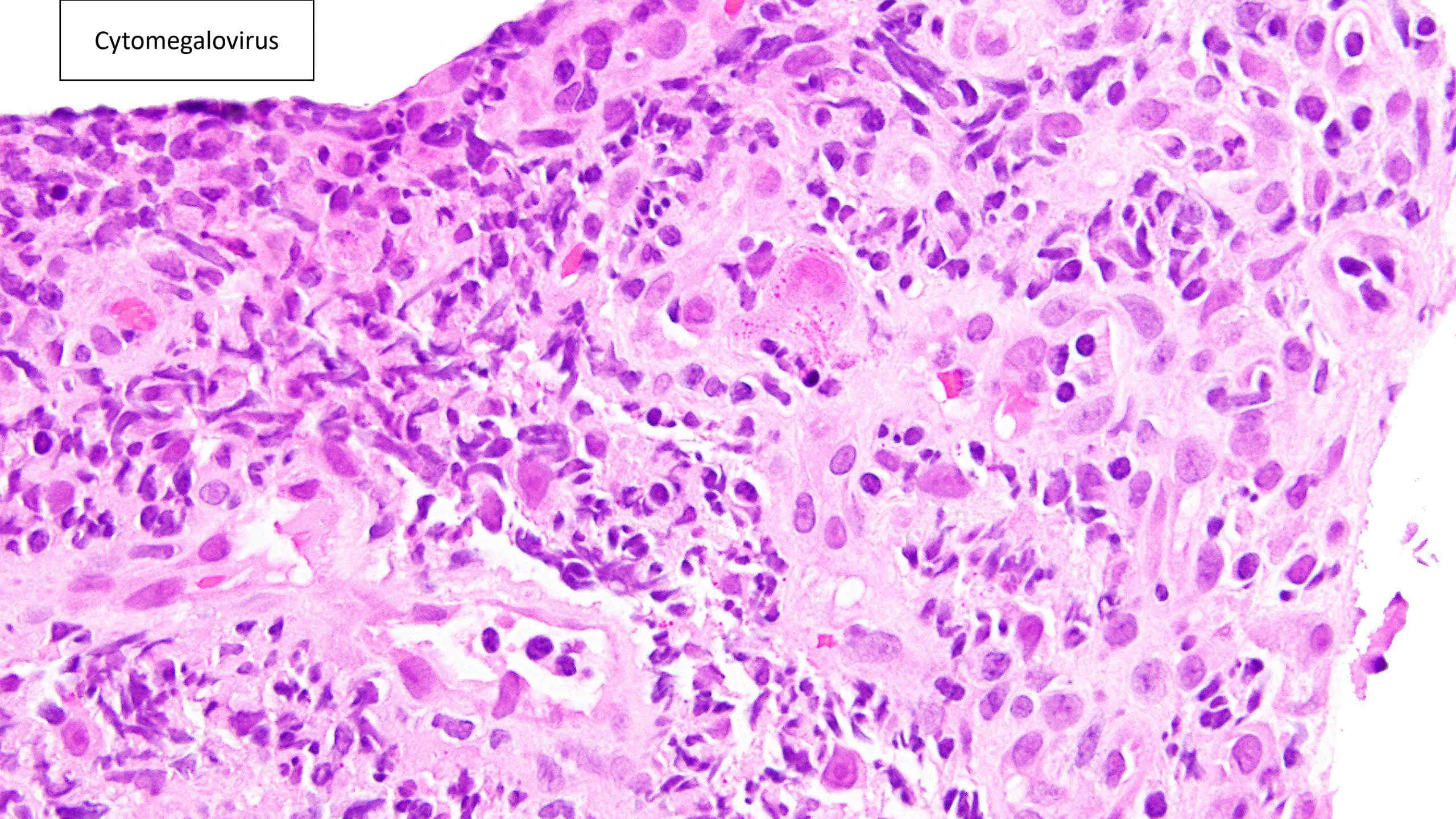
Cytomegalovirus

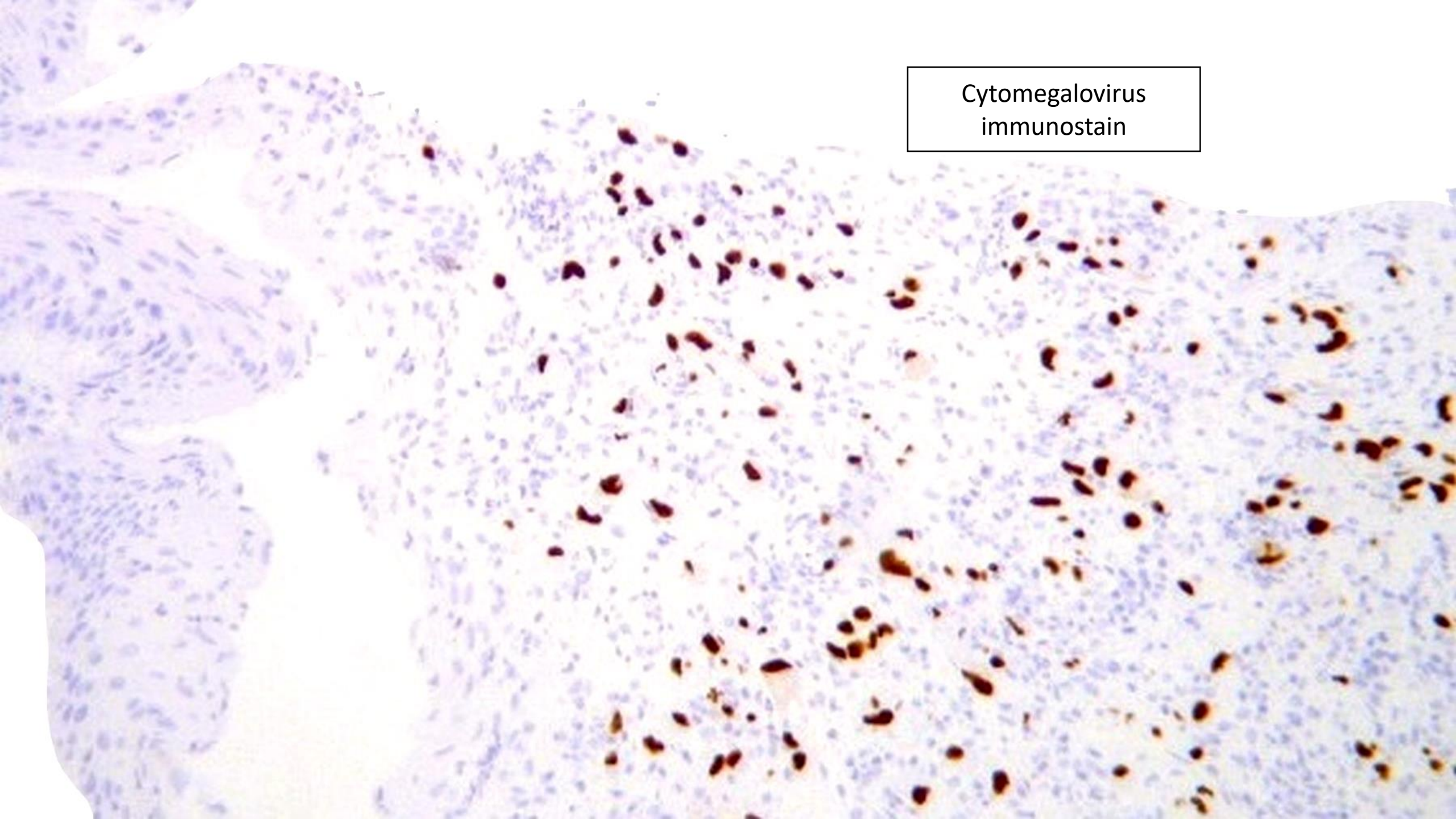
Cytomegalovirus
immunostain

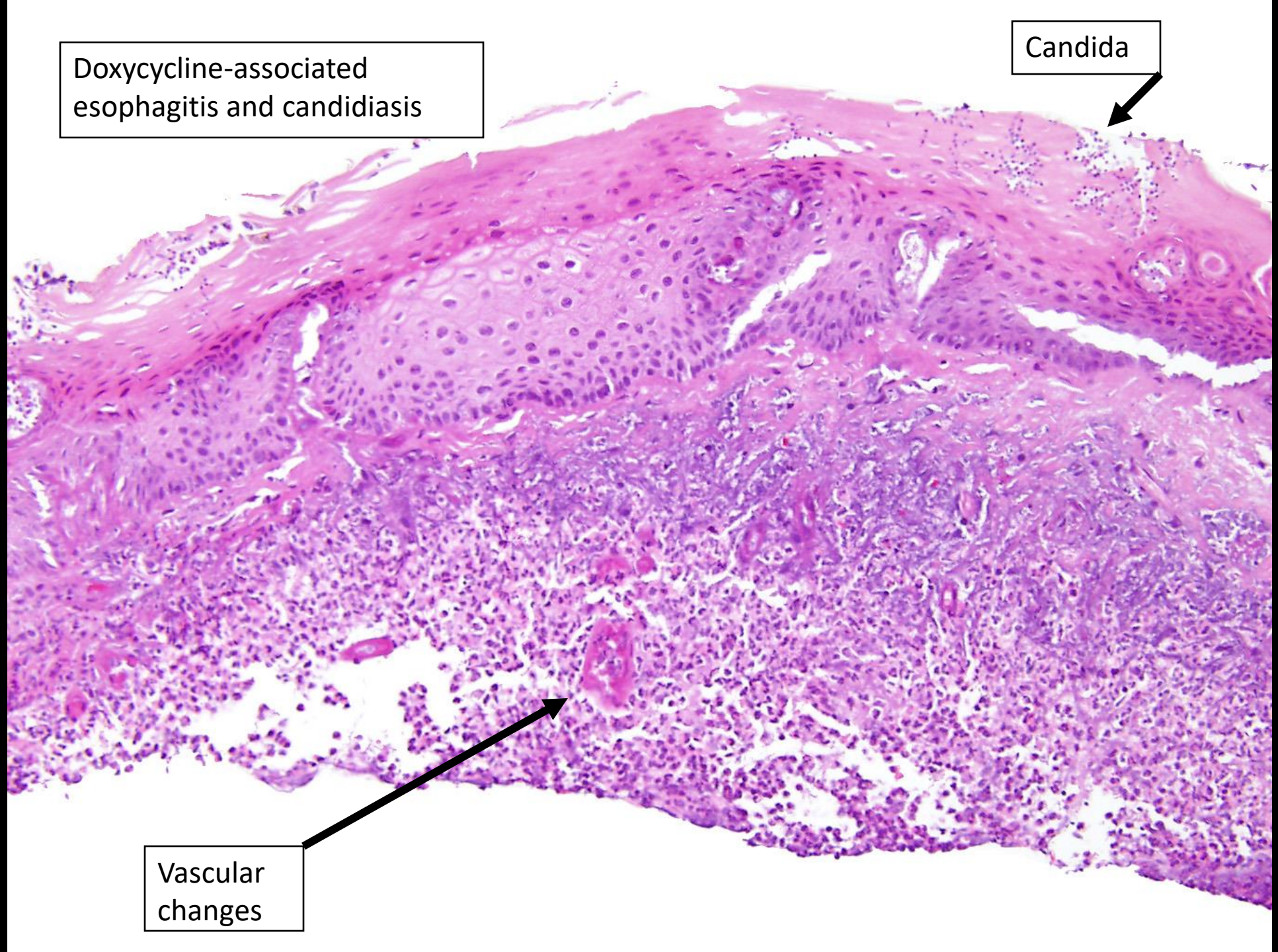
Doxycycline-associated esophagitis and candidiasis
Candida
Vascular changes

Apoptotic injury (often without lymphocytosis)

- Graft versus host disease
- Medications (immunotherapy, mycophenolate)
- Radiation

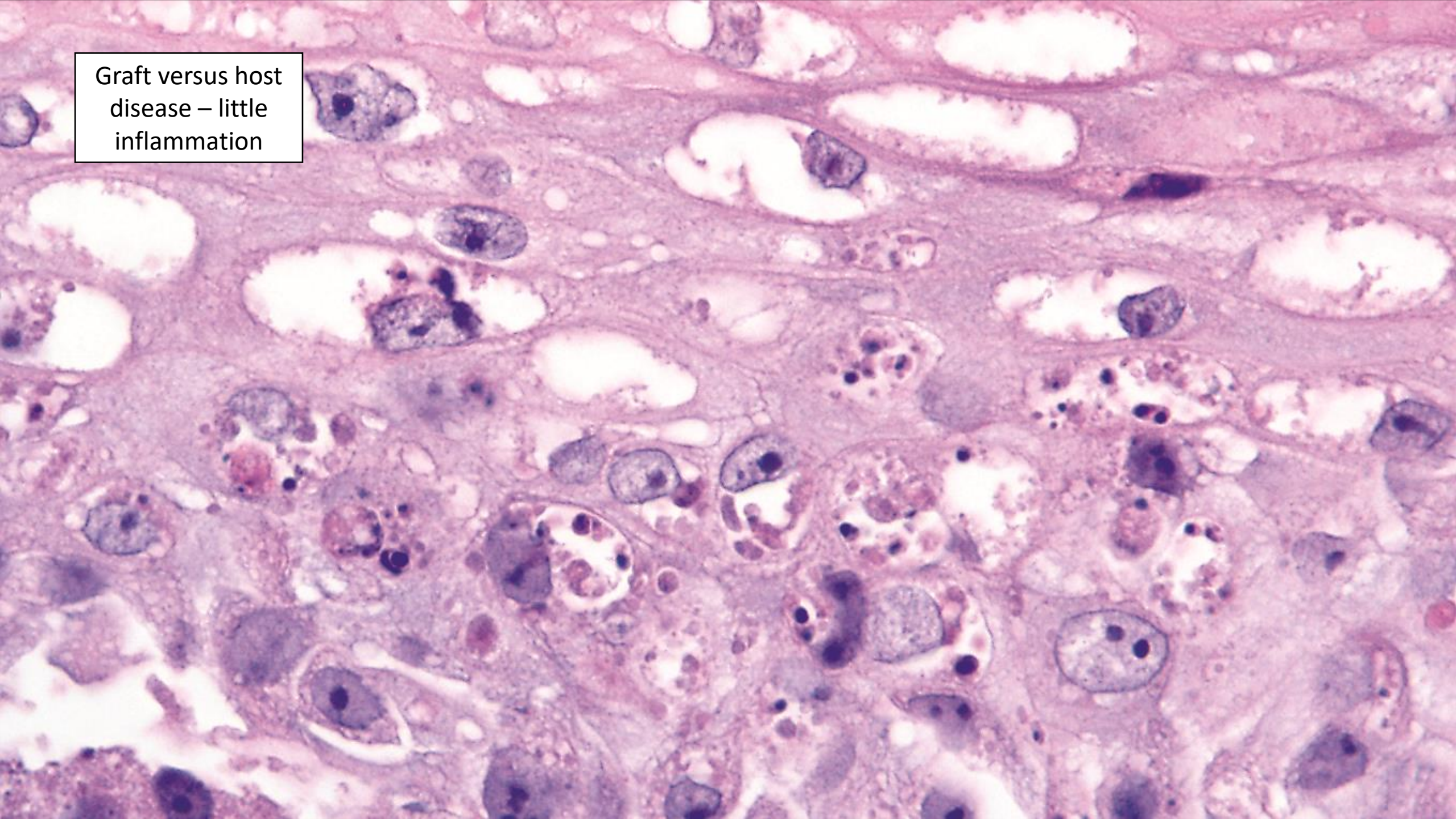
Graft versus host disease – little inflammation

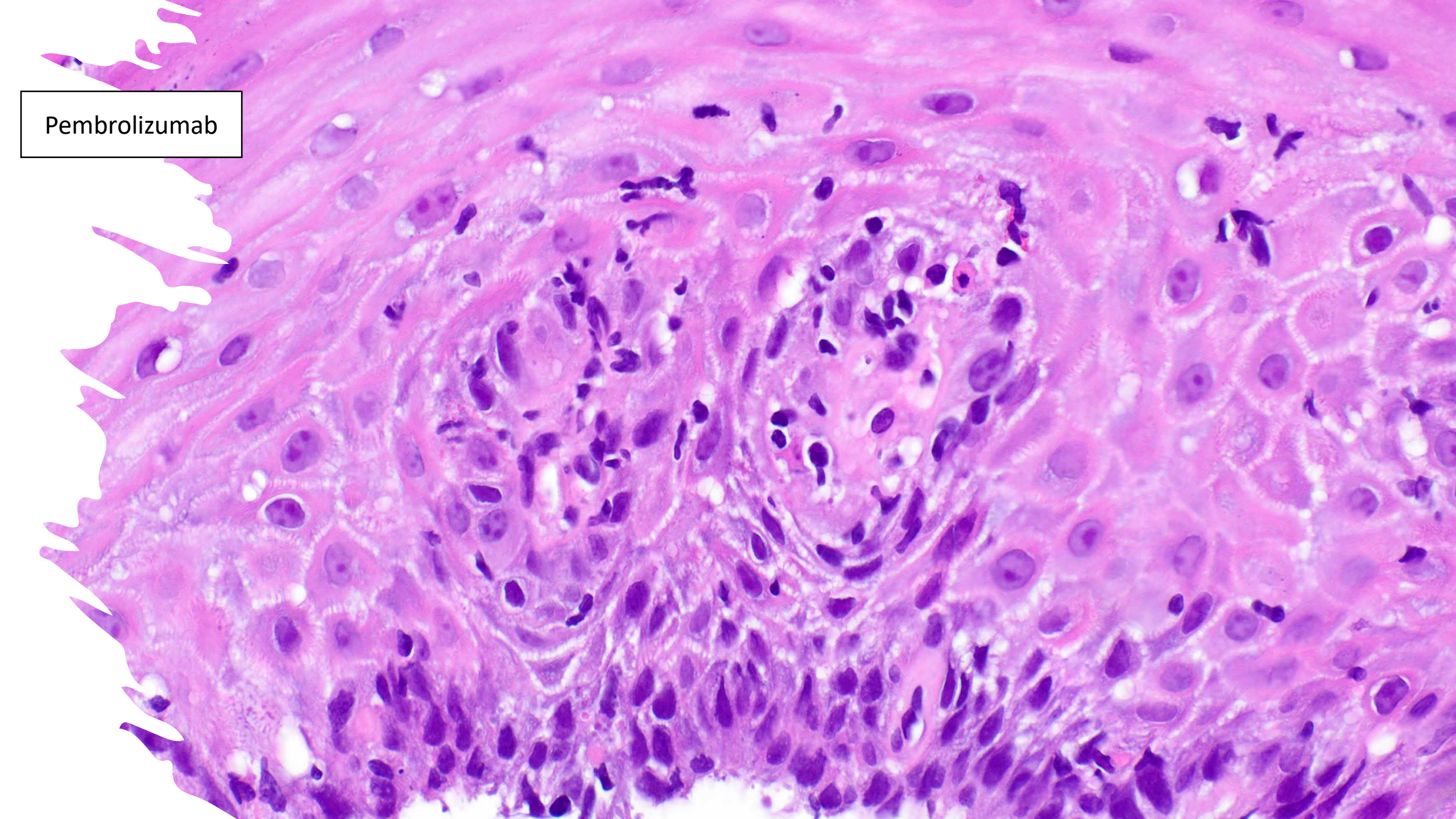
Pembrolizumab

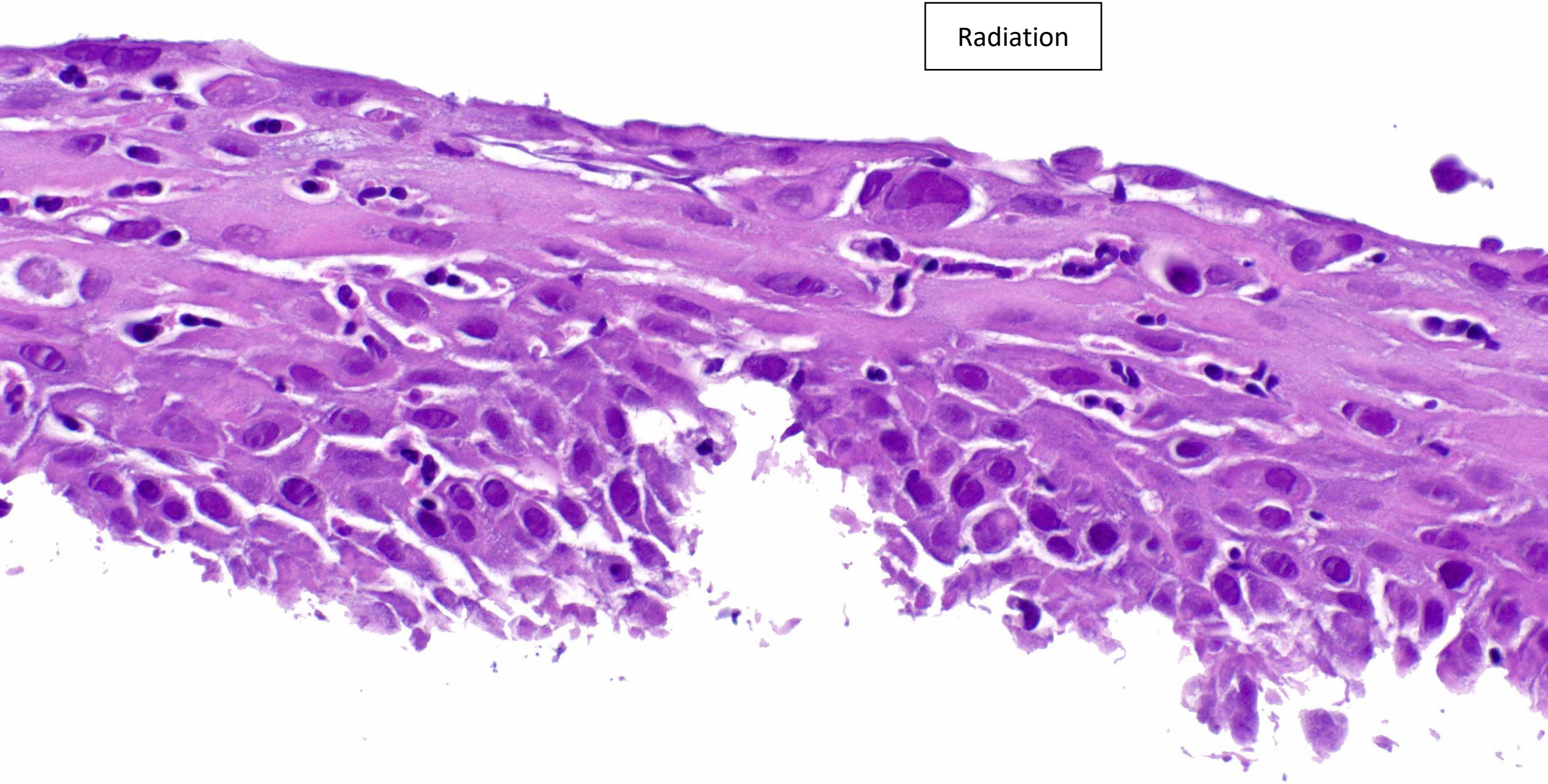
Radiation

Hyperkeratosis

- *Candida*
- Reflux
- Epidermoid metaplasia

Reflux parakeratosis – brightly eosinophilic and adheres tightly to surface

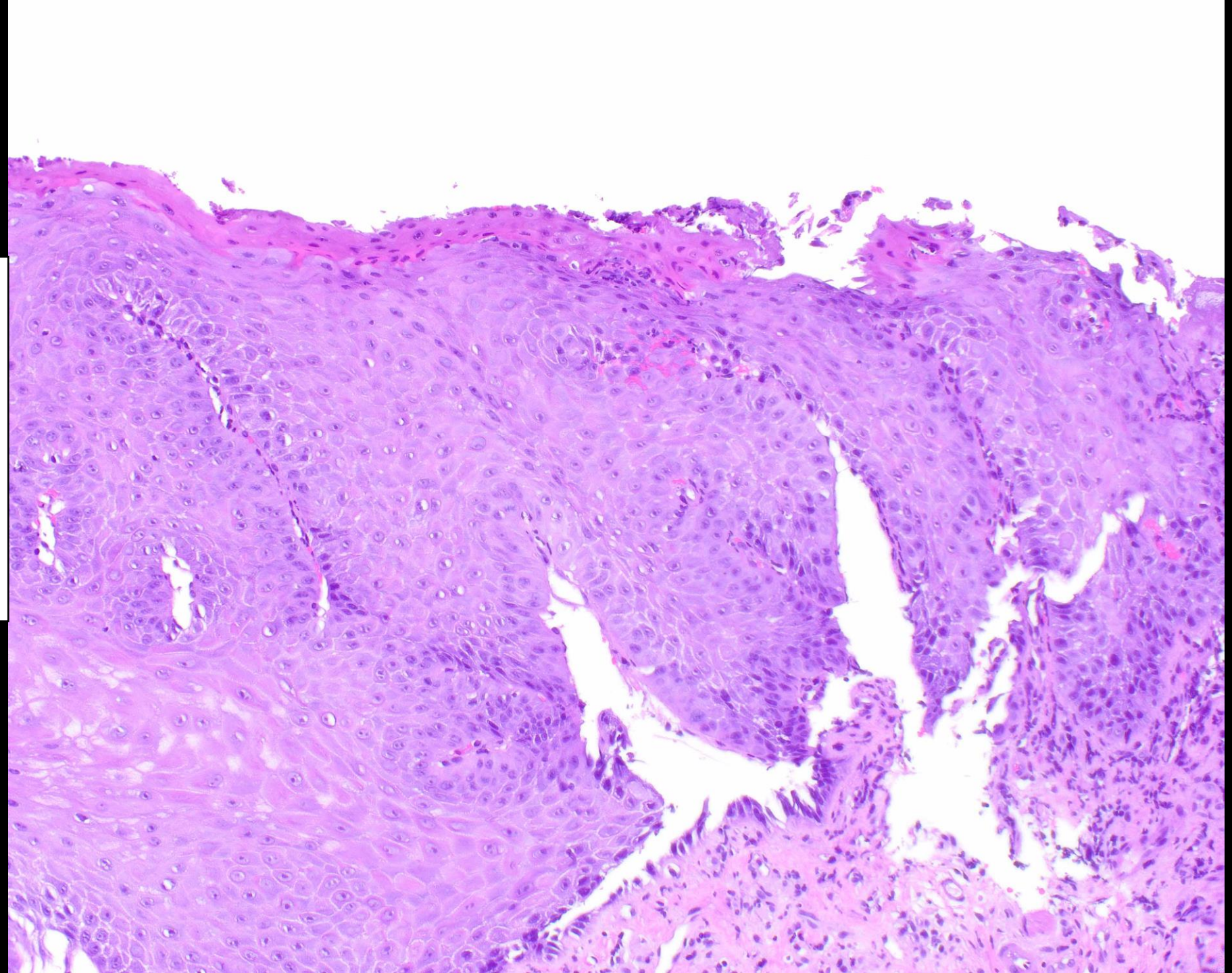

Candida parakeratosis- flaky like a pastry

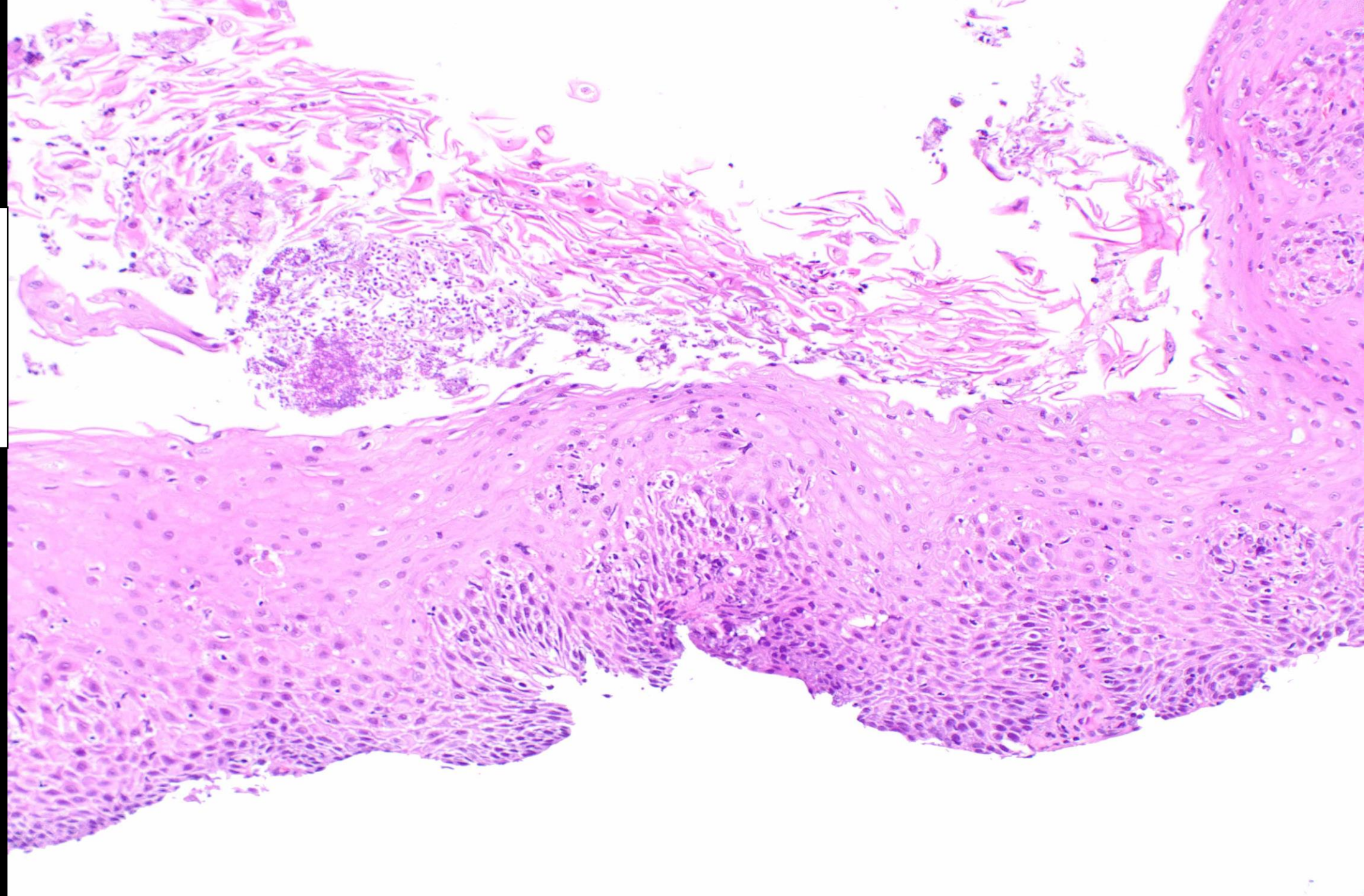

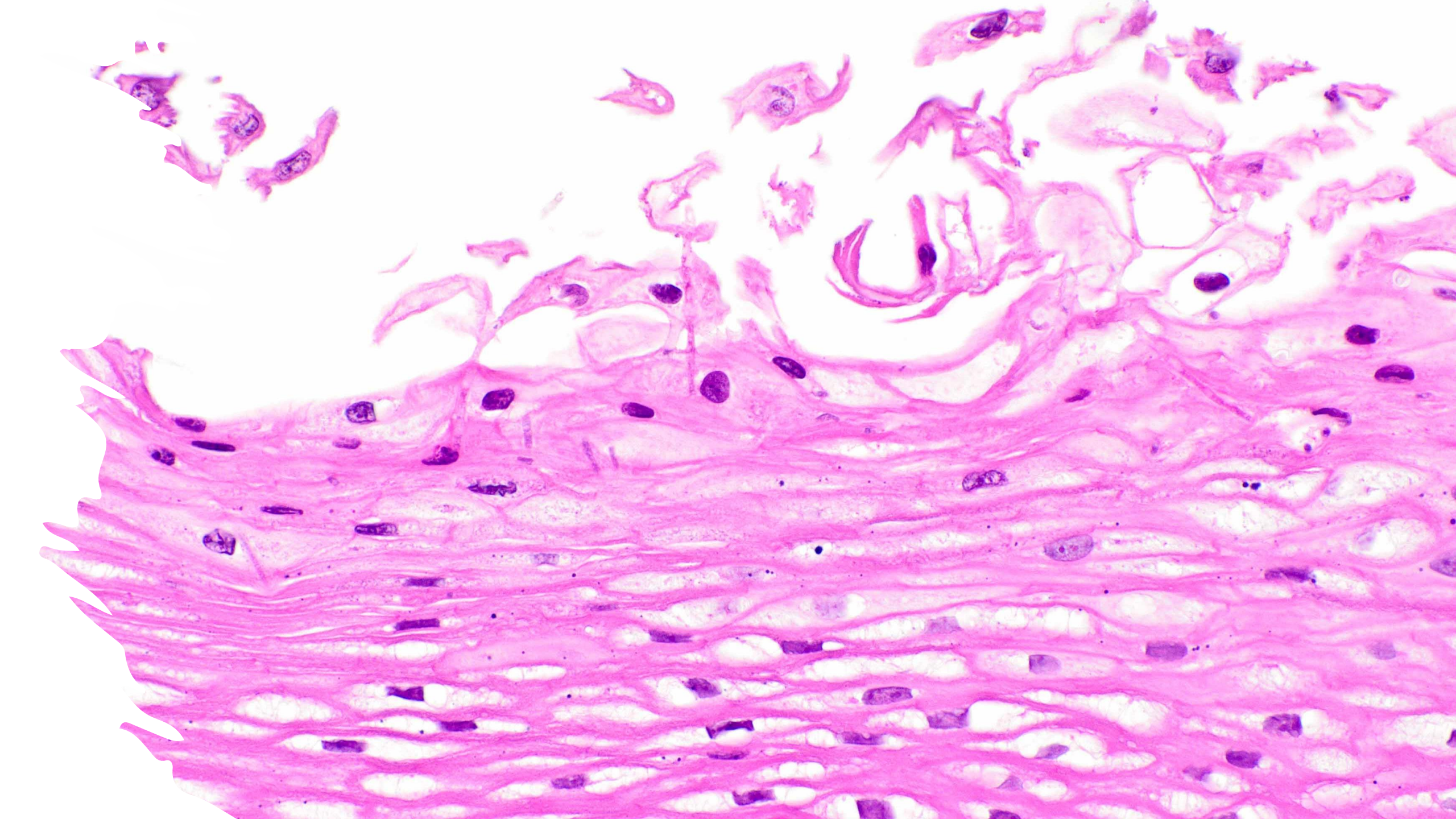

Epidermoid metaplasia:
White plaques
Associated with alcohol and tobacco
Probably a precursor to squamous cell carcinoma

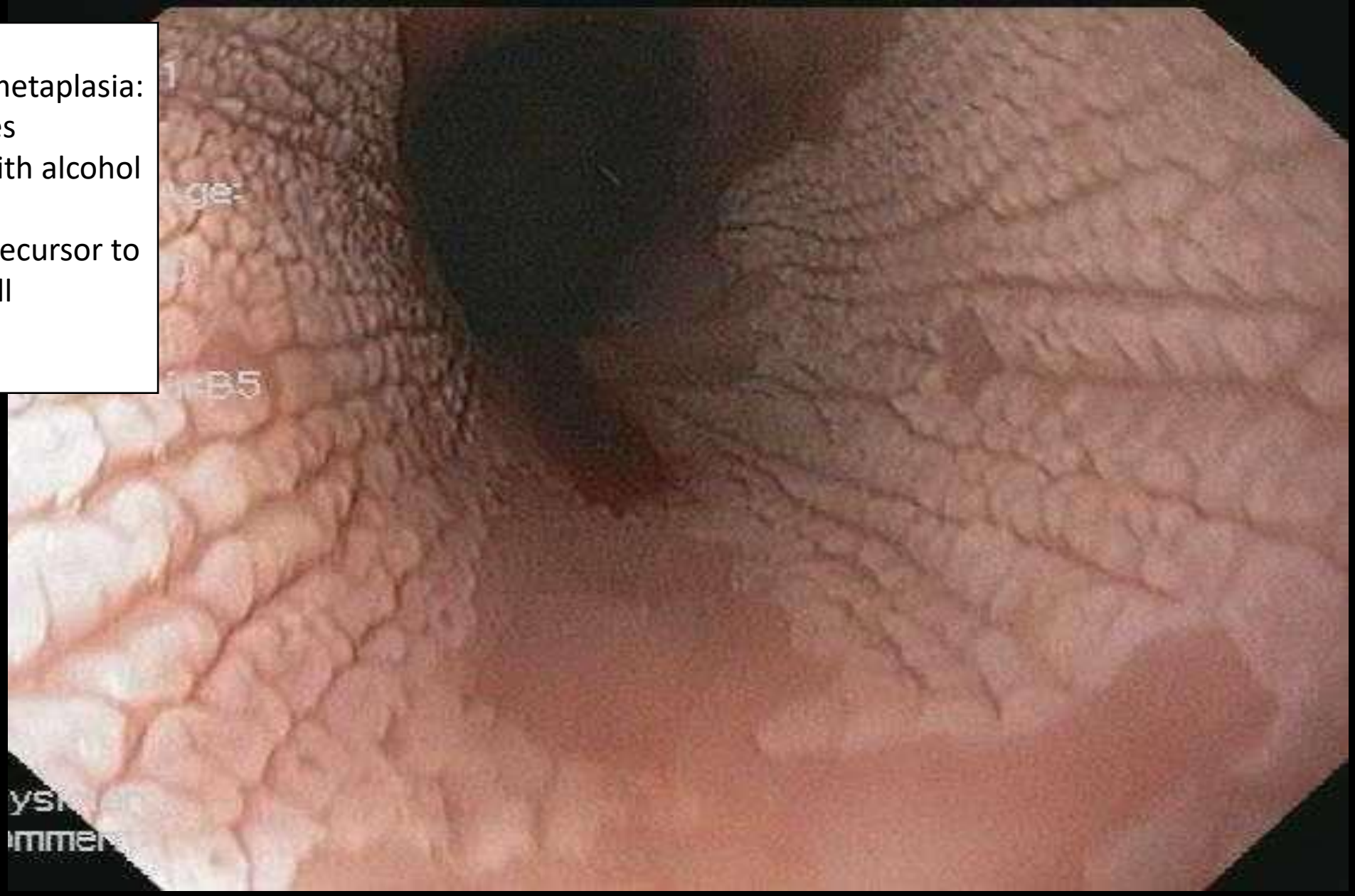

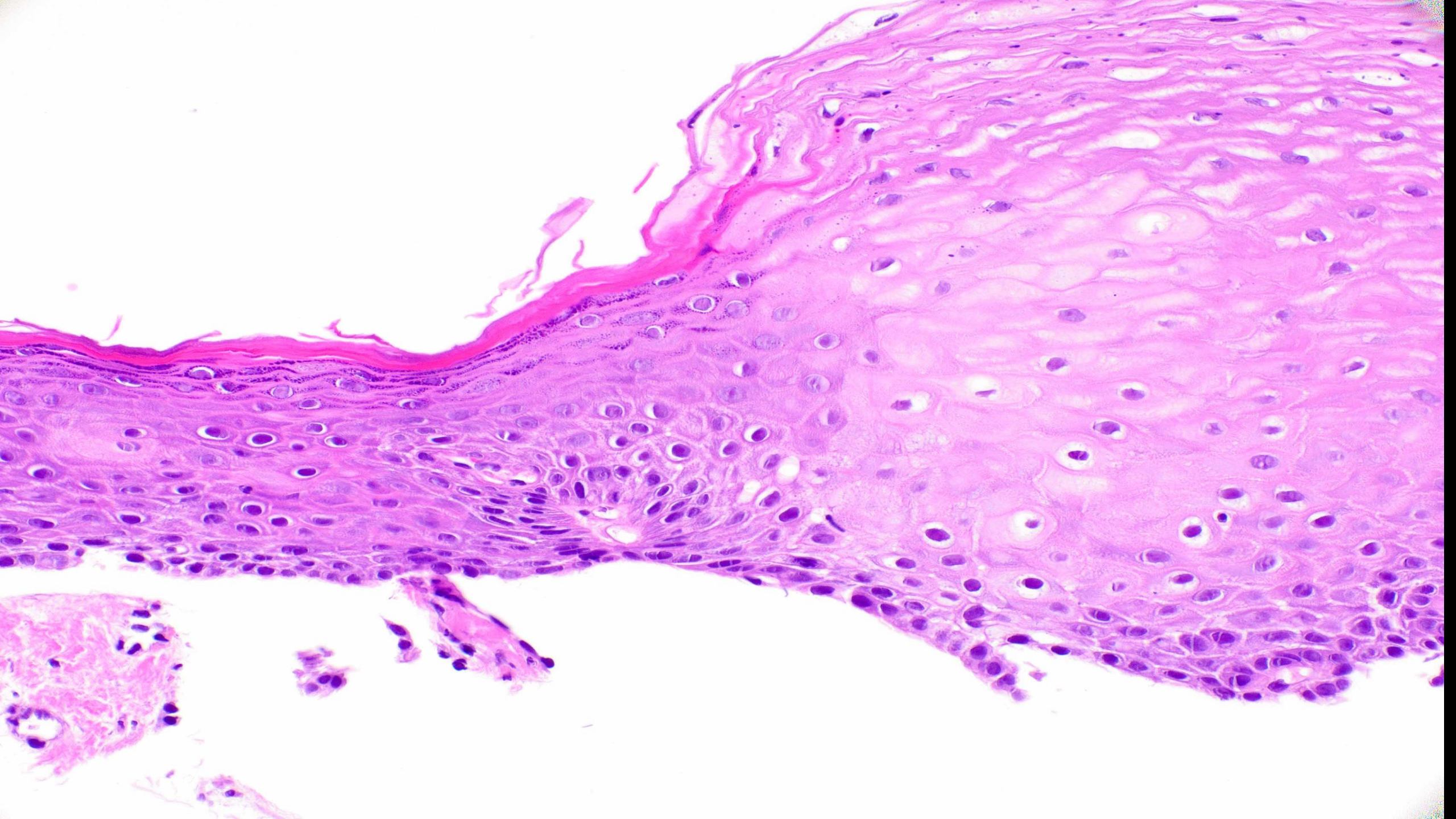

Epidermoid Metaplasia

- The molecular alterations are identical to those in the associated squamous cell carcinomas!
- Accumulating clinical data support epidermoid metaplasia as a precursor to squamous cell carcinoma

- Singhi AD, Arnold CA, Lam-Himlin DM, Nikiforova MN, Voltaggio L, Canto MI, McGrath KM, Montgomery EA. Targeted next-generation sequencing supports epidermoid metaplasia of the esophagus as a precursor to esophageal squamous neoplasia. Mod Pathol. Mod Pathol. 2017 Nov;30(11):1613-1621. PubMed PMID: 28731047.
- Kamboj AK, Gibbens YY, Hagen CE, Wang KK, Iyer PG, Katzka DA. Esophageal Epidermoid Metaplasia: Clinical Characteristics and Risk of Esophageal Squamous Neoplasia. Am J Gastroenterol. 2021 Jul 1;116(7):1533-1536. PMID: 33734117.

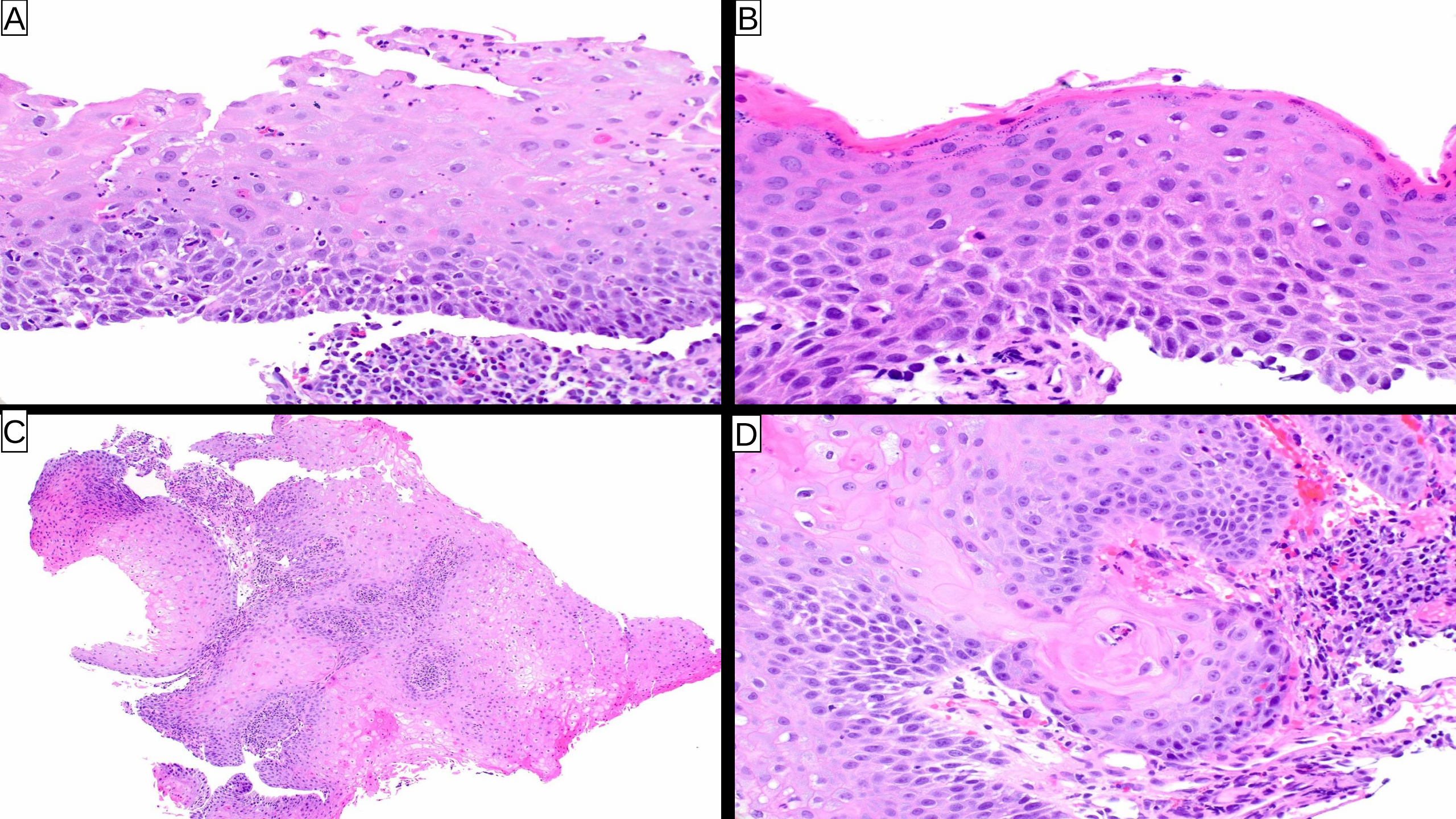
A
B
C
D

Stomach

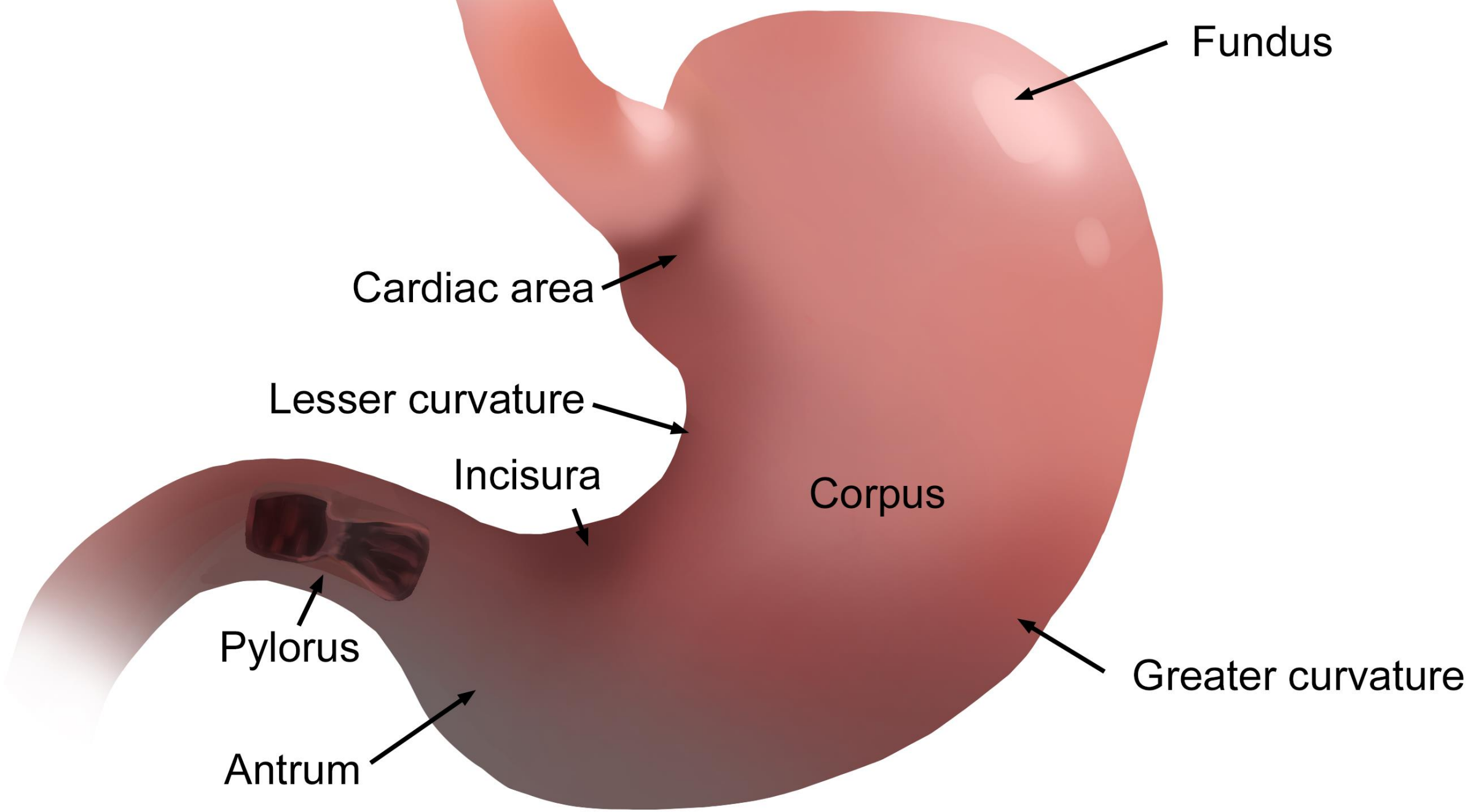
Fundus
Cardiac area
Lesser curvature
Incisura
Corpus
Pylorus
Greater curvature
Antrum

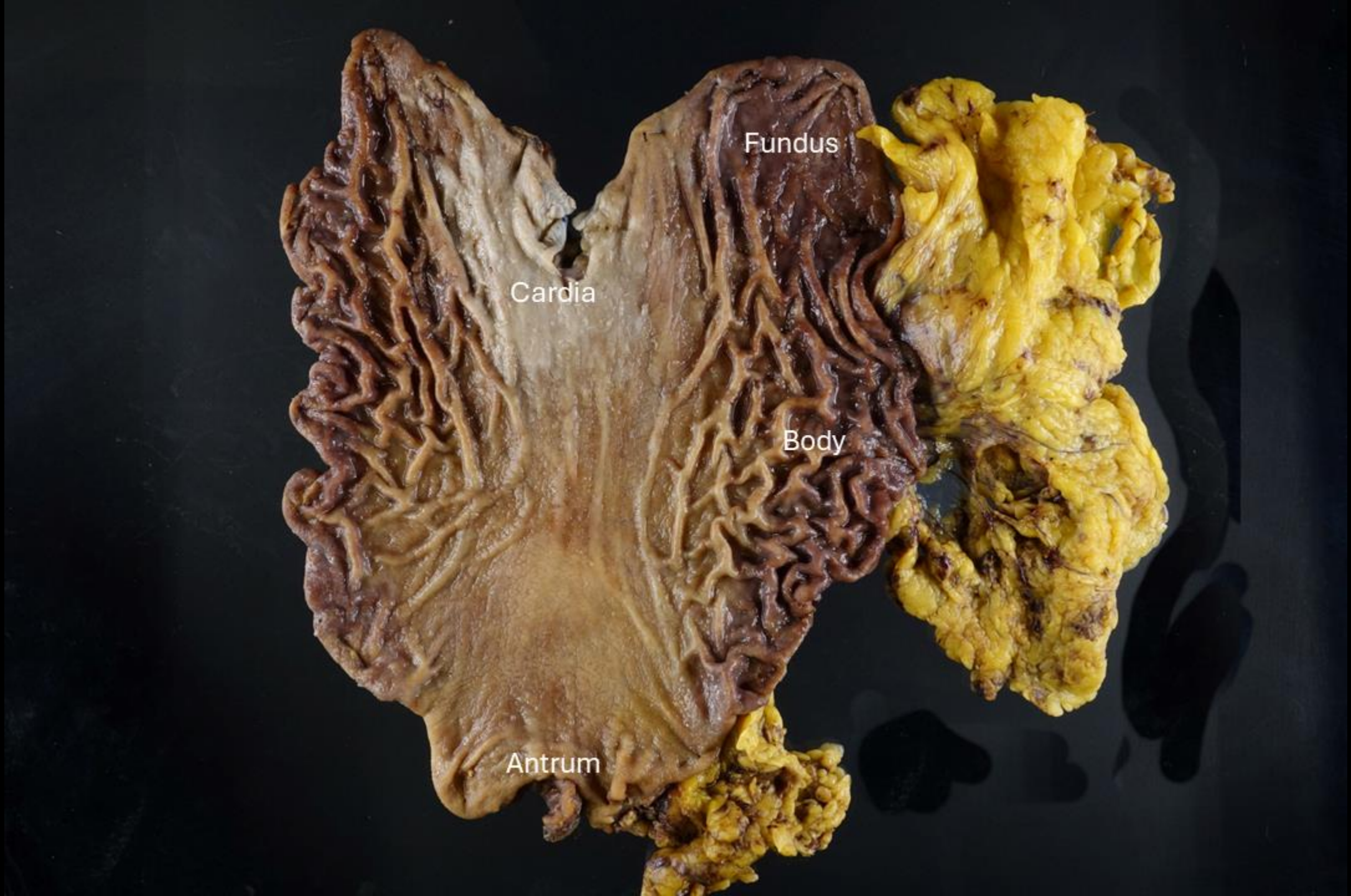
Fundus
Cardia
Body
Antrum

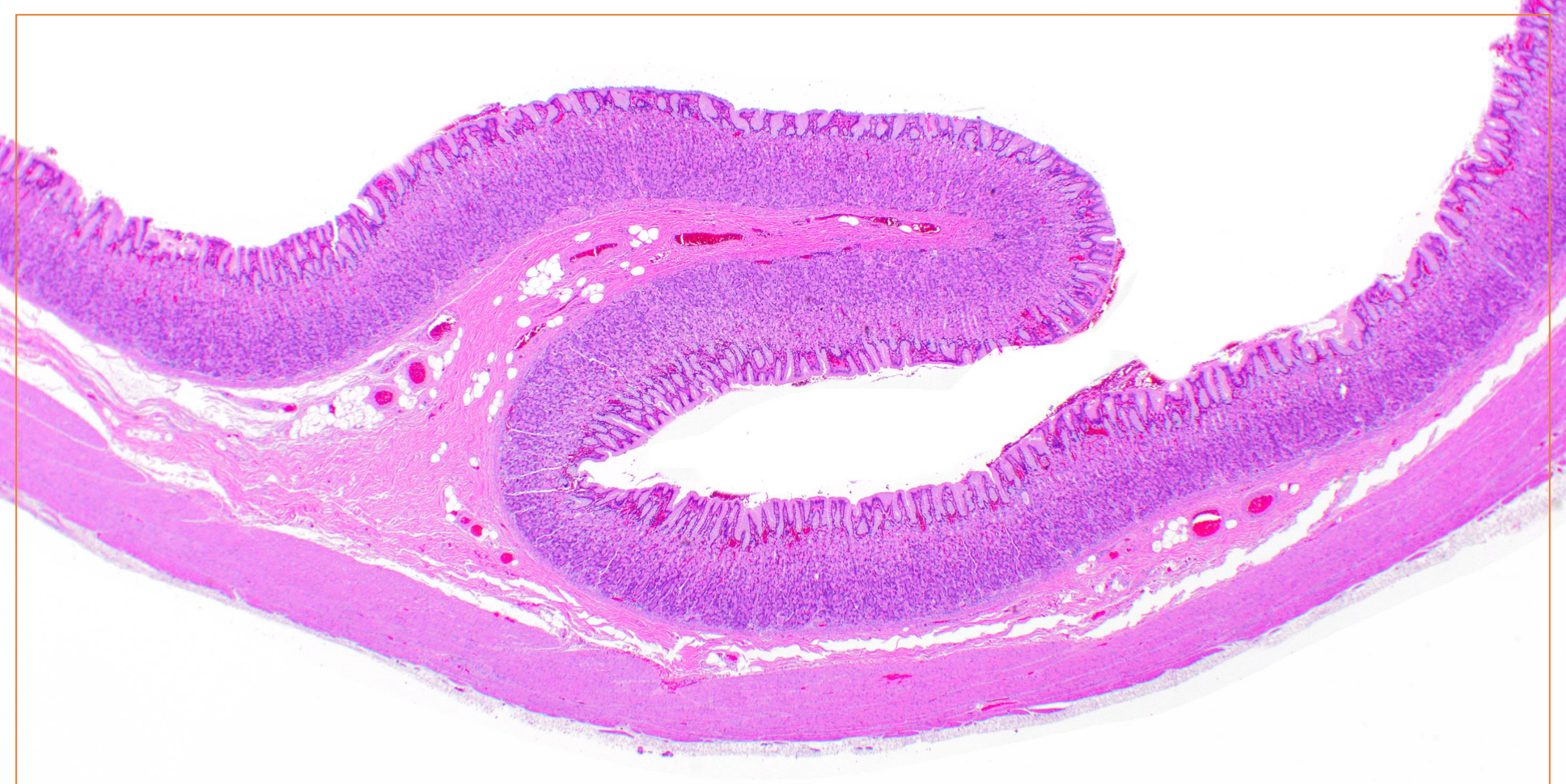

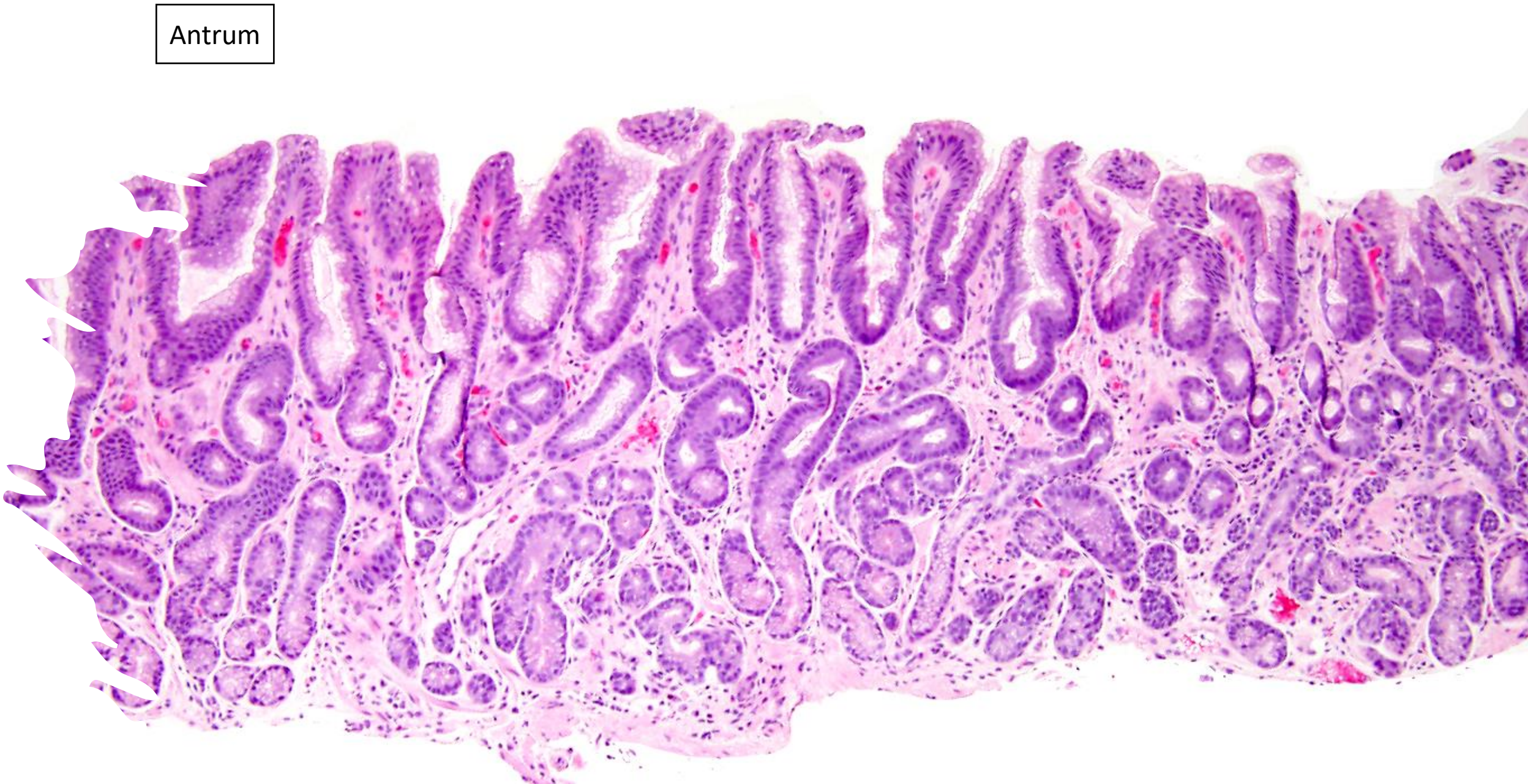
Antrum

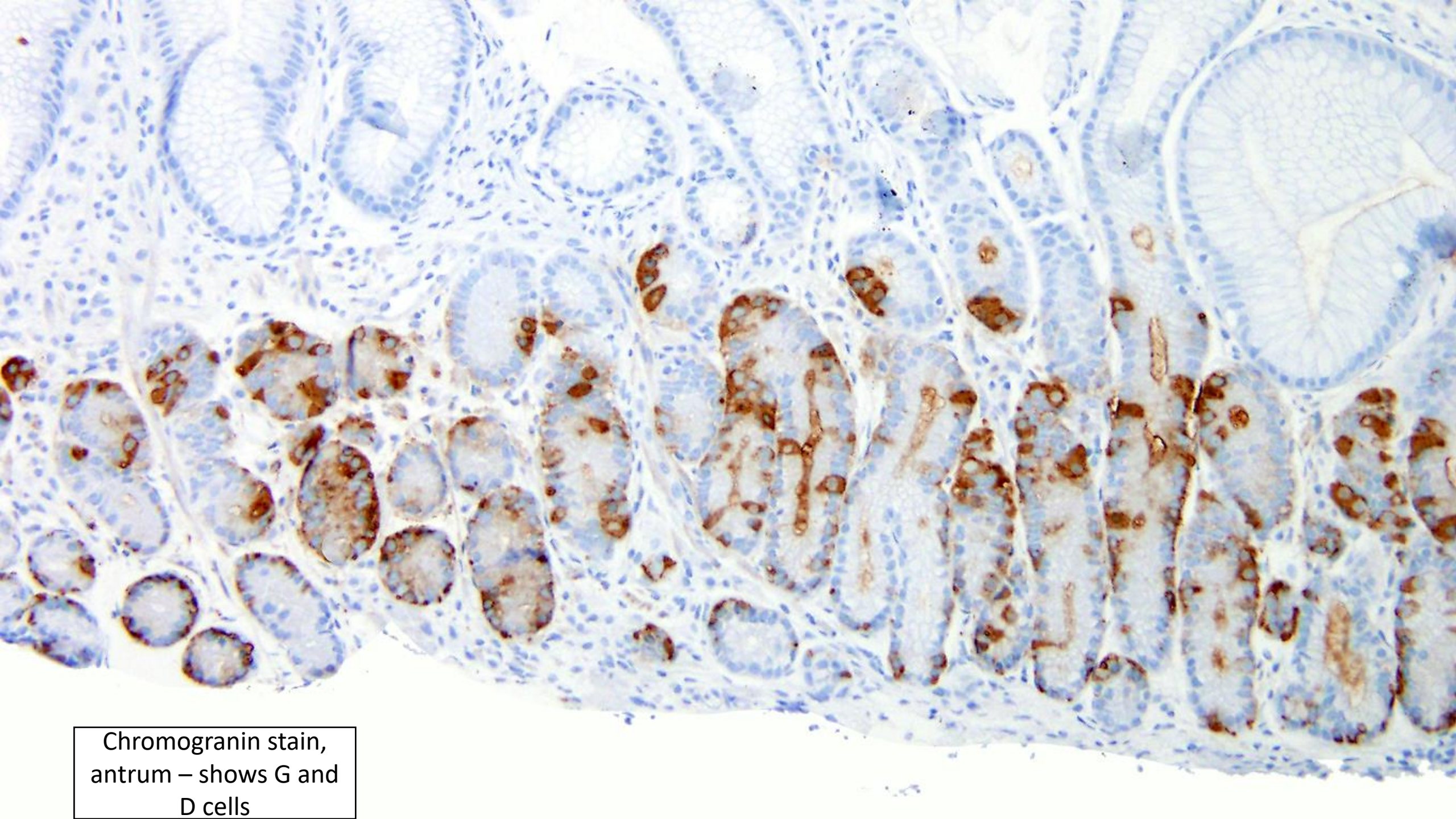

Chromogranin stain, antrum – shows G and D cells

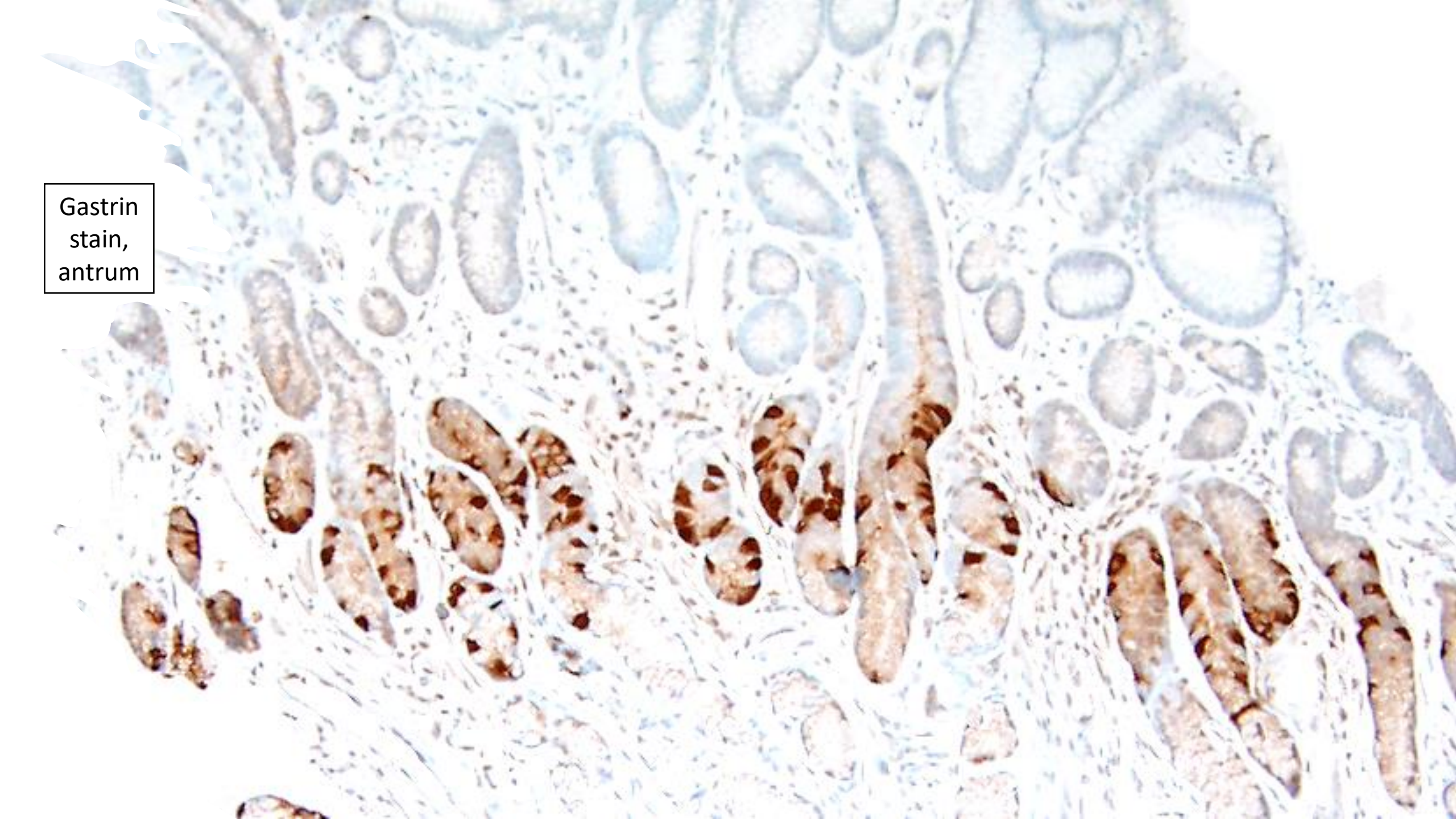
Gastrin stain, antrum

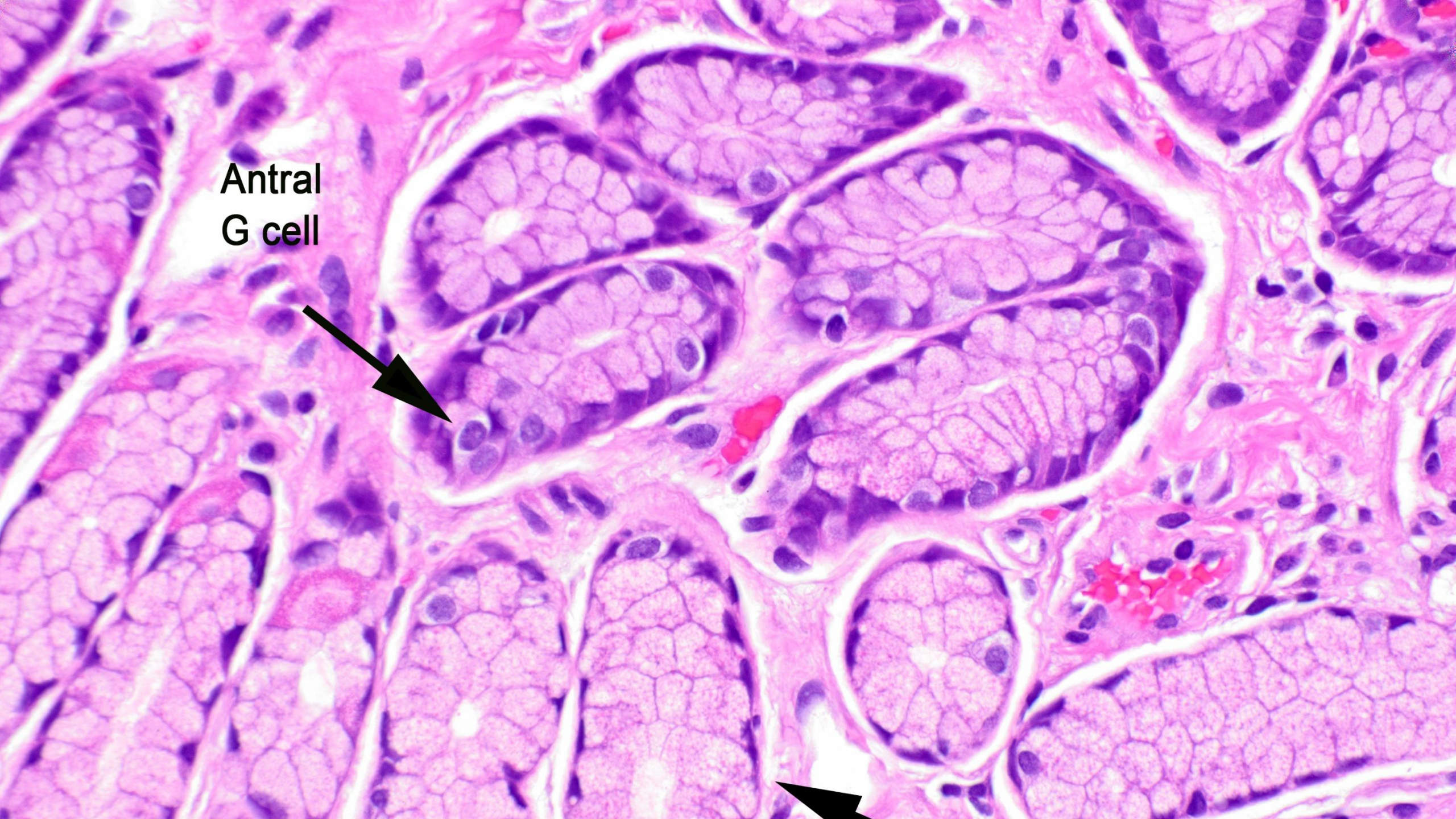
Antral
G cell

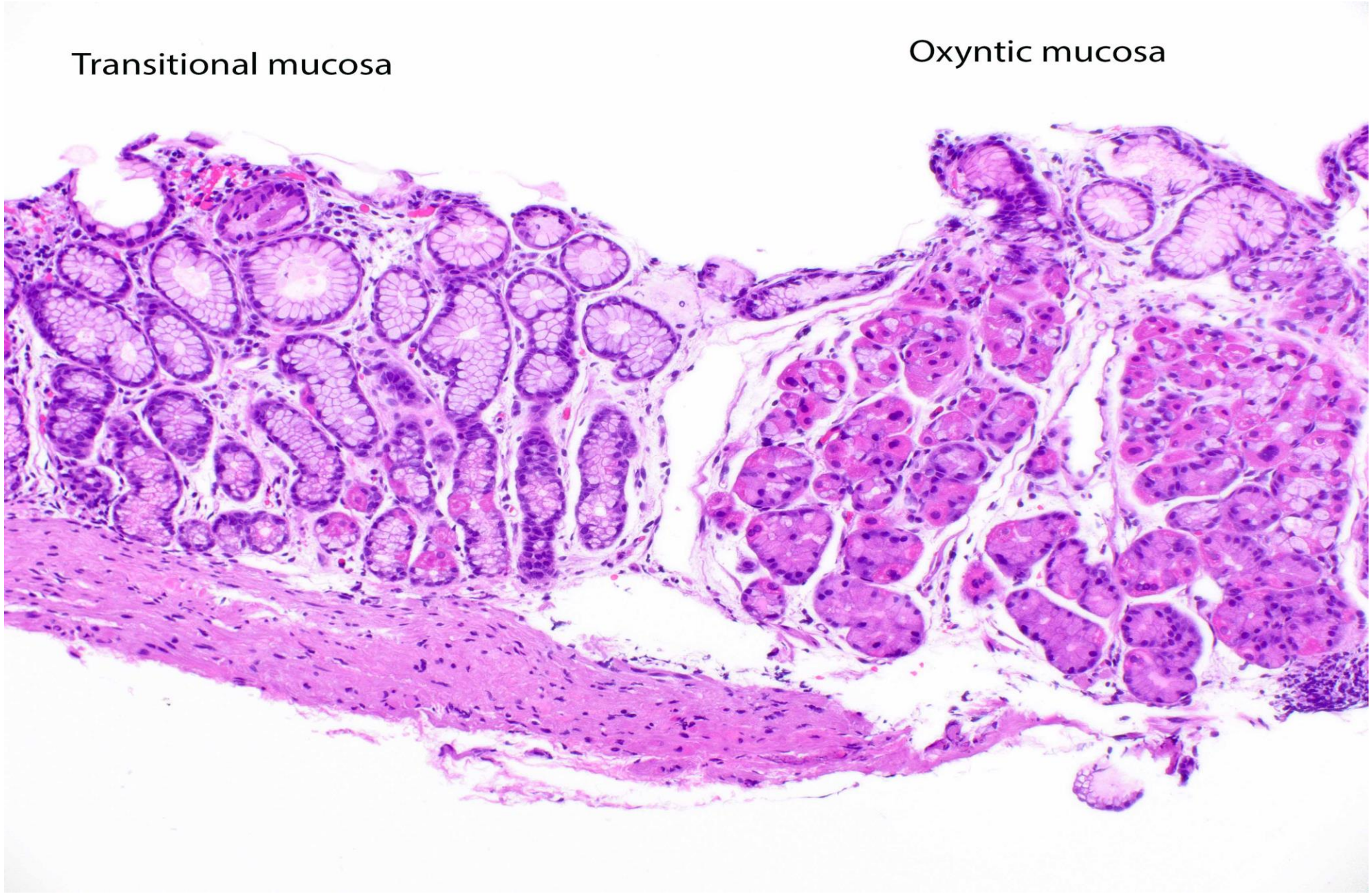
Transitional mucosa
Oxyntic mucosa

Oxyntic mucosa
Pink parietal cells
Purplish chief cells

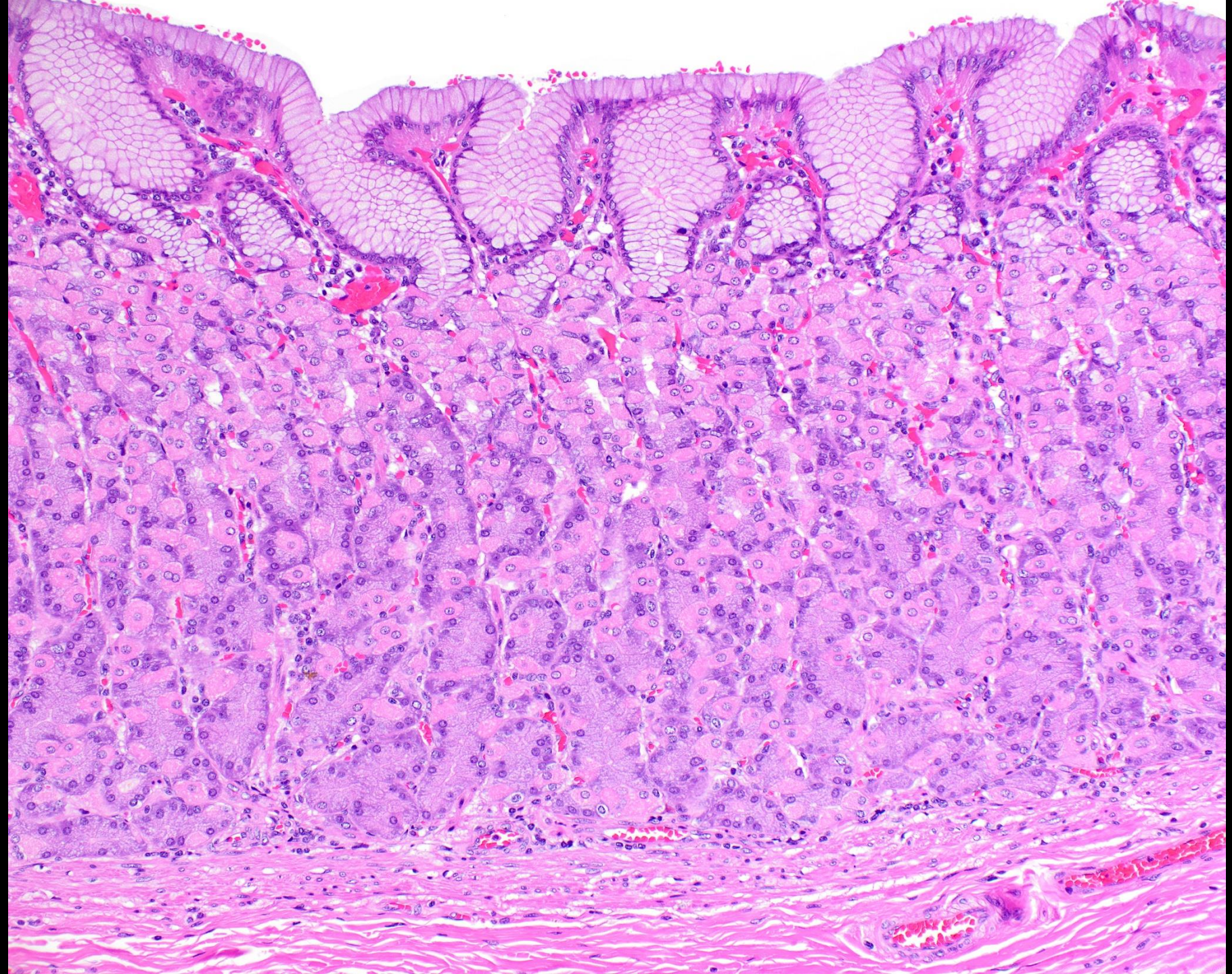

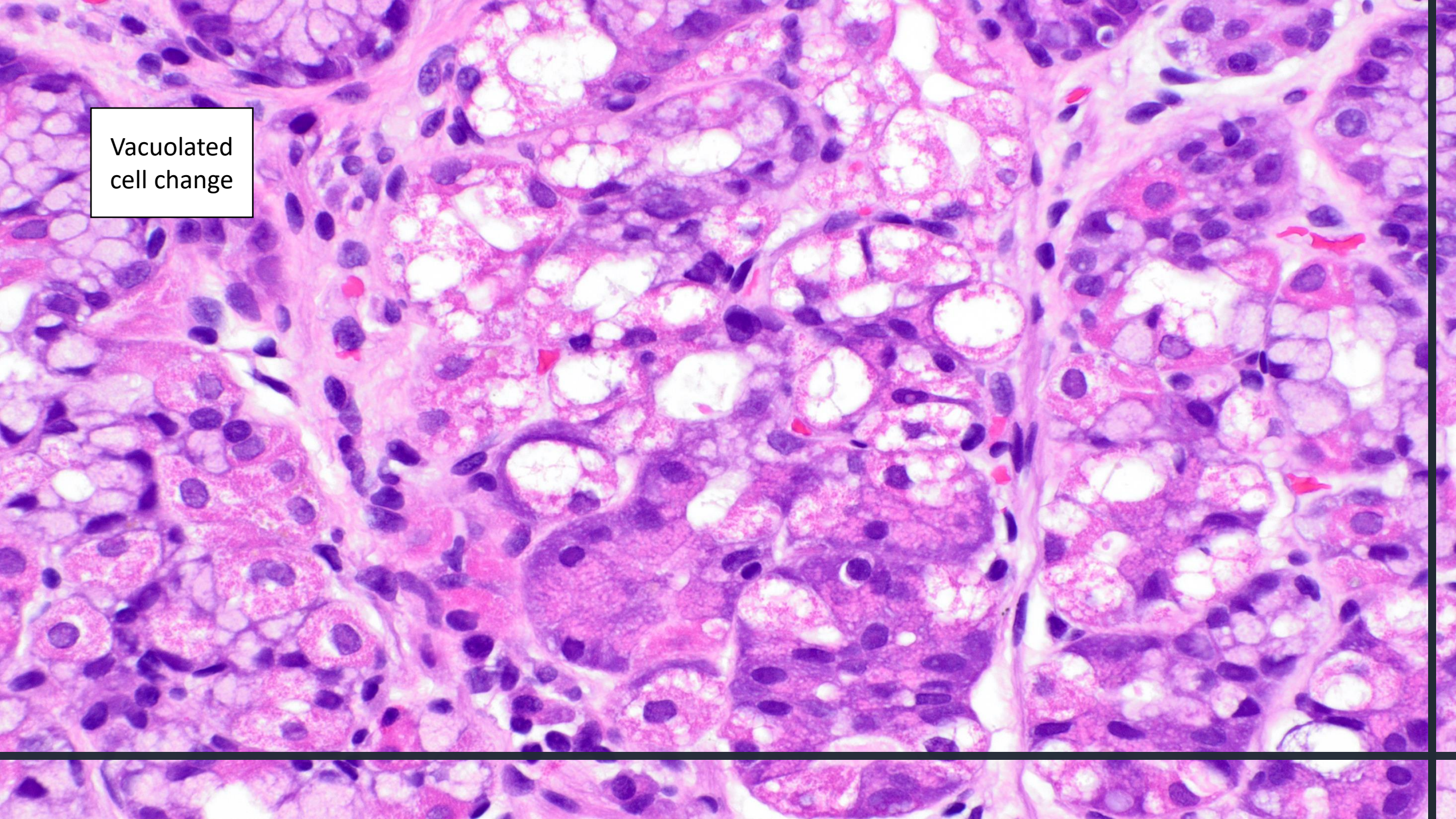
Vacuolated
cell change

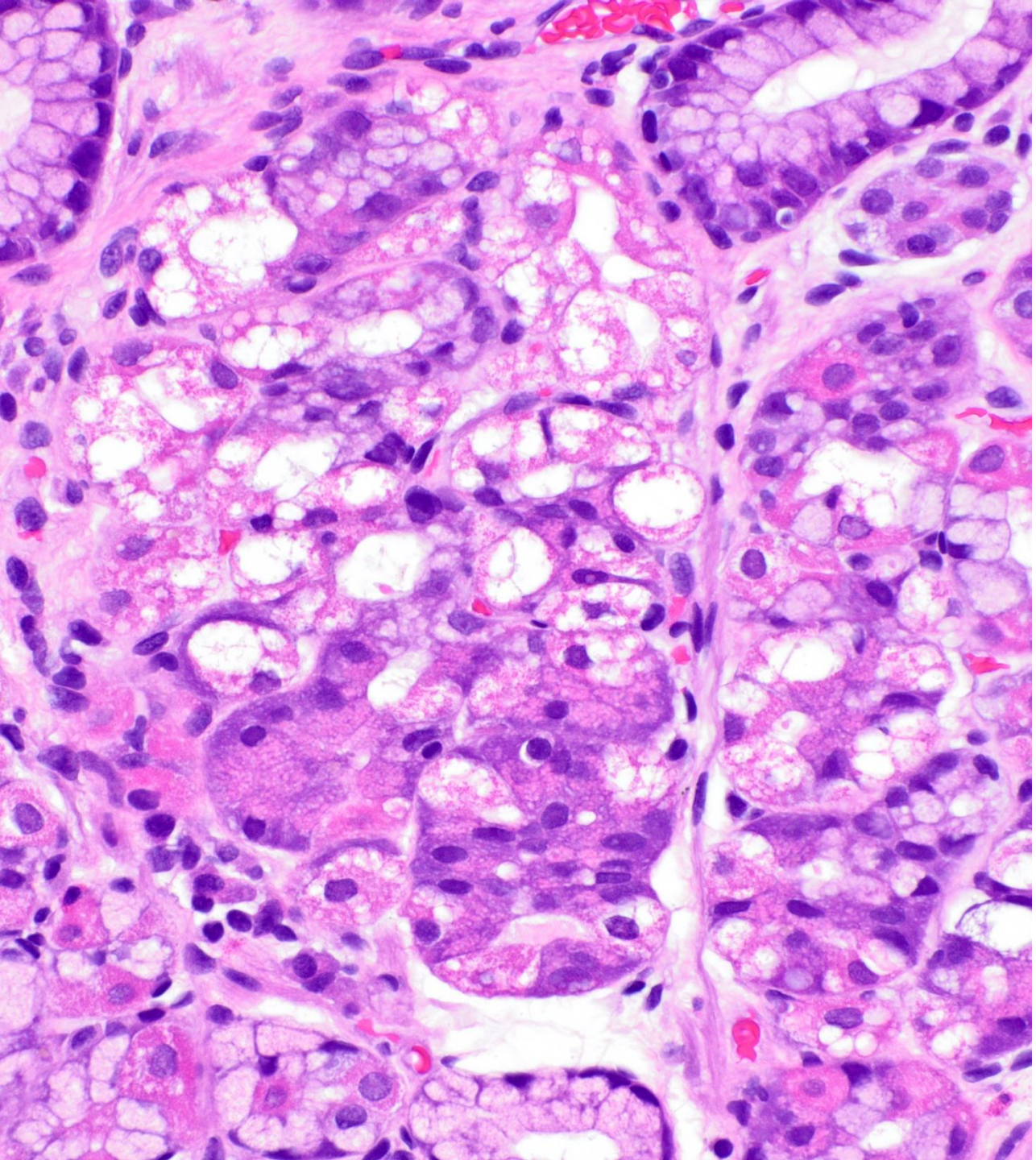

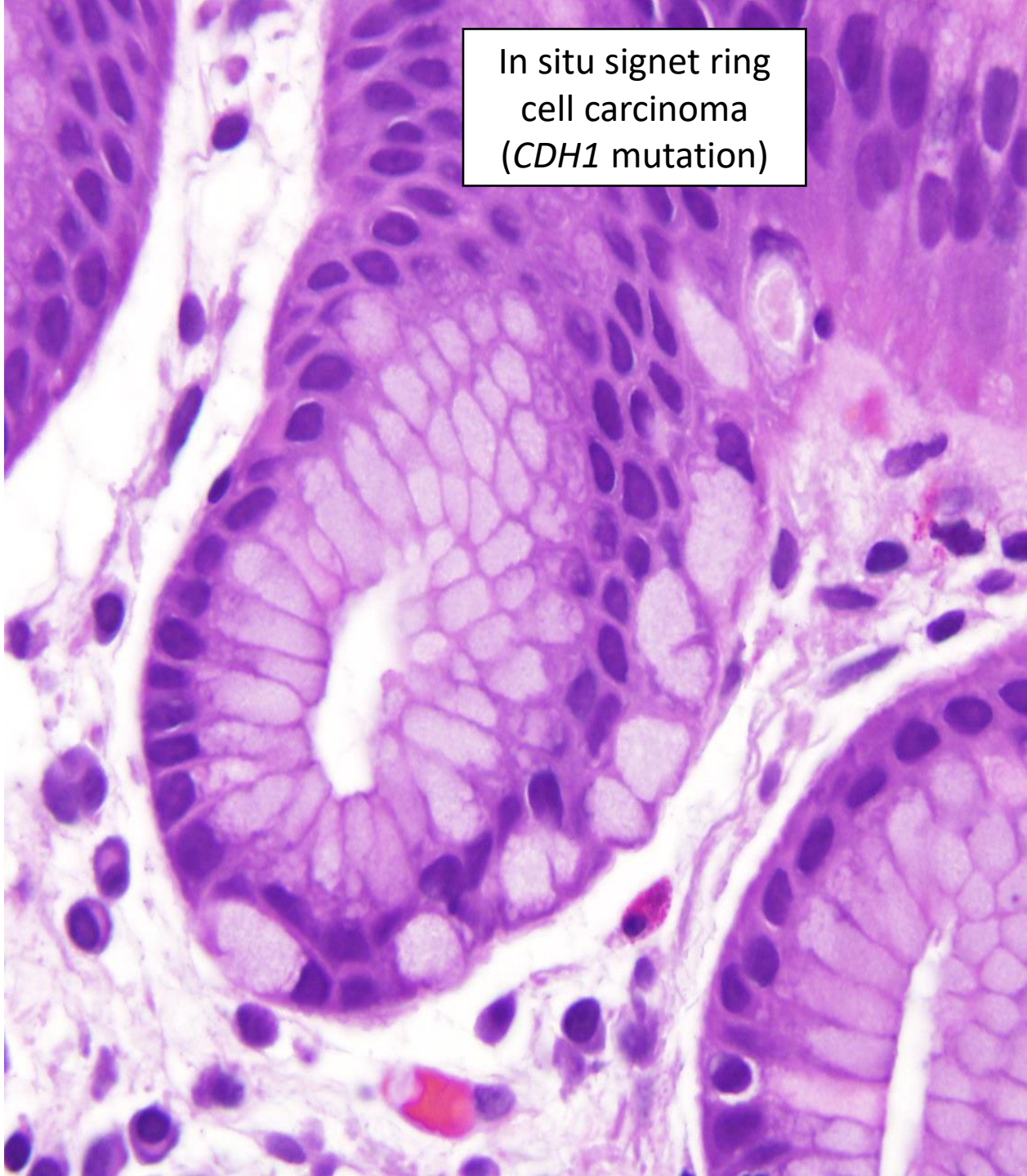
In situ signet ring cell carcinoma (*CDH1* mutation)

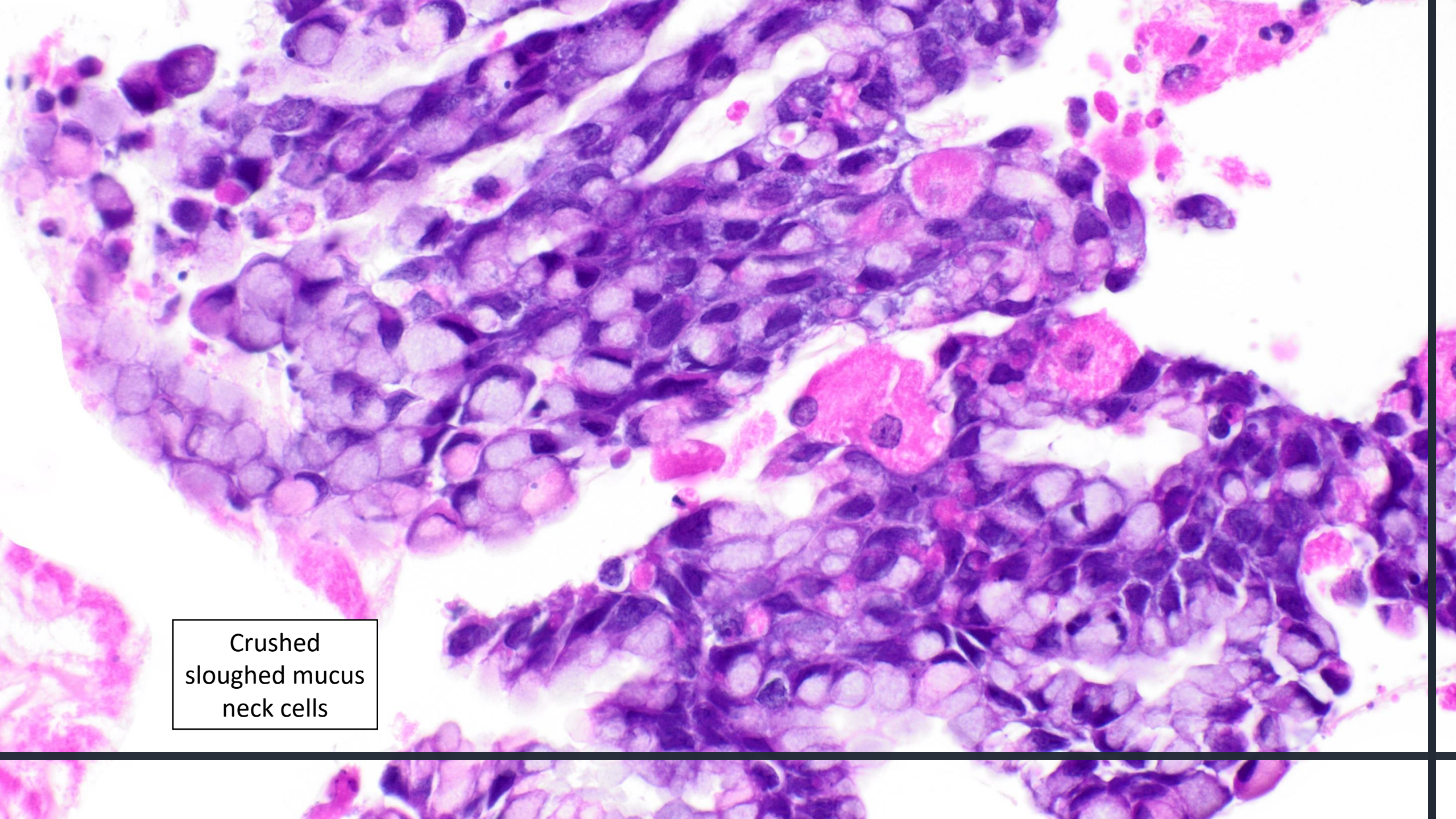
Crushed
sloughed mucus
neck cells

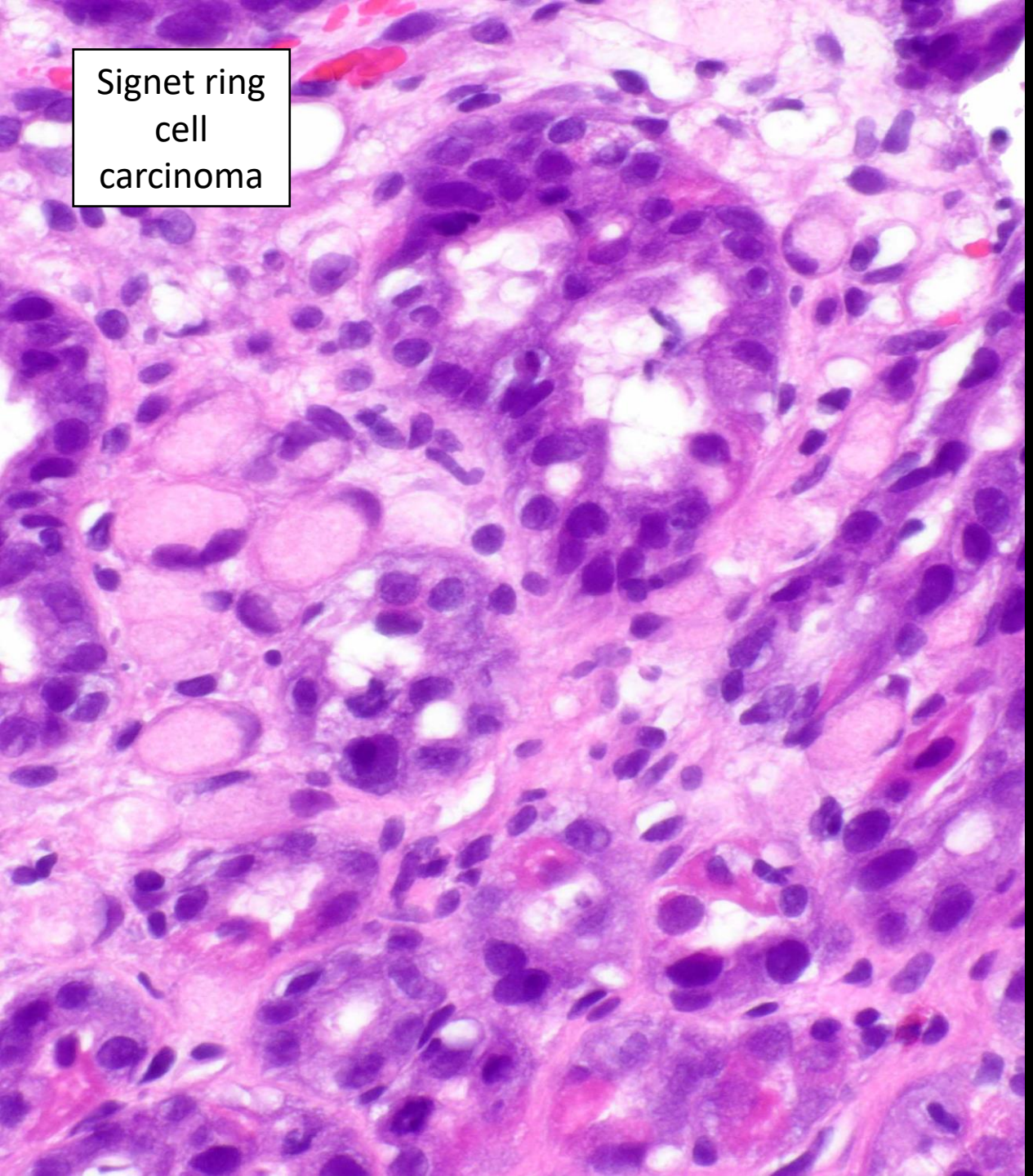
Signet ring
cell
carcinoma

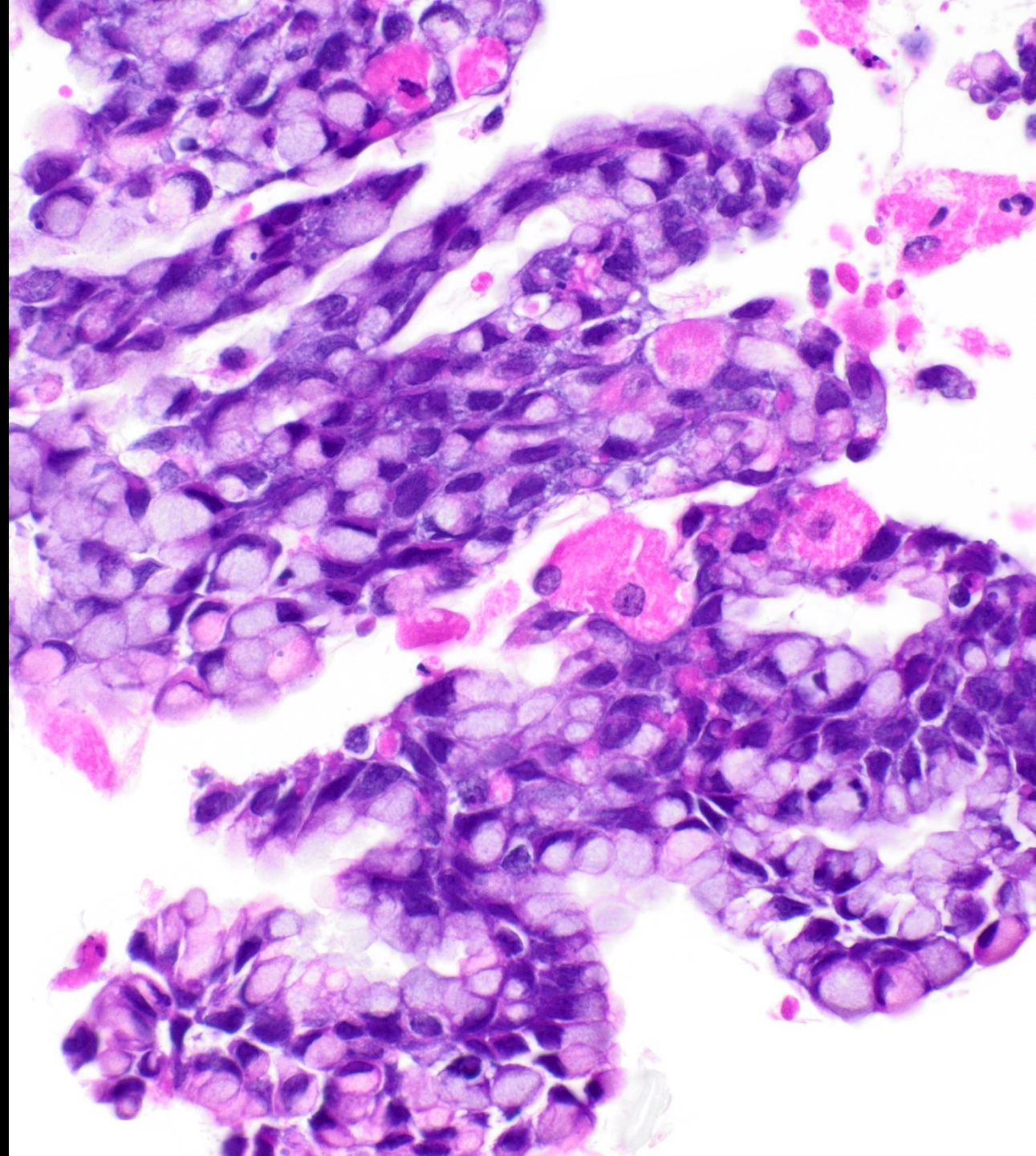

Gastric Injury

1. What type of gastric mucosa is present?

2. Is the mucosa inflamed?

3. Is there prominent epithelial apoptosis?

Attention to each of these is useful in determining the etiology of any abnormal findings.

Gastric mucosal injury

- H. pylori gastritis and autoimmune gastritis.
- “Reactive gastropathy/chemical gastropathy”
- Medication-associated injury is important.
- Issues often revolve around reactive versus dysplastic epithelial changes.

A fantastic clue

- A great clue to reactive epithelium in Barrett mucosa is looking for “the four lines”
- This feature is present in gastric cardiac mucosa and remains in Barrett mucosa

- Let’s have a look

- 1: Waters KM, Salimian KJ, Assarzadegan N, Hutchings D, Makhoul EP, Windon AL, Wong MT, Voltaggio L, Montgomery EA. Cell polarity (the 'four lines’) distinguishes gastric dysplasia from epithelial changes in reactive gastropathy. Histopathology. 2021 Feb;78(3):453-458. PMID: 32841414; PMCID: PMC9281539.
- 2: Waters KM, Salimian KJ, Voltaggio L, Montgomery EA. Refined Criteria for Separating Low-grade Dysplasia and Nondysplastic Barrett Esophagus Reduce Equivocal Diagnoses and Improve Prediction of Patient Outcome: A 10-Year Review. Am J Surg Pathol. 2018 Dec;42(12):1723-1729. PMID: 30234520.

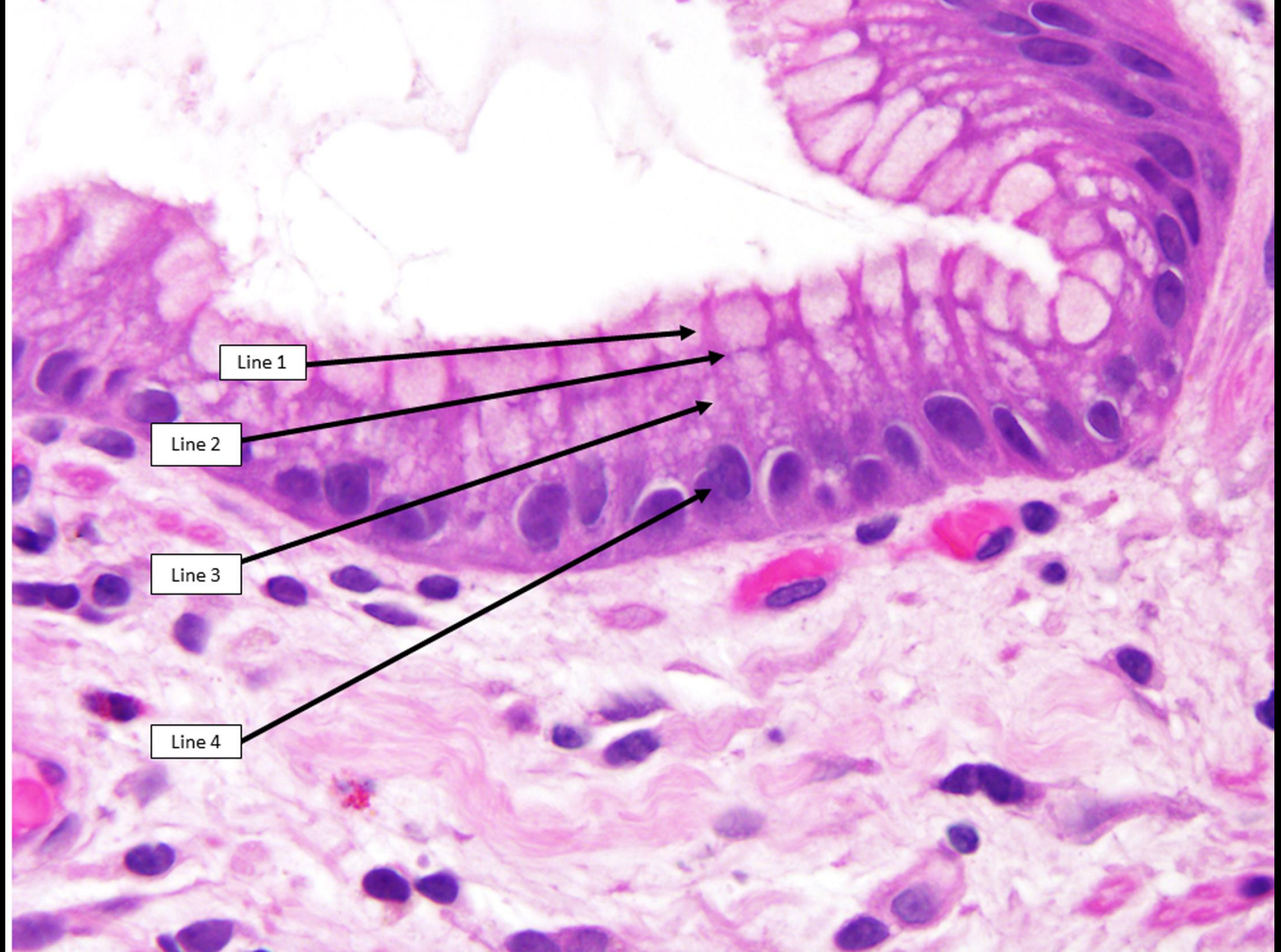
Line 1
Line 2
Line 3
Line 4

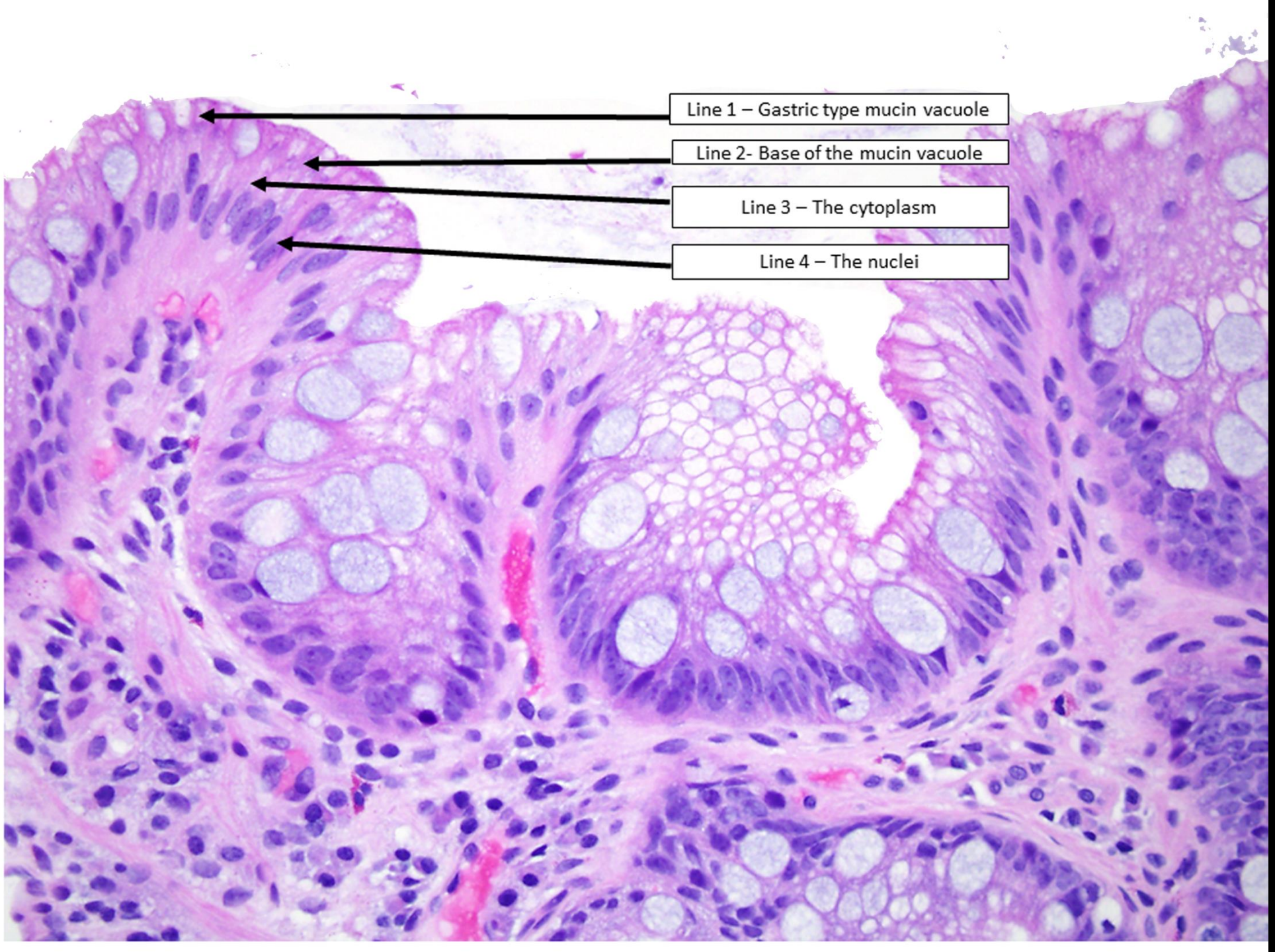
Line 1 – Gastric type mucin vacuole
Line 2- Base of the mucin vacuole
Line 3 – The cytoplasm
Line 4 – The nuclei

Antral biopsy

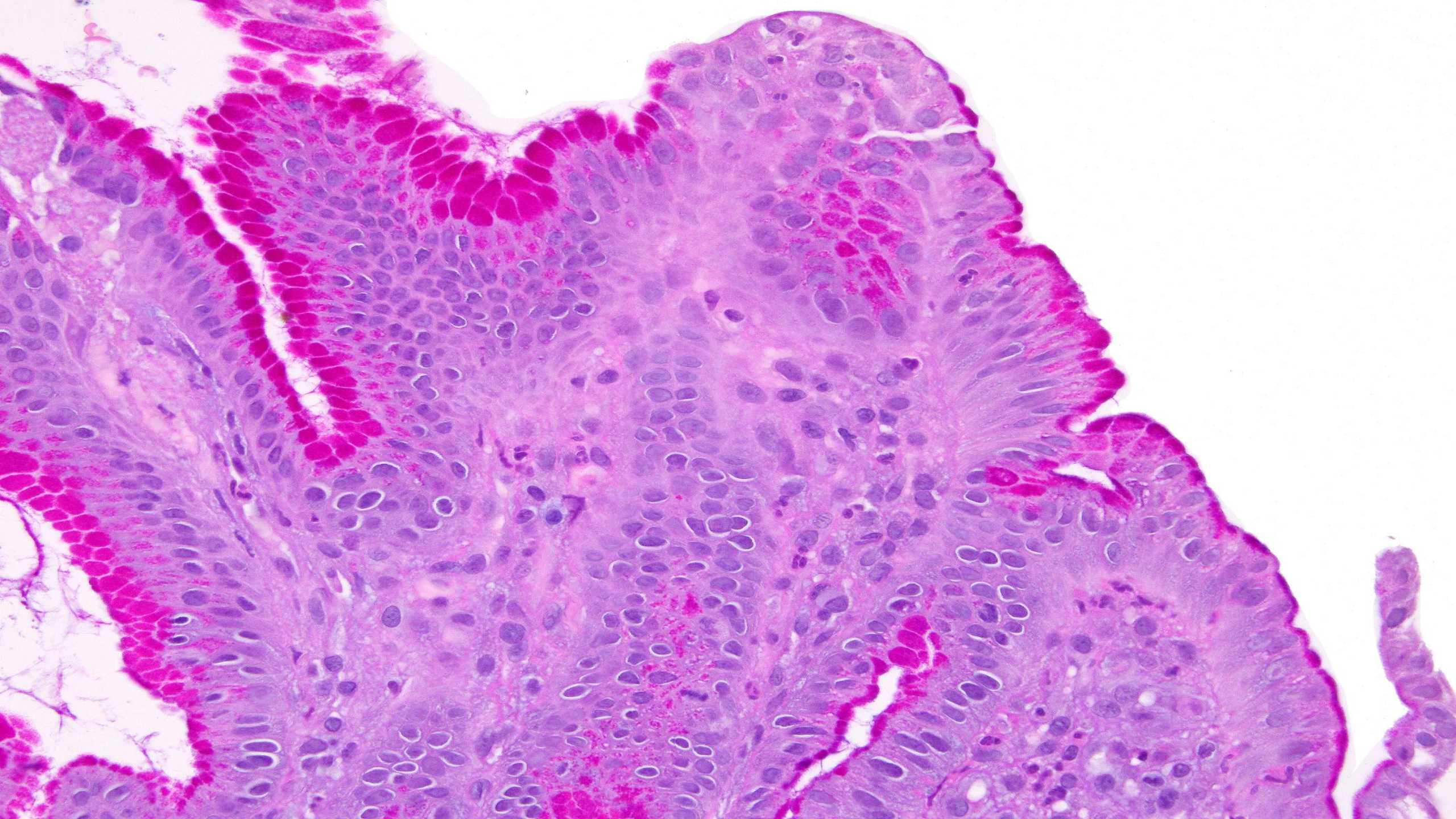

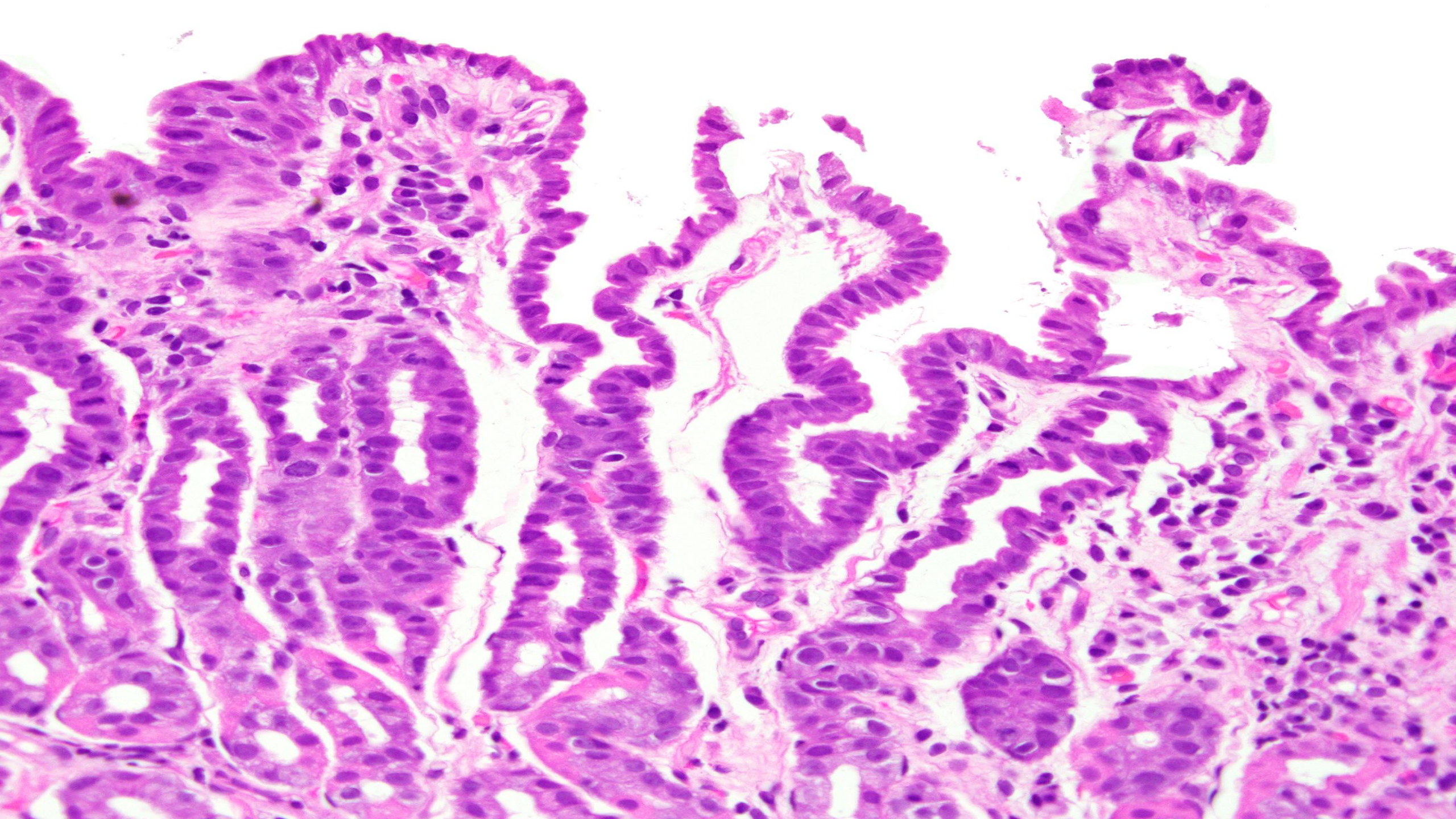

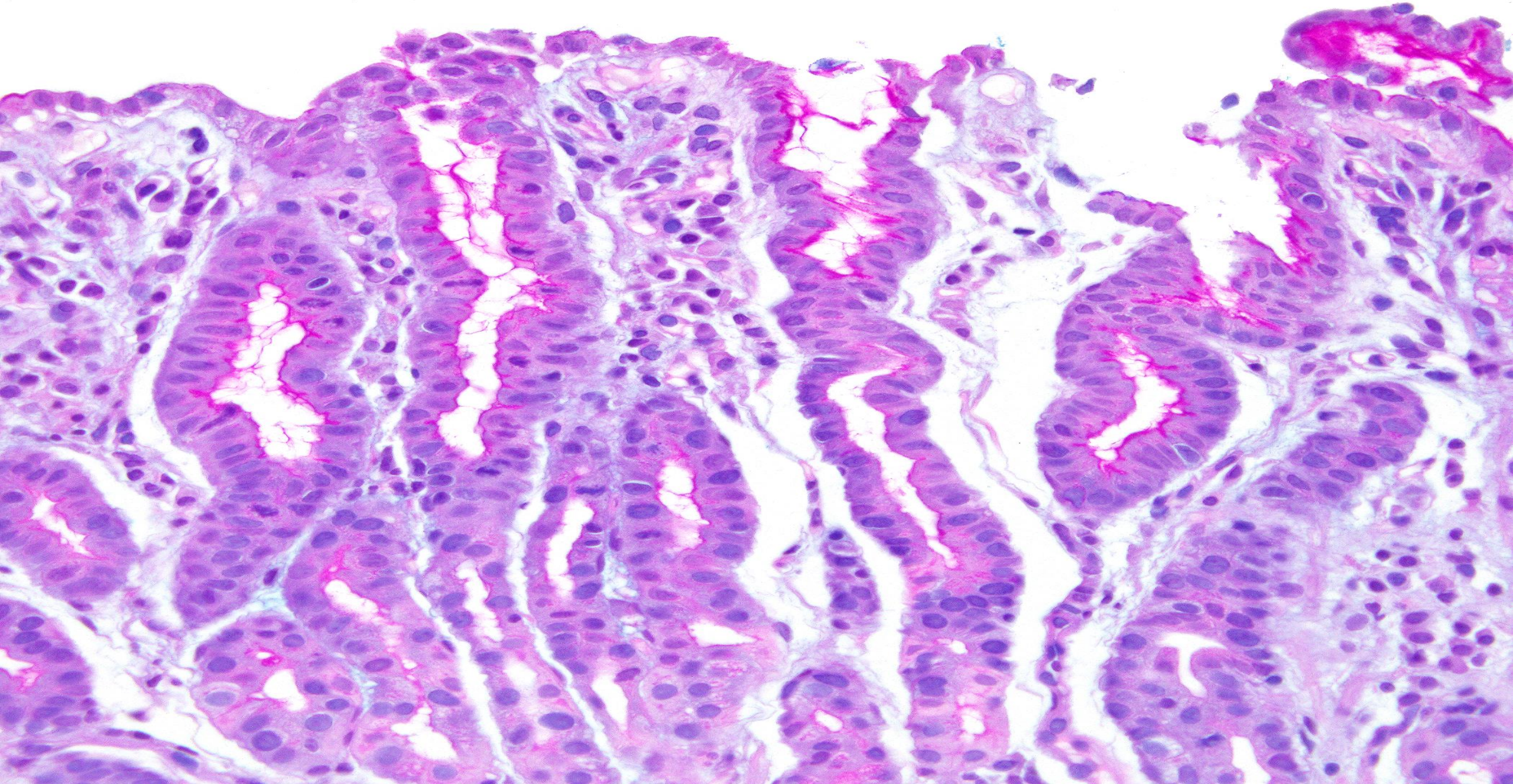

Stomach – Neuroendocrine tumors

Autoimmune gastritis matters in discussing gastric NETs

- Inherited predisposition
- Antibodies to parietal cells/intrinsic factor
- Possible link to *H. pylori*
- Possible increased risk for gastric carcinoma (but seems less likely in the absence of prior H. pylori infection)*.
- Hypochlorohydria from parietal cell loss, iron deficiency anemia, ultimately pernicious anemia.
- Patients often develop “Type 1 carcinoids”

Rugge M, Bricca L, Guzzinati S, Sacchi D, Pizzi M, Savarino E, Farinati F, Zorzi M, Fassan M, Dei Tos AP, Malfertheiner P, Genta RM, Graham DY. Autoimmune gastritis: long-term natural history in naïve *Helicobacter pylori*-negative patients. Gut. 2023 Jan;72(1):30-38. PMID: 35772926.

Metaplastic Atrophic Gastritis (MAG)

Autoimmune vs. H. pylori Types

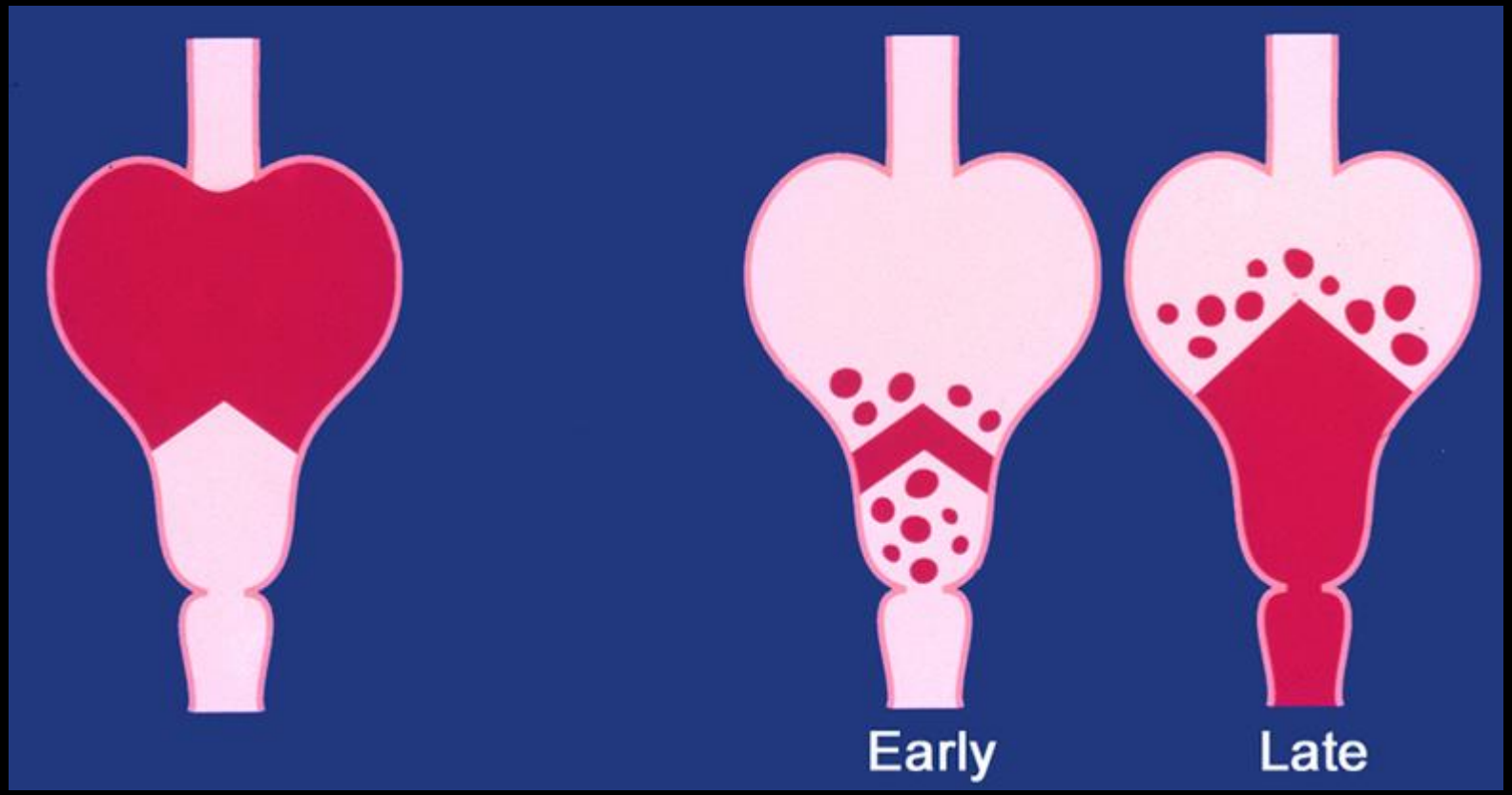

Autoimmune

H. pylori

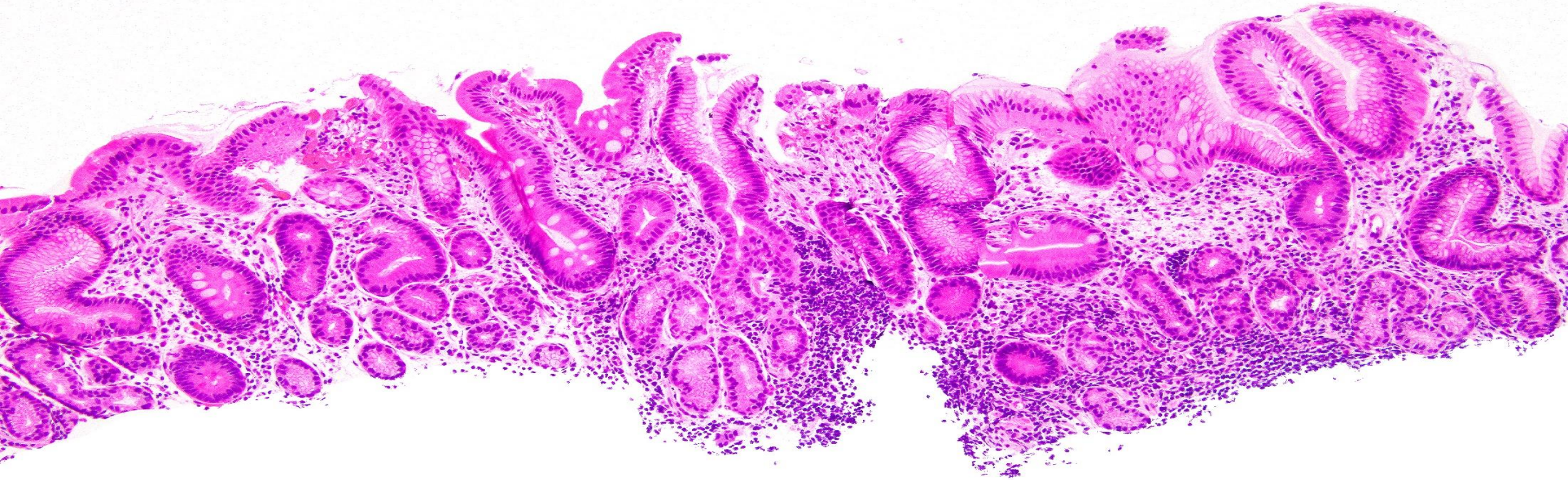

Gastric body with absent parietal cells and intestinal and (pseudo)pyloric metaplasia (antralization)

Autoimmune gastritis,
pancreatic metaplasia

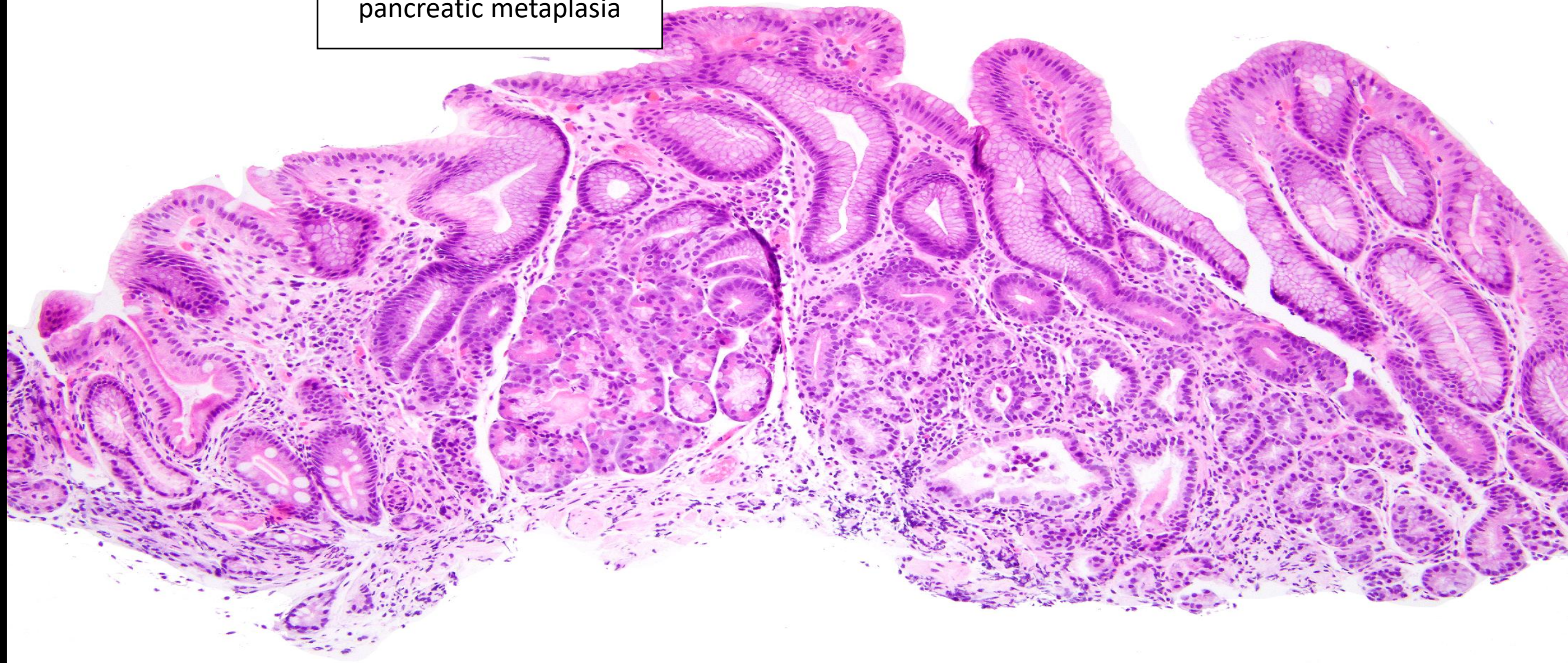

Chromogranin stain

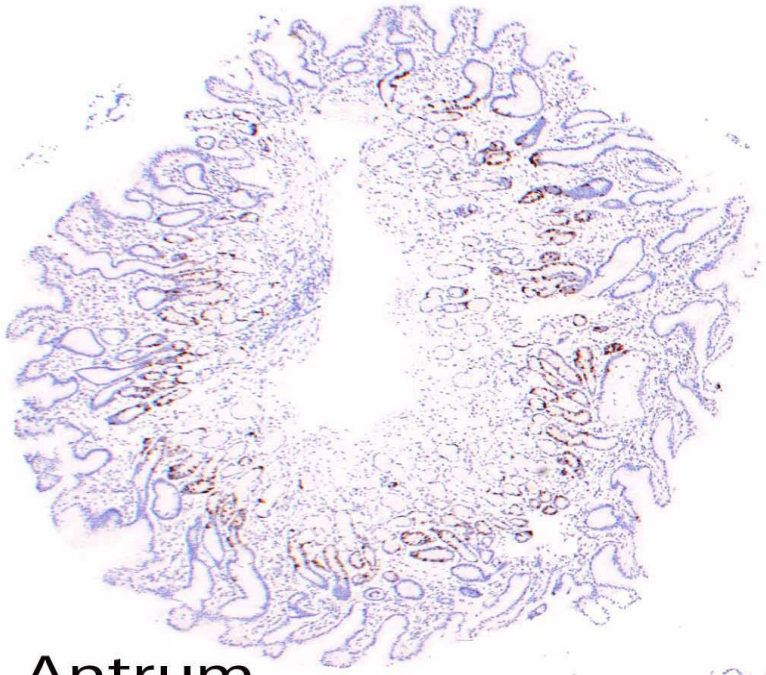

Antrum

The G cells are stained by chromogranin in an orderly fashion; you don't really need the gastrin stain.

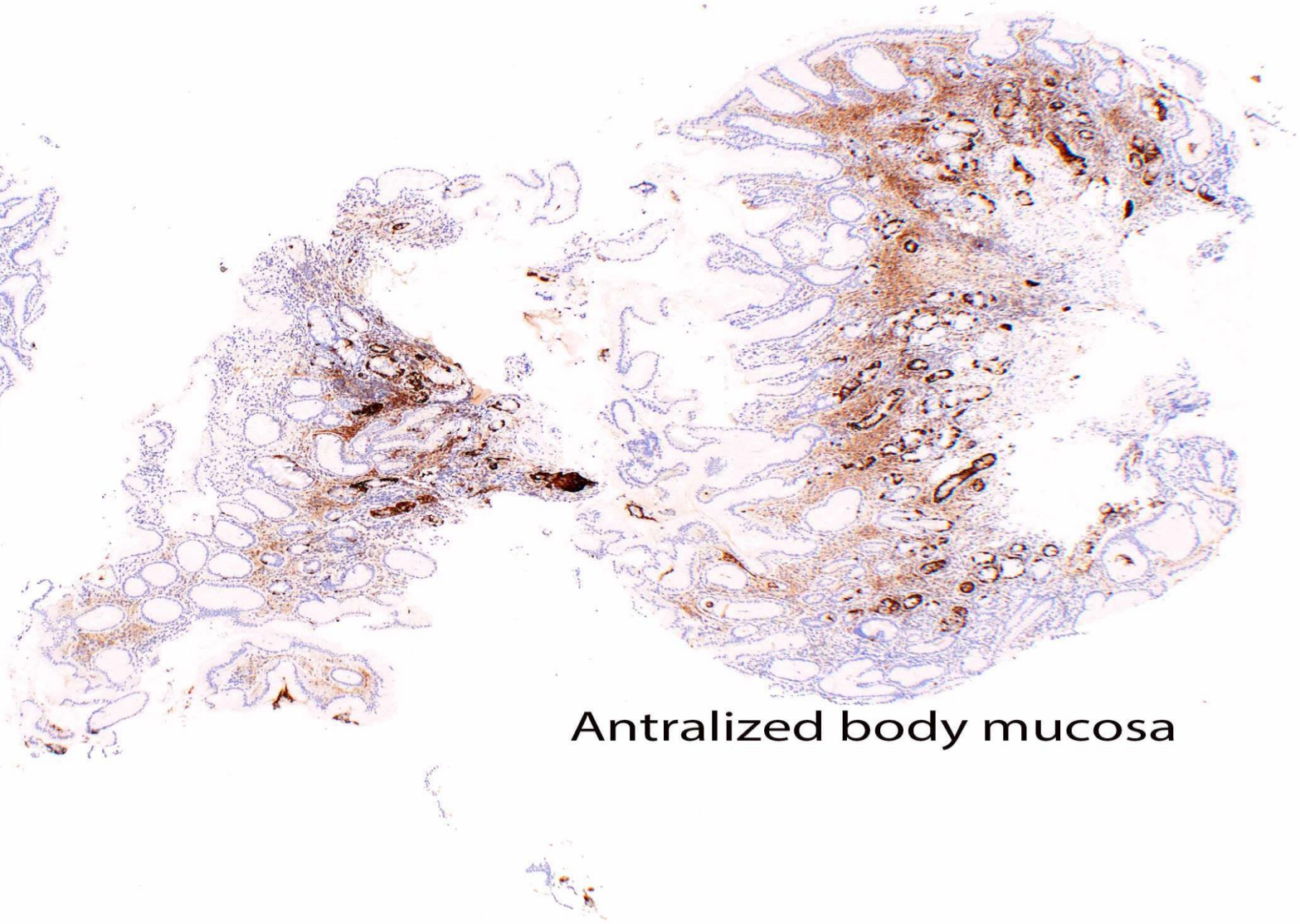

Antralized body mucosa

Evolving autoimmune gastritis –

Pittman ME, Voltaggio L, Bhaijee F, Robertson SA, Montgomery EA. Autoimmune Metaplastic Atrophic Gastritis: Recognizing Precursor Lesions for Appropriate Patient Evaluation. Am J Surg Pathol. 2015 Dec;39(12):1611-20. PMID: 26291507.

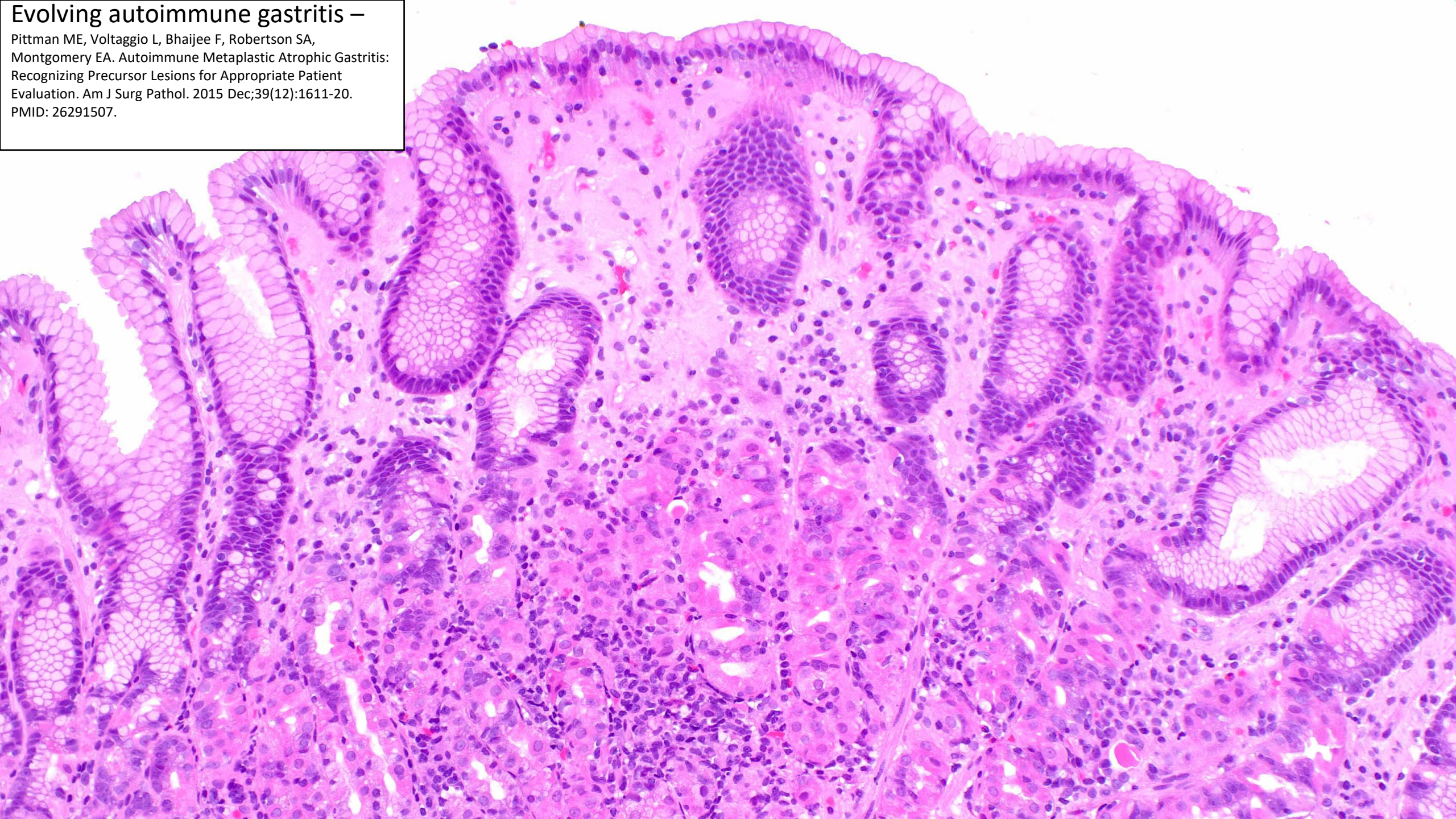

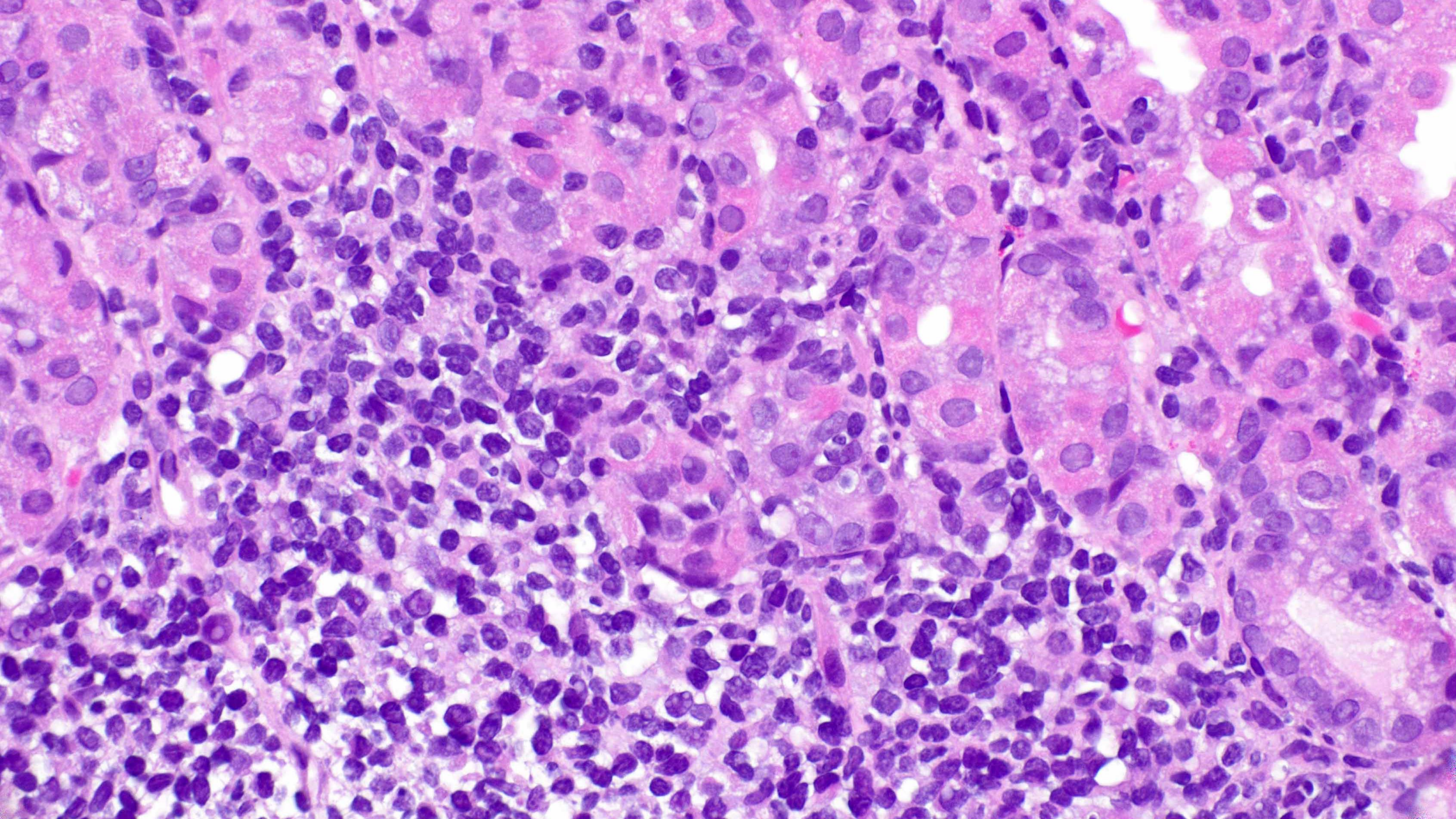

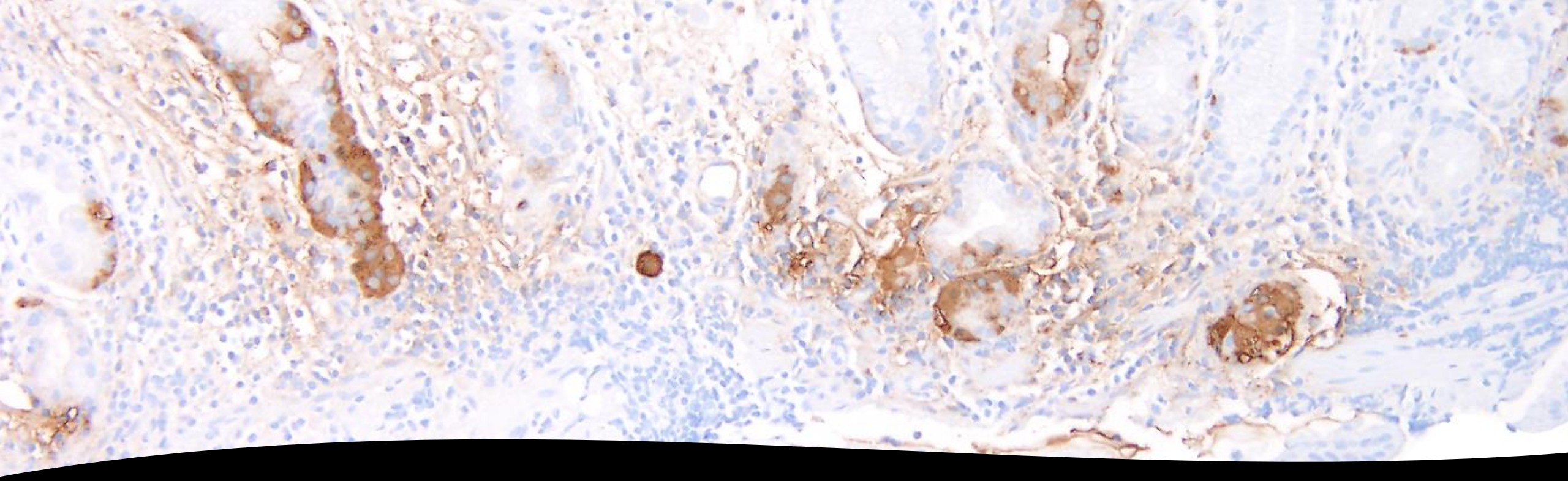

Body in evolving autoimmune gastritis– a chromogranin stain shows ECL cell hyperplasia

H. Pylori gastritis v evolving autoimmune gastritis

H. Pylori gastritis involving gastric body

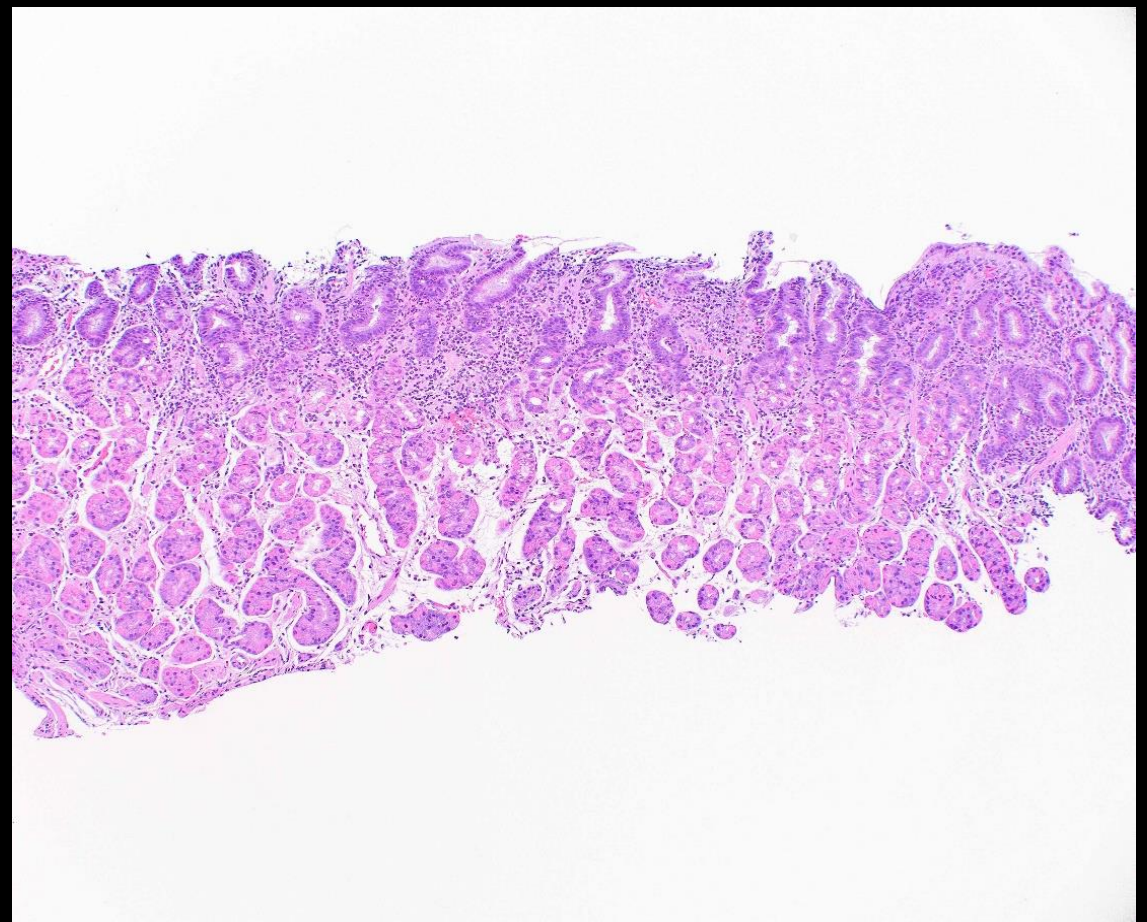

Evolving autoimmune gastritis involving gastric body

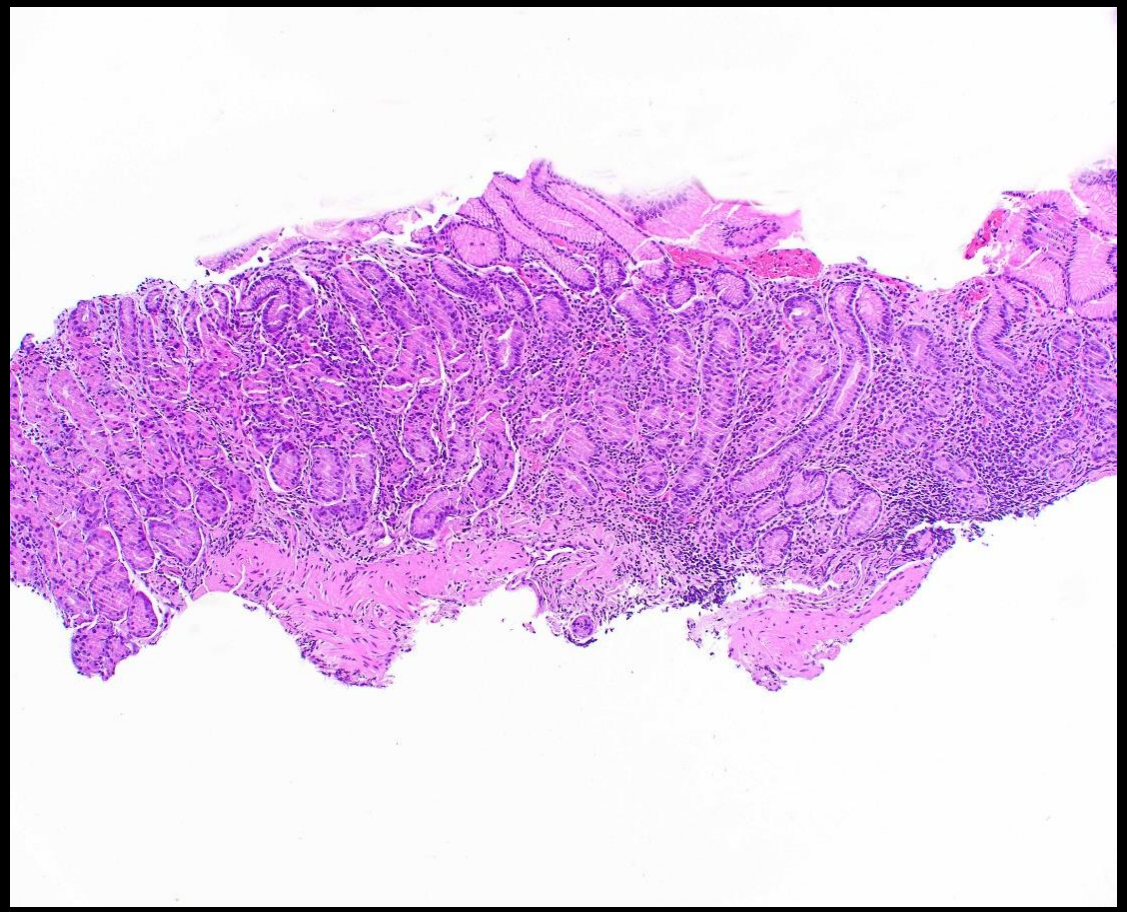

Autoimmune gastritis – patchy distribution

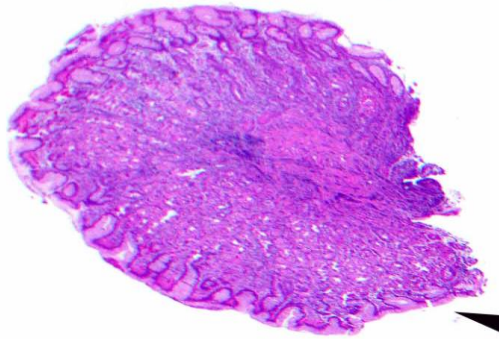

All biopsies show oxyntic (body/corpus) mucosa with variable damage in autoimmune gastritis

Patchy damage

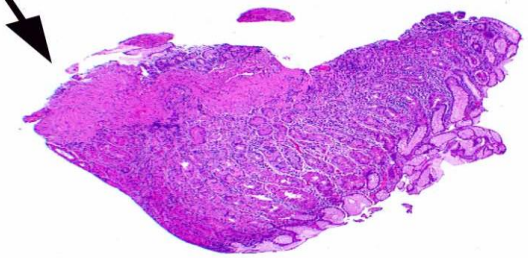

No damage

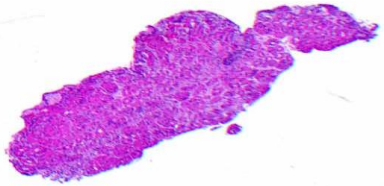

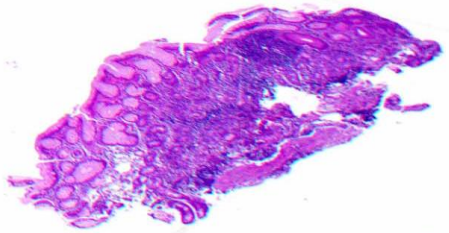

Extensive damage; no parietal cells

When Does It Stop Being ECL Cell Hyperplasia and Become Carcinoid?

- Extensive literature on hyperplasia-dysplasia-neoplasia – no practical value
- Some use a cut-off of 0.5 mm as “carcinoid”
- The WHO is not clear on a cut-off size.
- Our definition – if the endoscopist sees a nodule it’s a carcinoid/WDNET of ECL cell type.

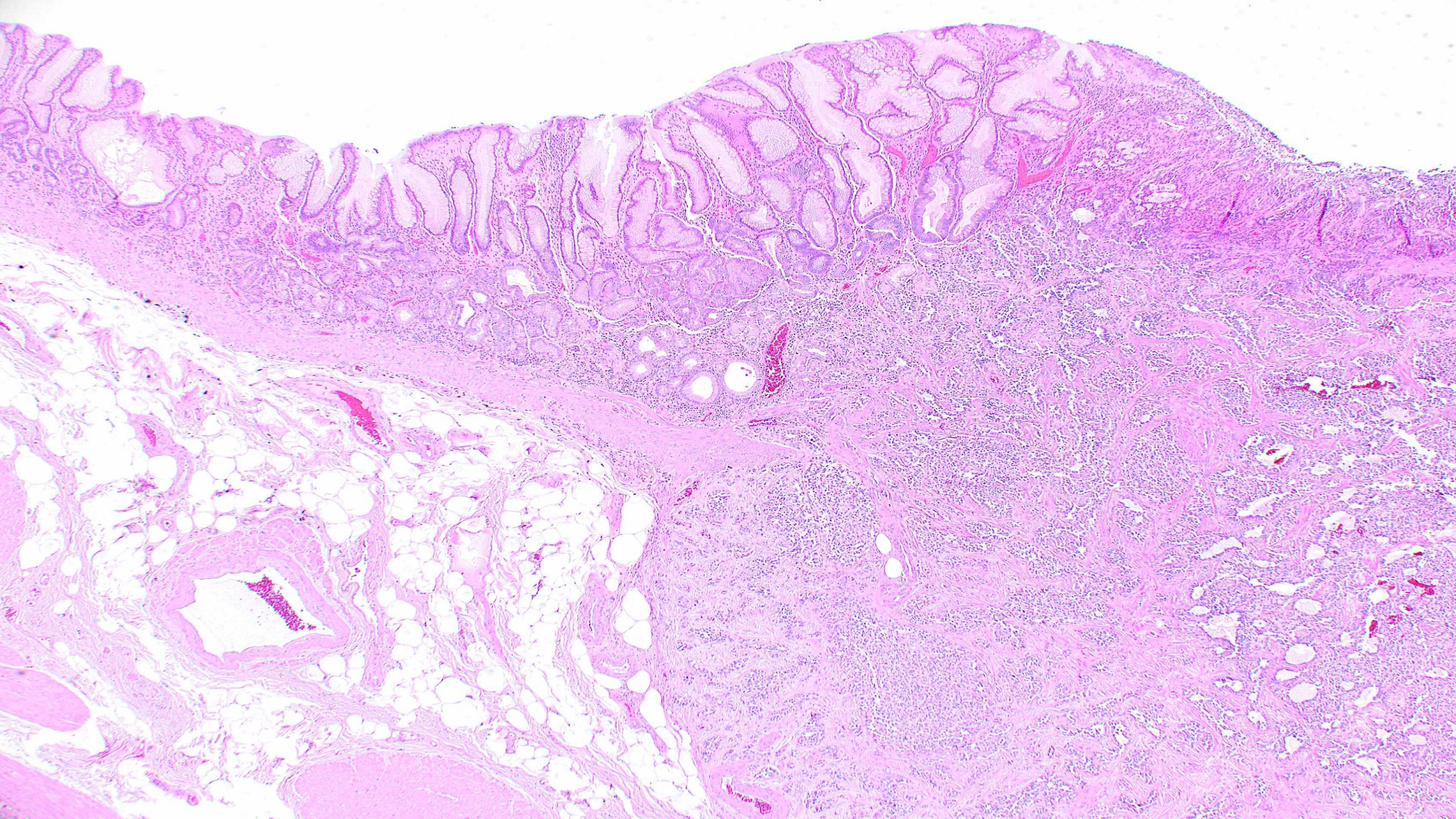

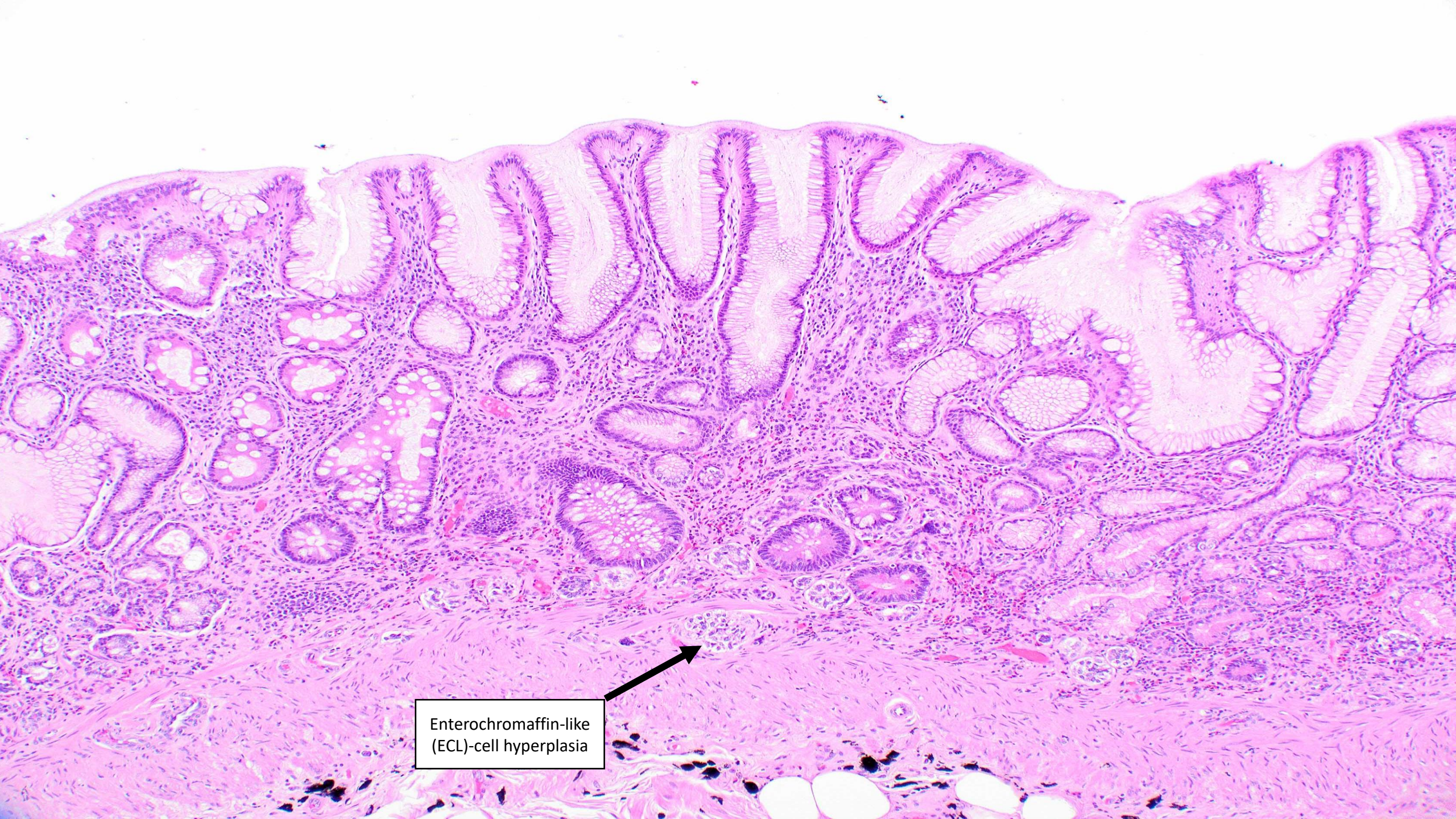
Enterochromaffin-like
(ECL)-cell hyperplasia

- Type 1 carcinoid – Tremendous morphologic variability

- Poveda JC, Chahar S, Garcia-Buitrago MT, Montgomery EA, McDonald OG. The Morphologic Spectrum of Gastric Type 1 Enterochromaffin-Like Cell Neuroendocrine Tumors. Mod Pathol. 2023 Apr;36(4):100098. PMID: 36913909; PMCID: PMC10121960.
- Poveda JC, Park JY, Garcia-Buitrago MT, Singhi A, Alruwaii Z, Kumar S, McDonald OG, Montgomery EA. Autoimmune Metaplastic Atrophic Gastritis (AMAG): Regional Demographics and Their Effect on Prevalence. Int J Surg Pathol. 2024 Oct 1:10668969241271311. PMID: 39350751.

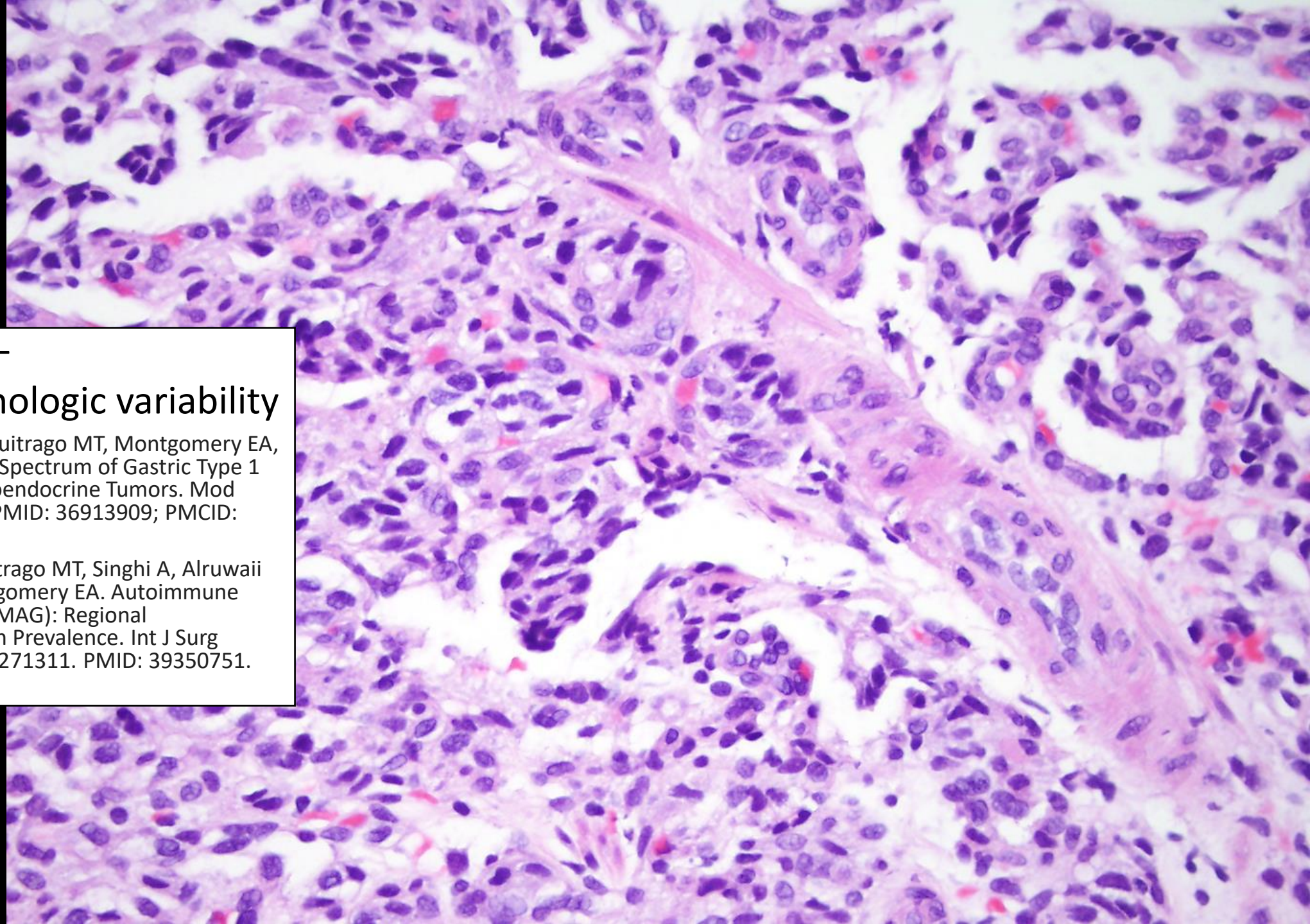

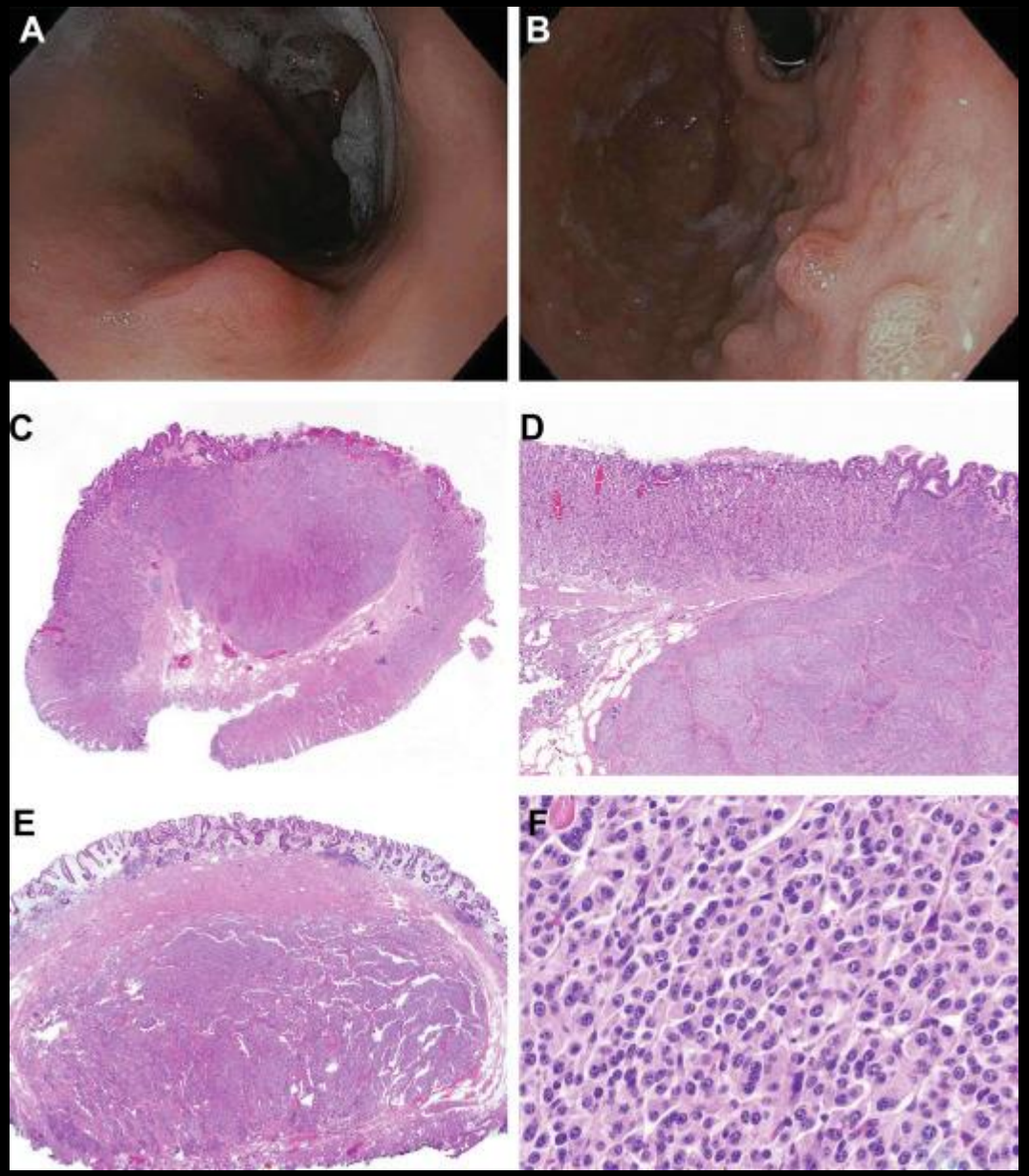

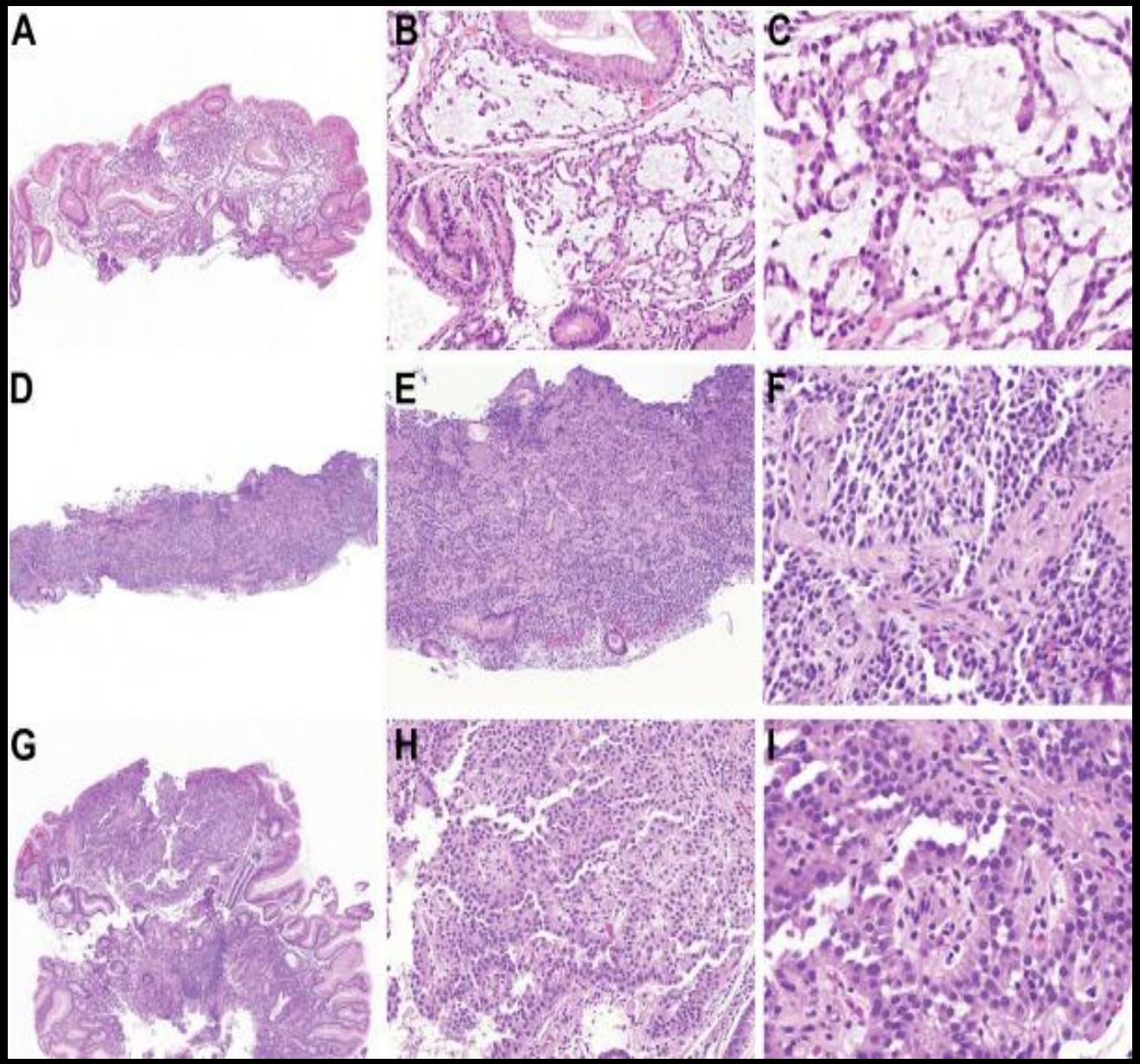

Poveda JC, Chahar S, Garcia-Buitrago MT, Montgomery EA, McDonald OG. The Morphologic Spectrum of Gastric Type 1 Enterochromaffin-Like Cell Neuroendocrine Tumors. Mod Pathol. 2023 Apr;36(4):100098. PMID: 36913909; PMCID: PMC10121960.

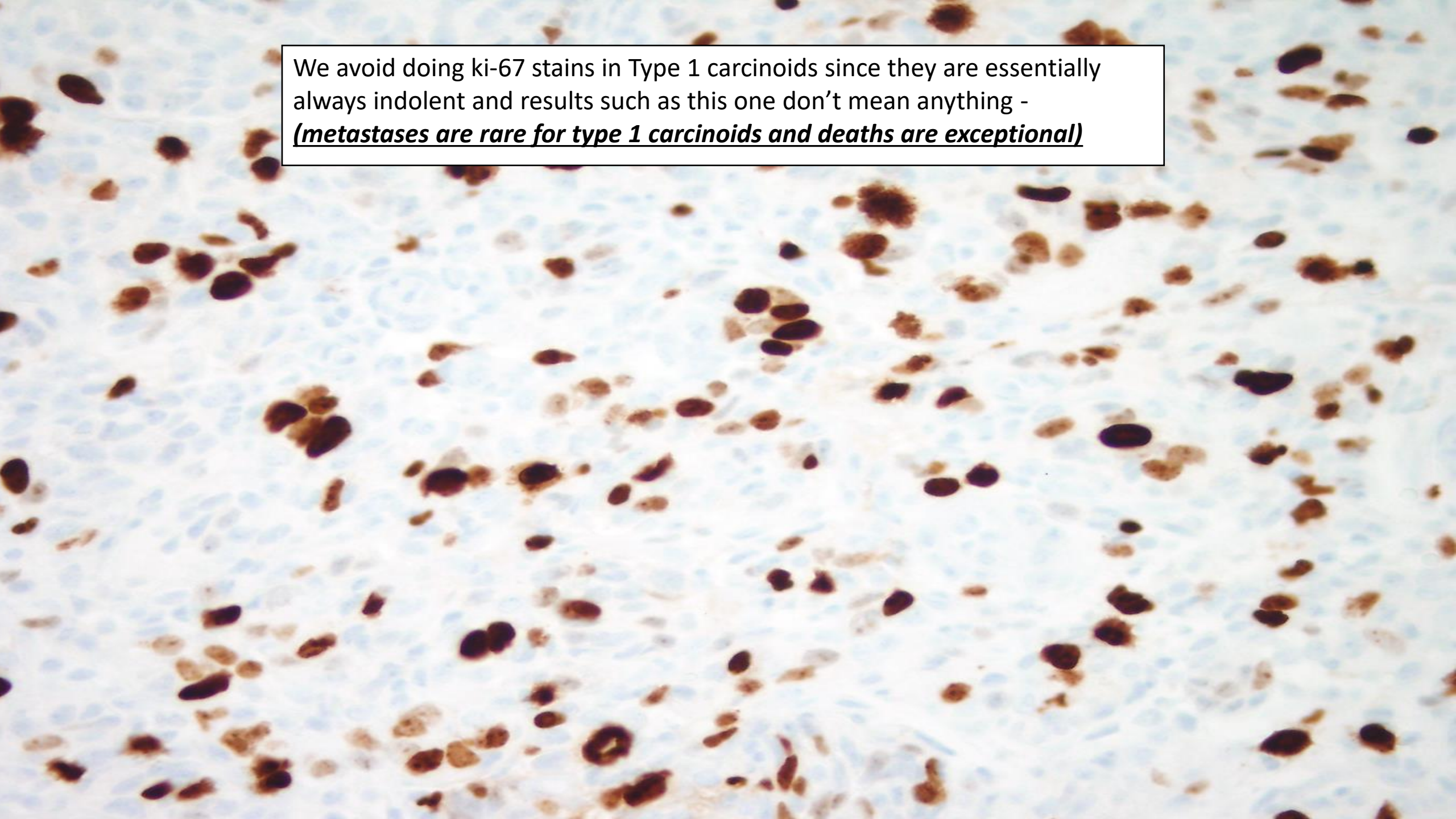

We avoid doing ki-67 stains in Type 1 carcinoids since they are essentially always indolent and results such as this one don't mean anything - ***(metastases are rare for type 1 carcinoids and deaths are exceptional)***

Case

Slide A is from the duodenum and slide B is from the stomach. What syndrome can you dream up to explain these findings?

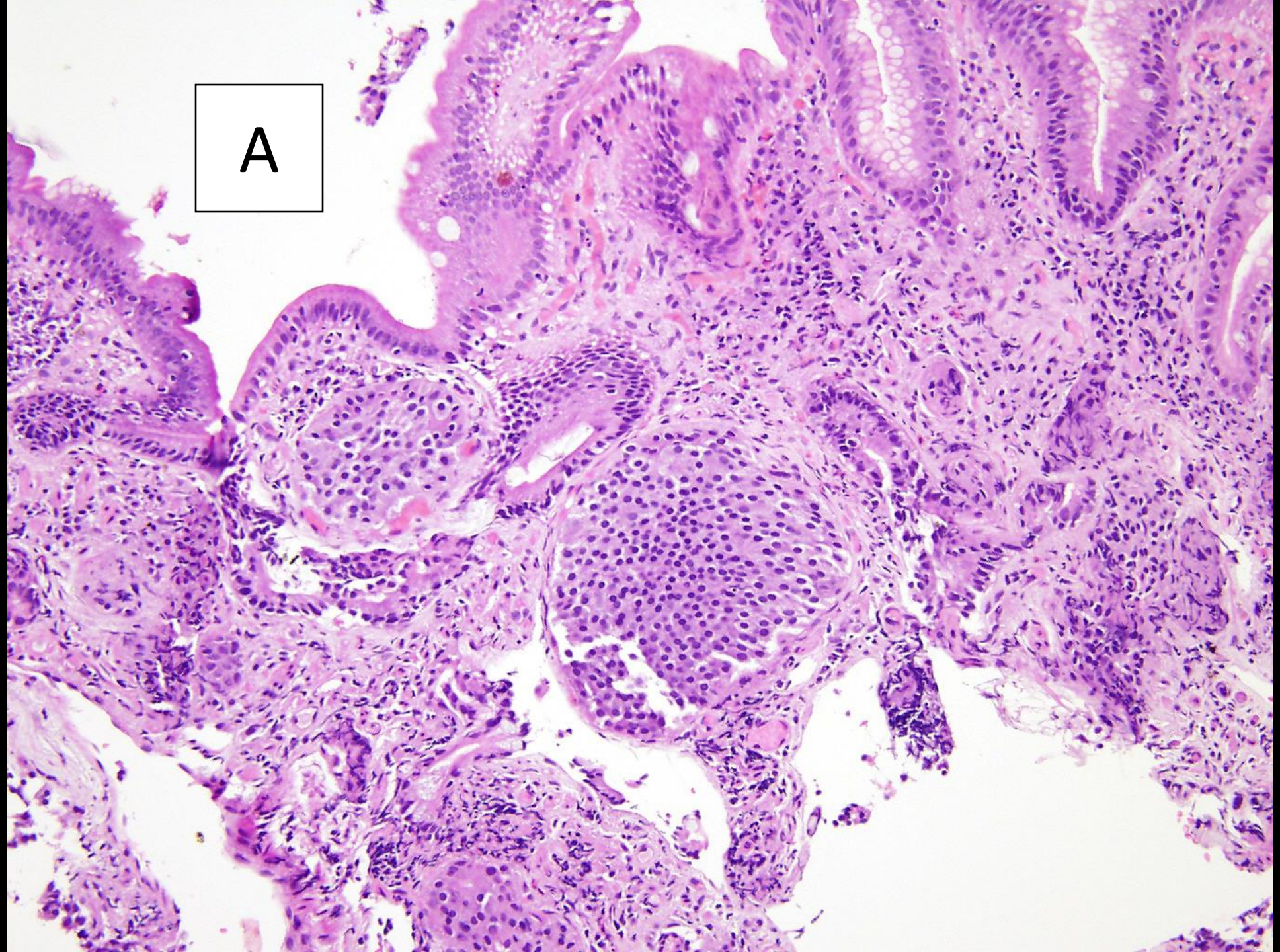
A

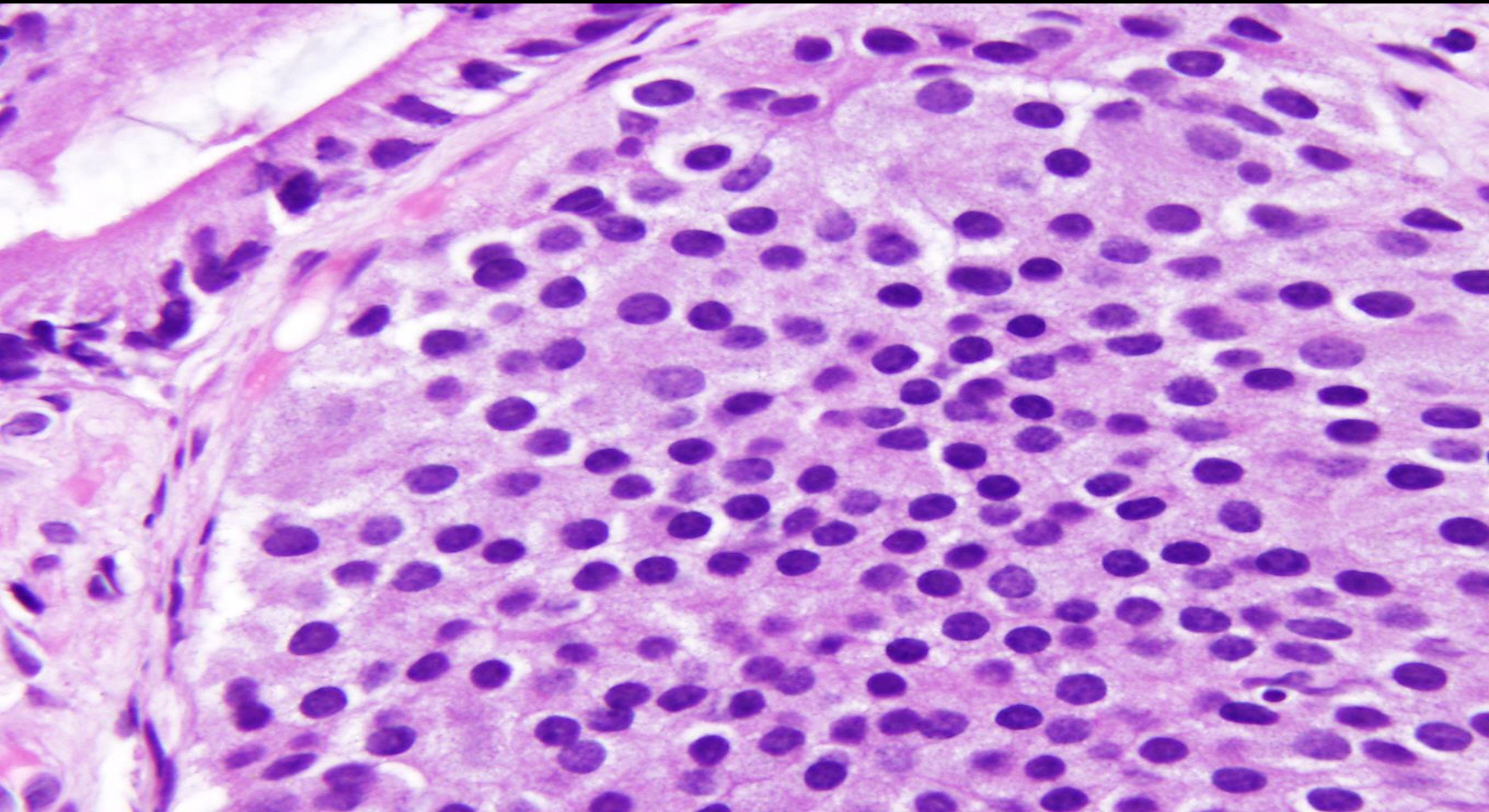

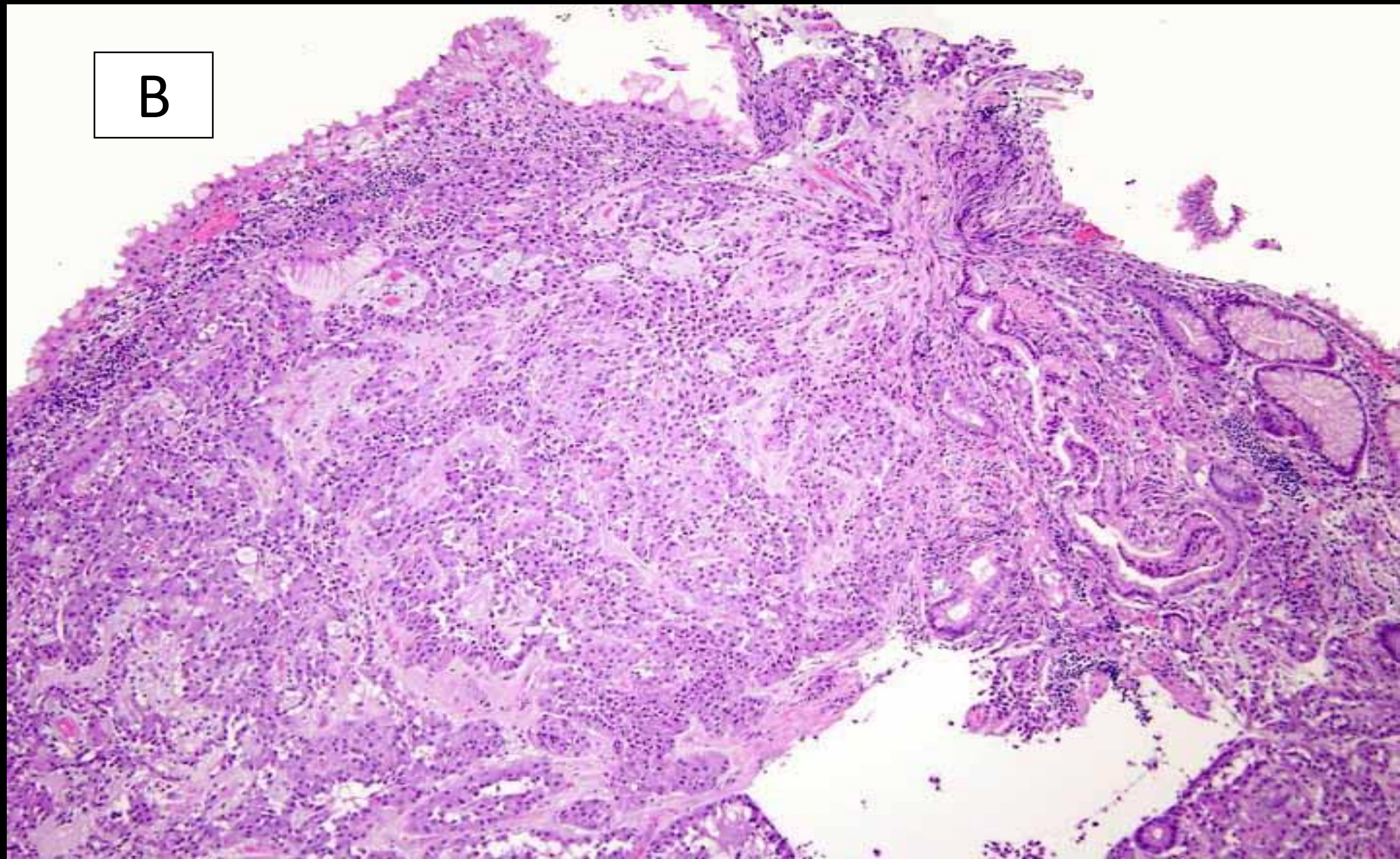
B

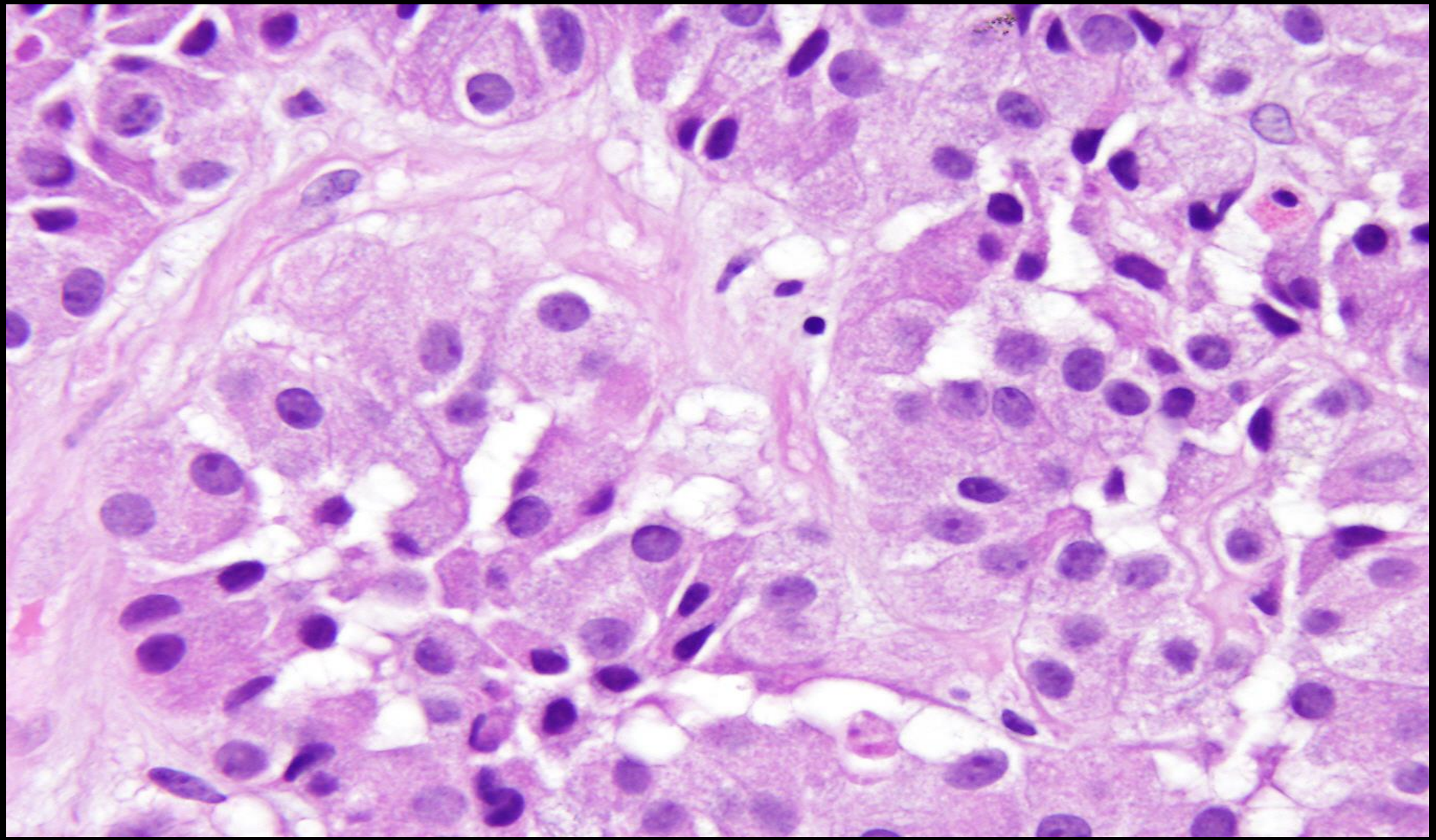

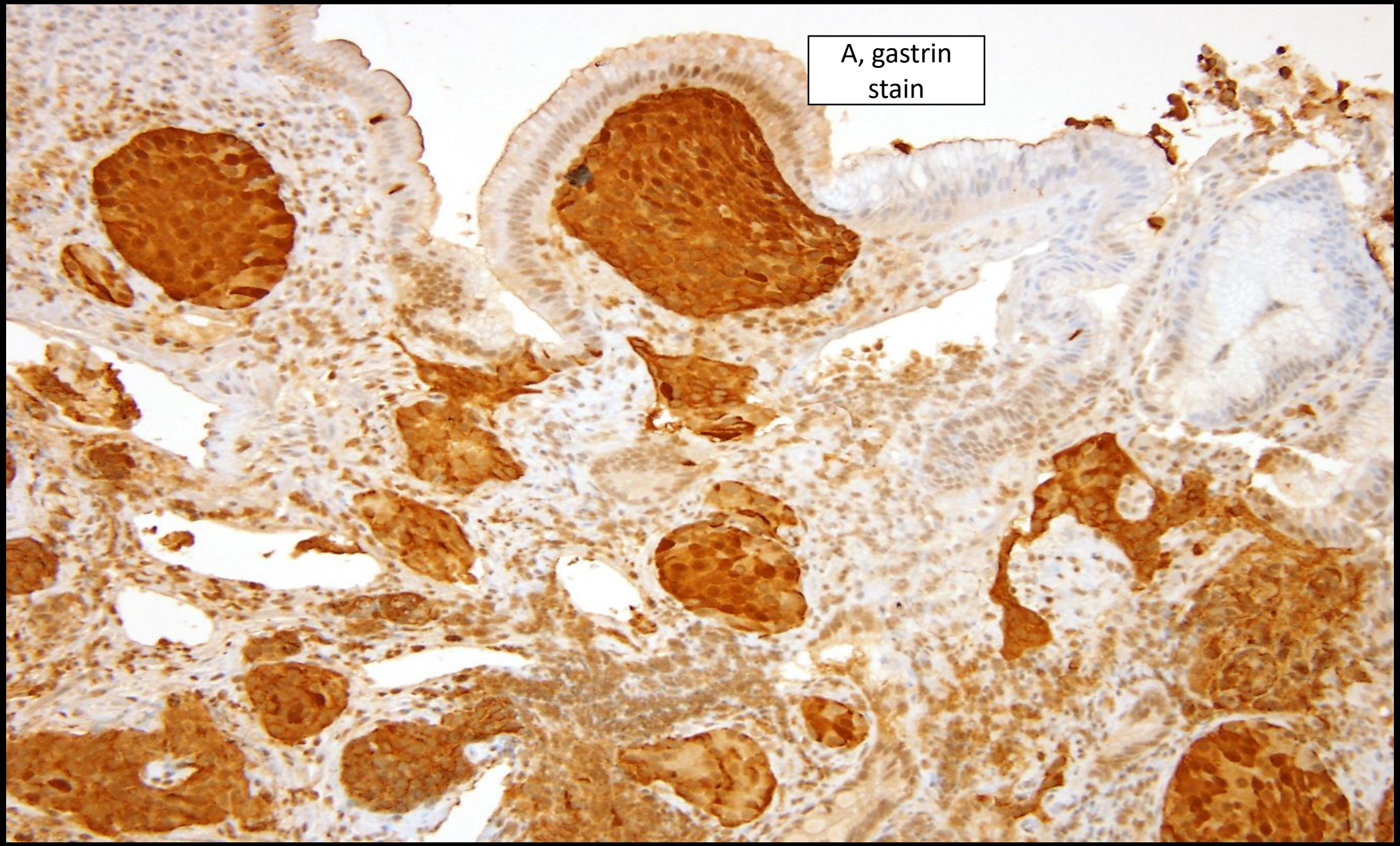
A, gastrin stain

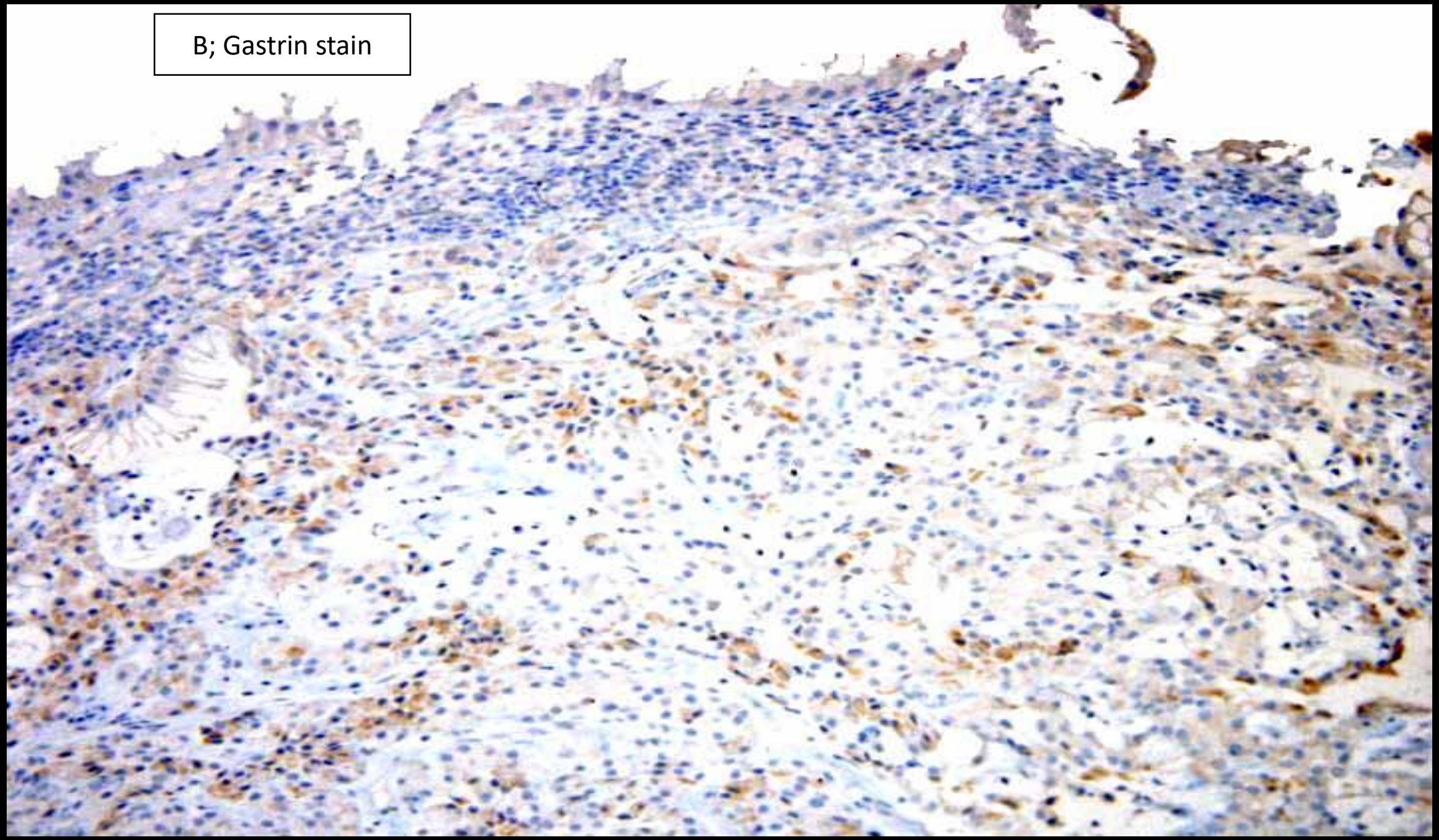
B; Gastrin stain

Diagnosis – Zollinger-Ellison Syndrome with a duodenal gastrinoma and a gastric carcinoid tumor/WDNET of ECL cell type – Type 2 carcinoid

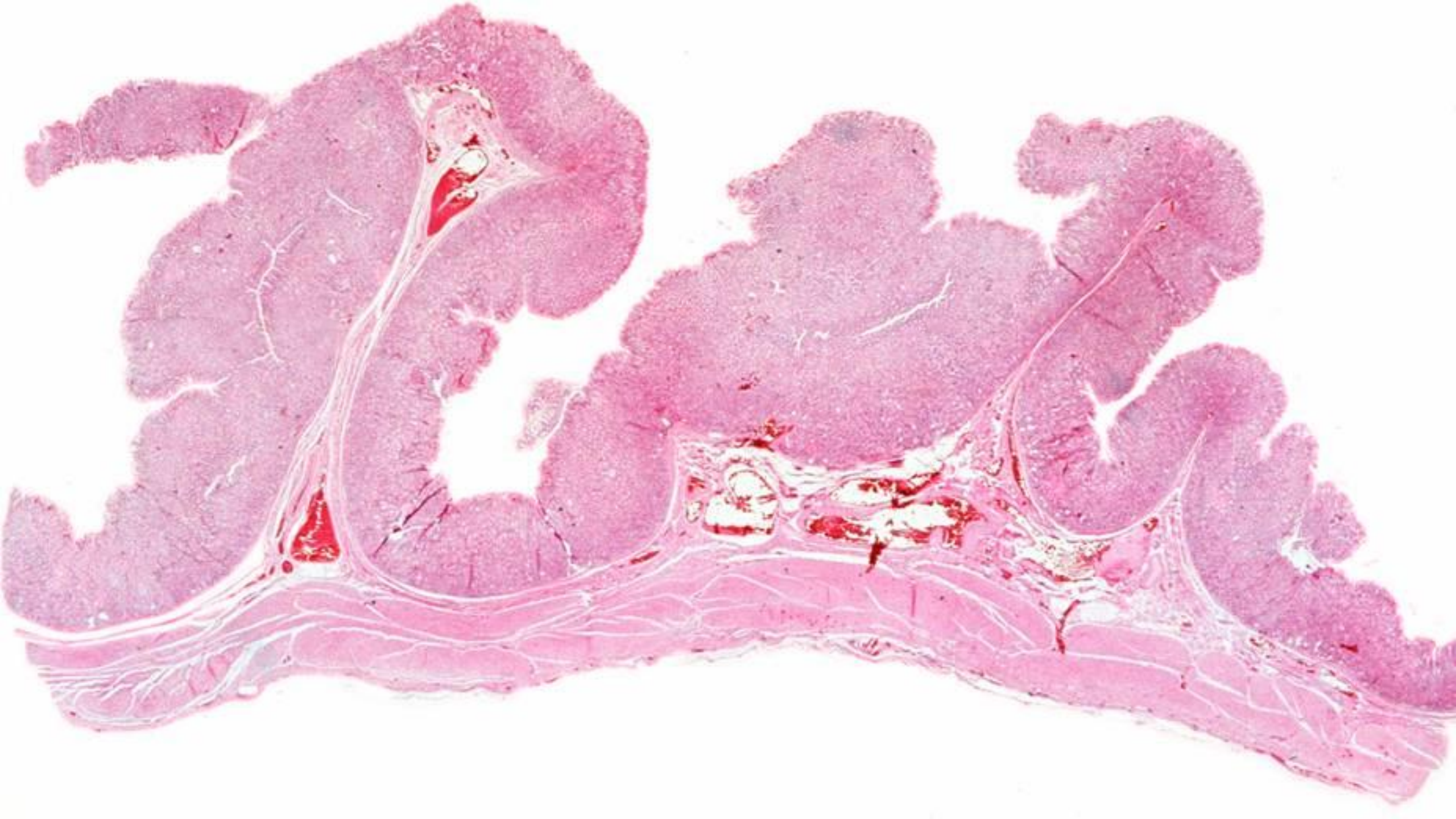

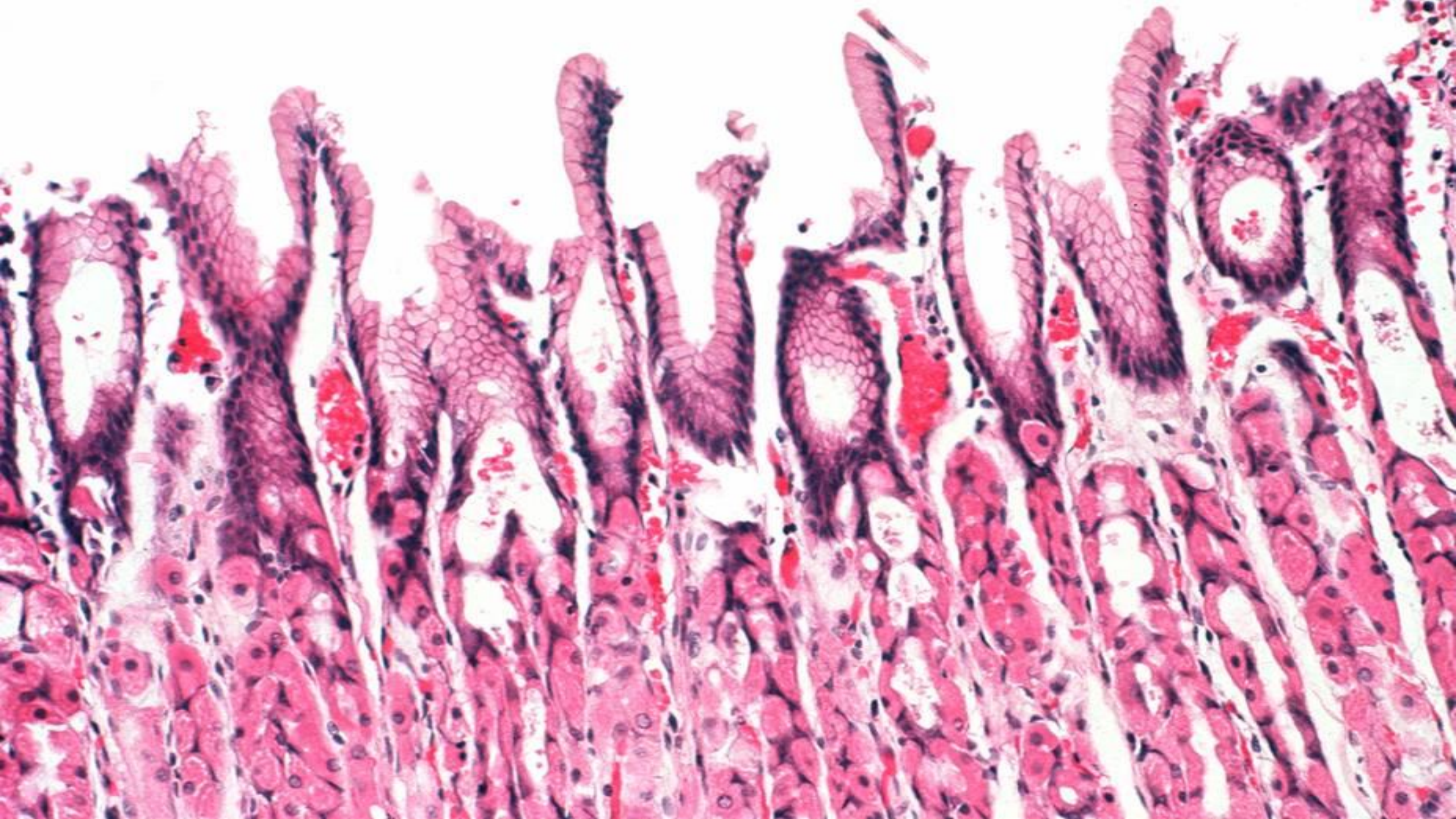

MEN-1

- Gene: Tumor suppressor gene on chromosome 11 (11q13)
- Pituitary: Prolactinomas, mass effect
- Parathyroid: Hyperparathyroidism, nephrolithiasis
- Pancreas-duodenum: Multicentric, gastrinomas, ulcers (PanNETs are leading cause of death)

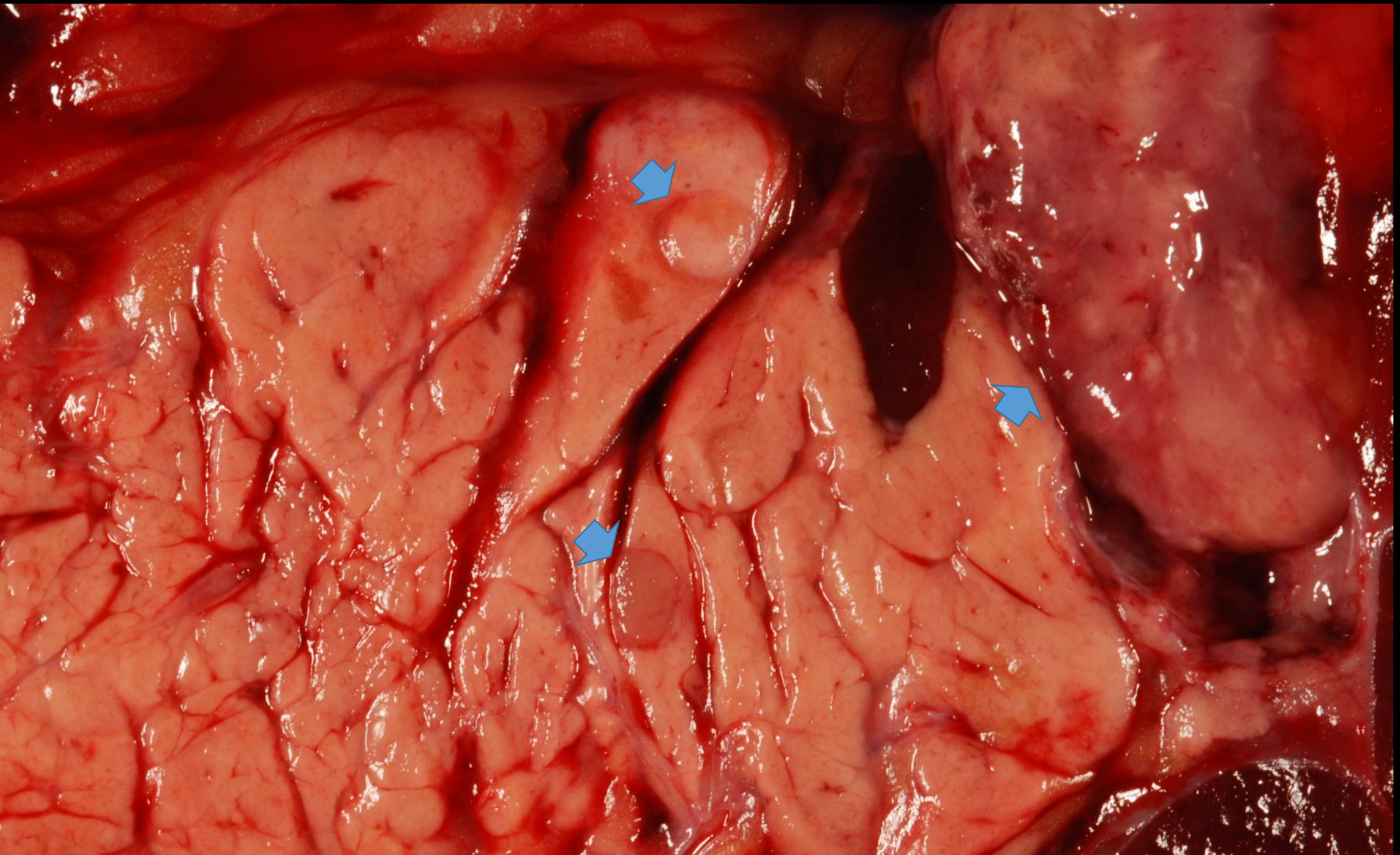

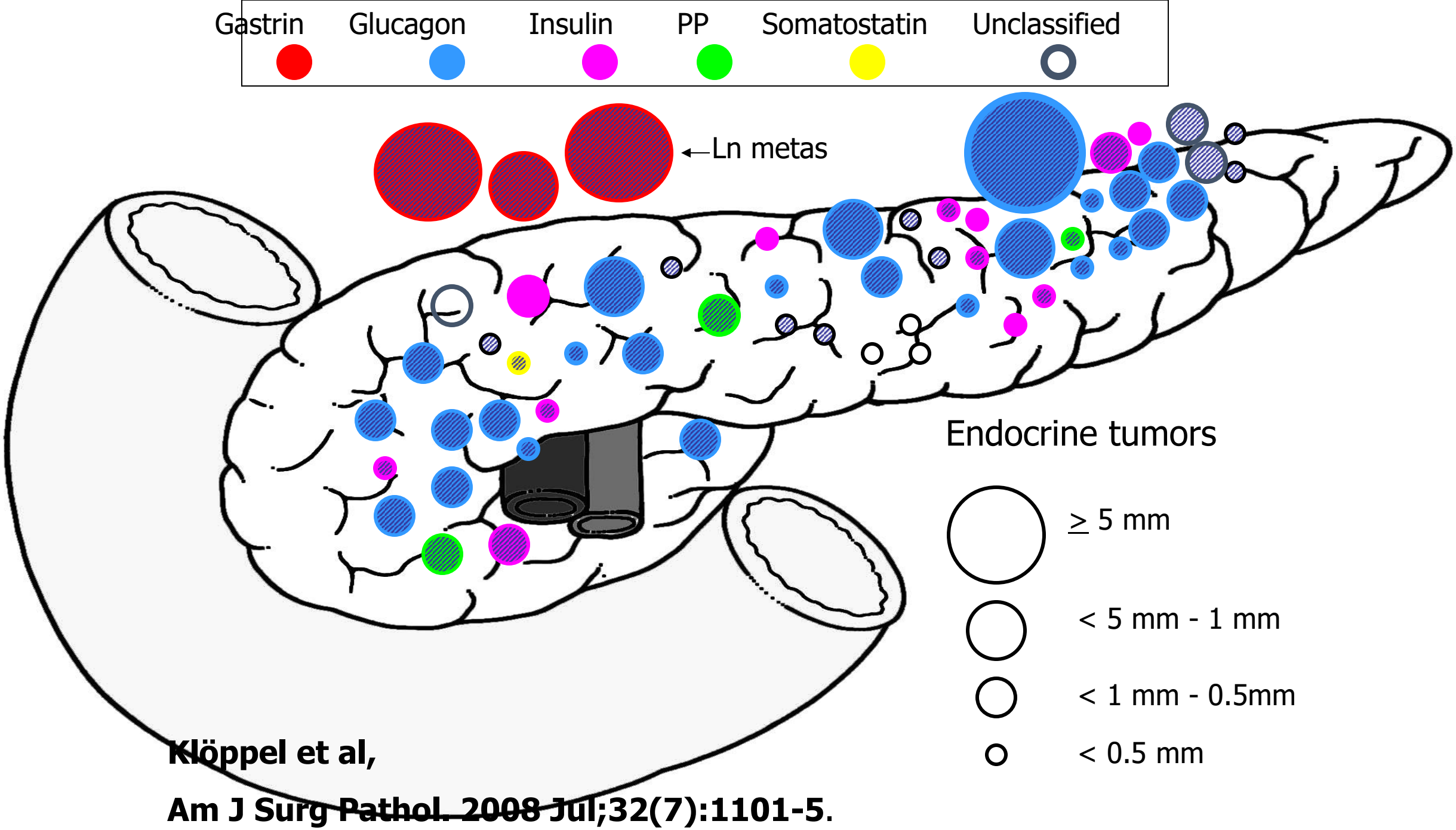

Klöppel et al,

Am J Surg Pathol. 2008 Jul;32(7):1101-5.

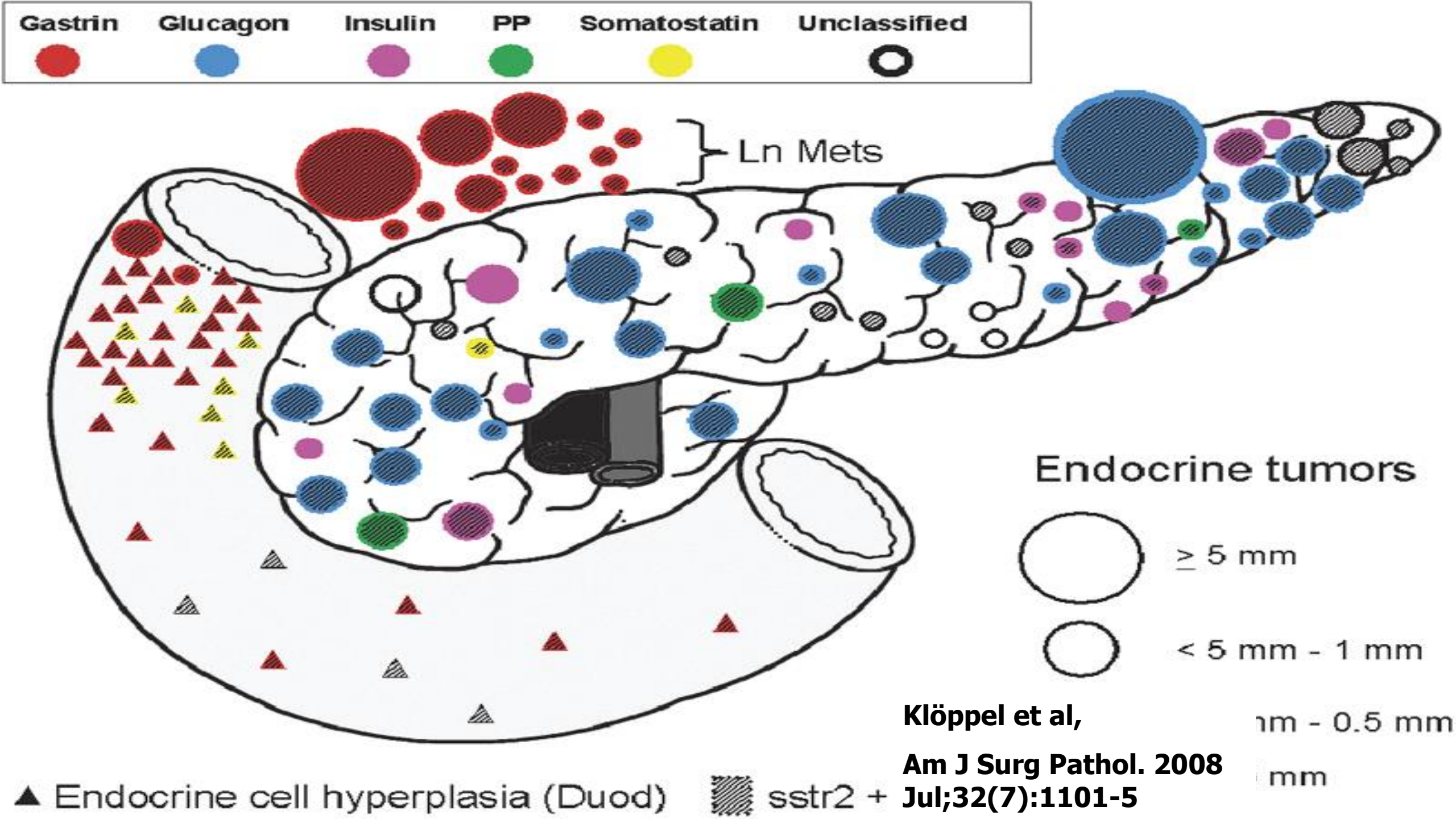

Klöppel et al,

Am J Surg Pathol. 2008 Jul;32(7):1101-5

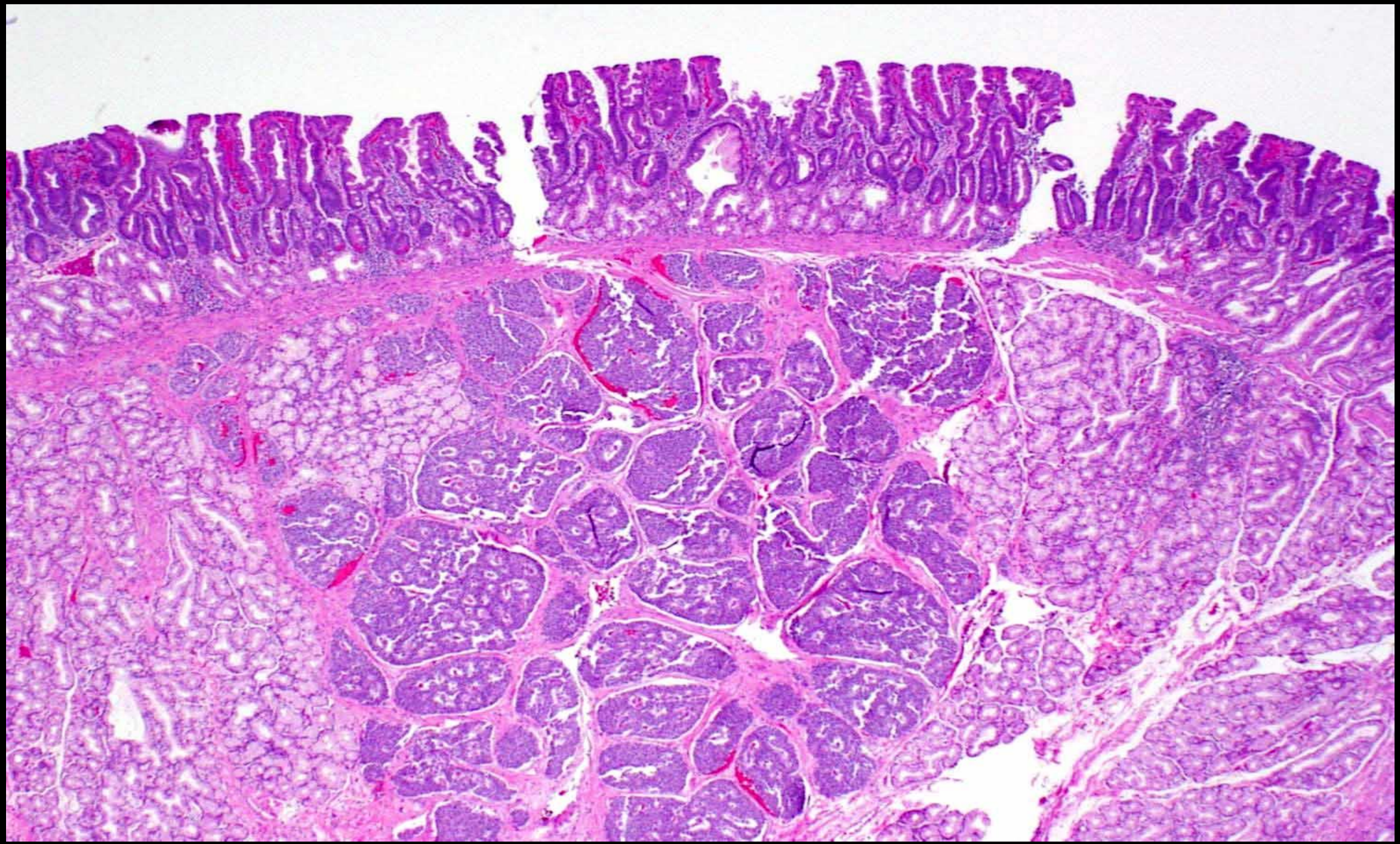

Gastrin

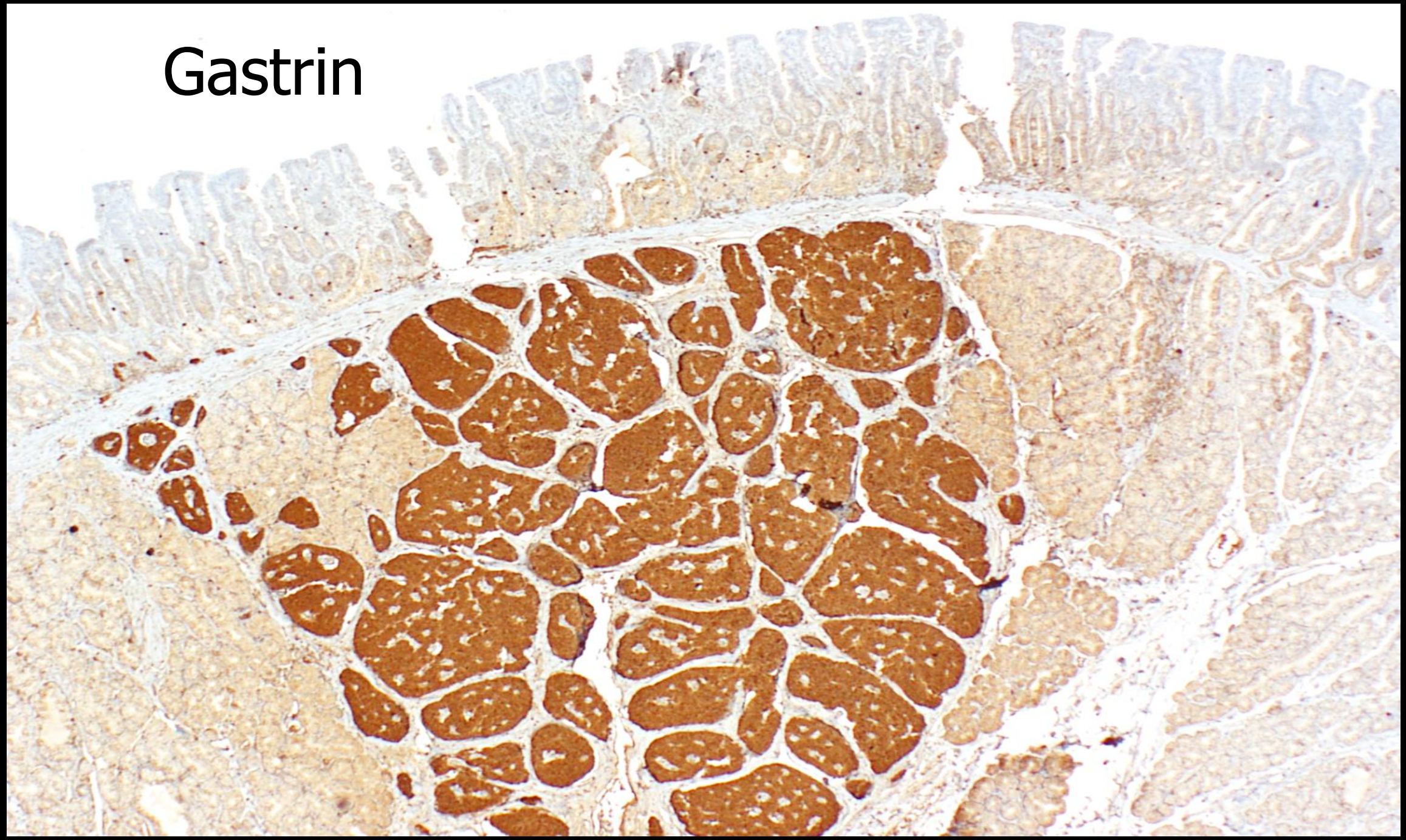

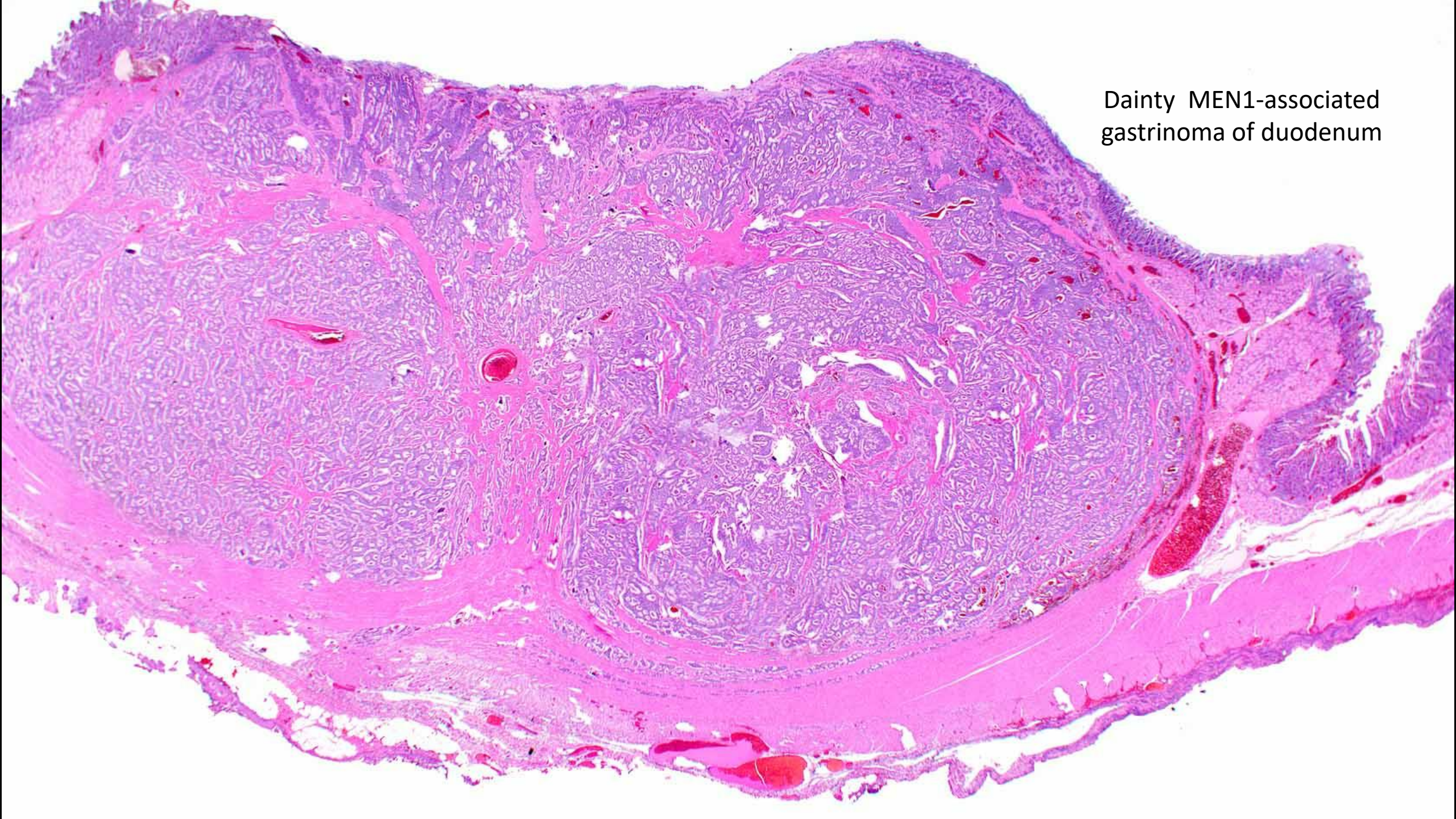
Dainty MEN1-associated
gastrinoma of duodenum

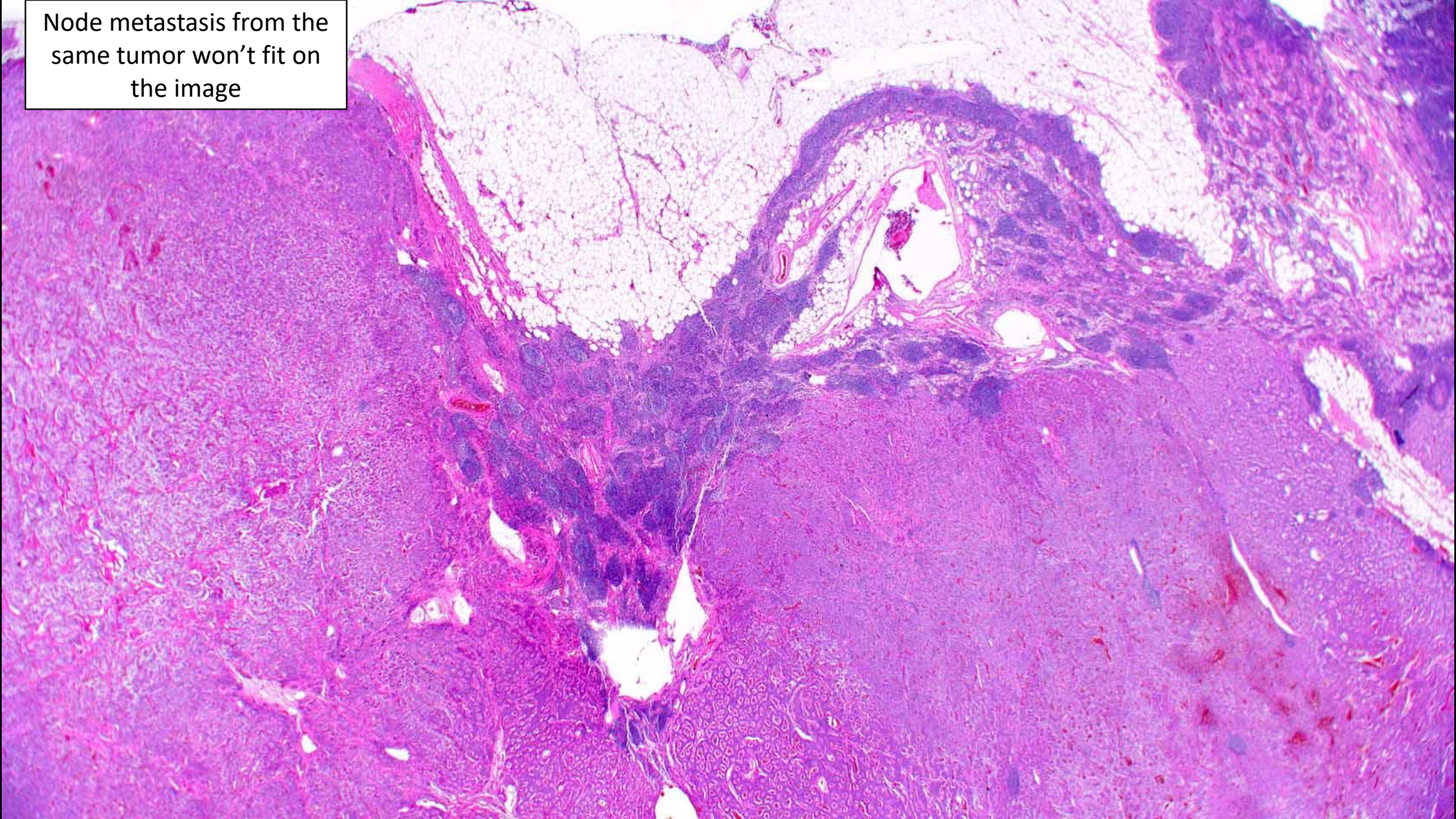
Node metastasis from the same tumor won’t fit on the image

Type 3 Gastric NET

- No autoimmune backdrop, no Zollinger Ellison (no gastrinoma)
- In other words, no hypergastrinemia
- More aggressive than type 1 with about a third dying of disease and metastases in about 70%
- ***(metastases are rare for type 1 and deaths are exceptional)***
- data poor on type 2 but they are indolent

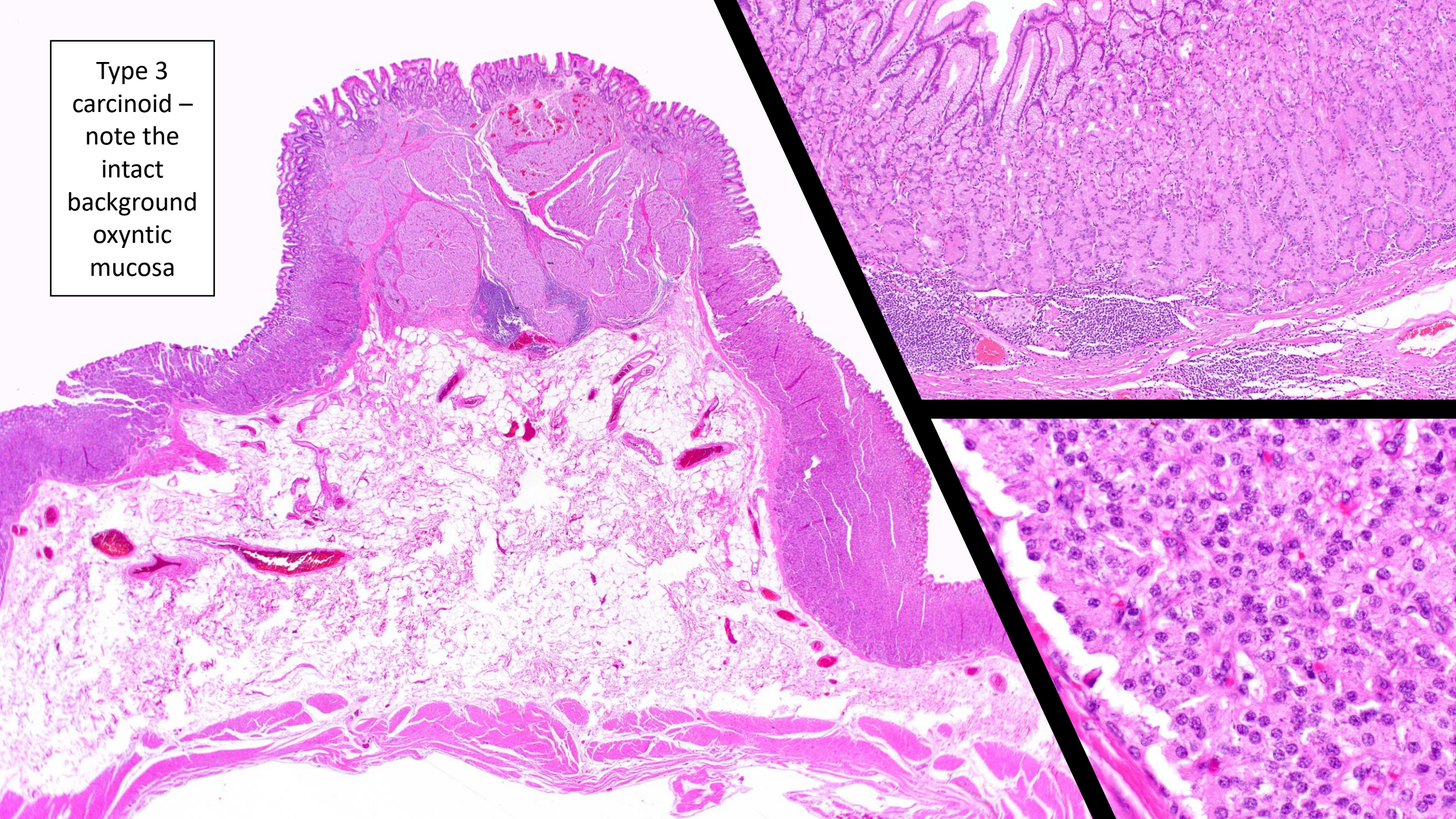
Type 3 carcinoid – note the intact background oxyntic mucosa

A Few Wrinkles

- Type 1 carcinoid - indolent
- Type 2 carcinoid – probably indolent
- Apparent Type 3 carcinoid – BAD – BUT a subset in patients with intact oxyntic mucosa on long-term PPI – these are indolent like Type 1 and 2* - "Type 5"
- Rare Type 4 carcinoid - Patients with hypergastrinemia related to defects of acid secretion by parietal cells, due probably to inactivating mutation of the *ATP4A* gene (encodes the H^+/K^+ ATPase alpha unit in parietal cells)

*Trinh VQ, Shi C, Ma C. Gastric neuroendocrine tumours from long-term proton pump inhibitor users are indolent tumours with good prognosis. Histopathology. 2020 Dec;77(6):865-876. PMID: 32702178.
*Rais R, Trikalinos NA, Liu J, Chatterjee D. Enterochromaffin-like Cell Hyperplasia-Associated Gastric Neuroendocrine Tumors May Arise in the Setting of Proton Pump Inhibitor Use. Arch Pathol Lab Med. 2022 Mar 1;146(3):366-371. PMID: 34283890.

Long term proton pump inhibitor use

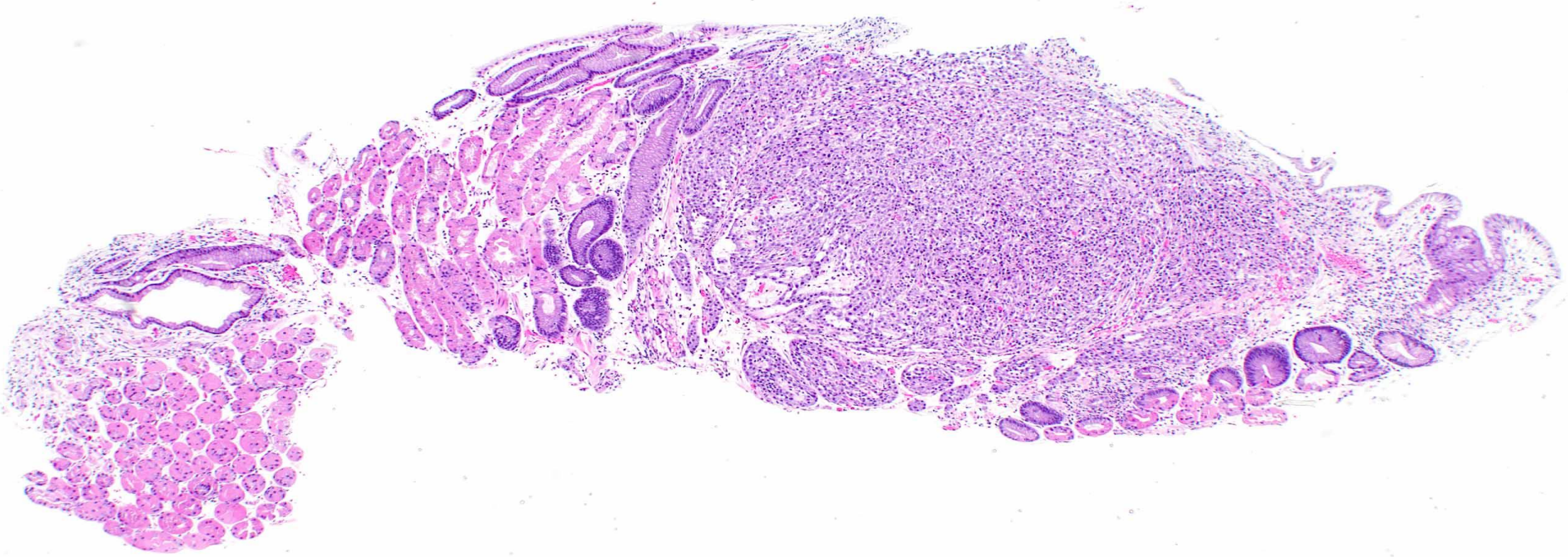

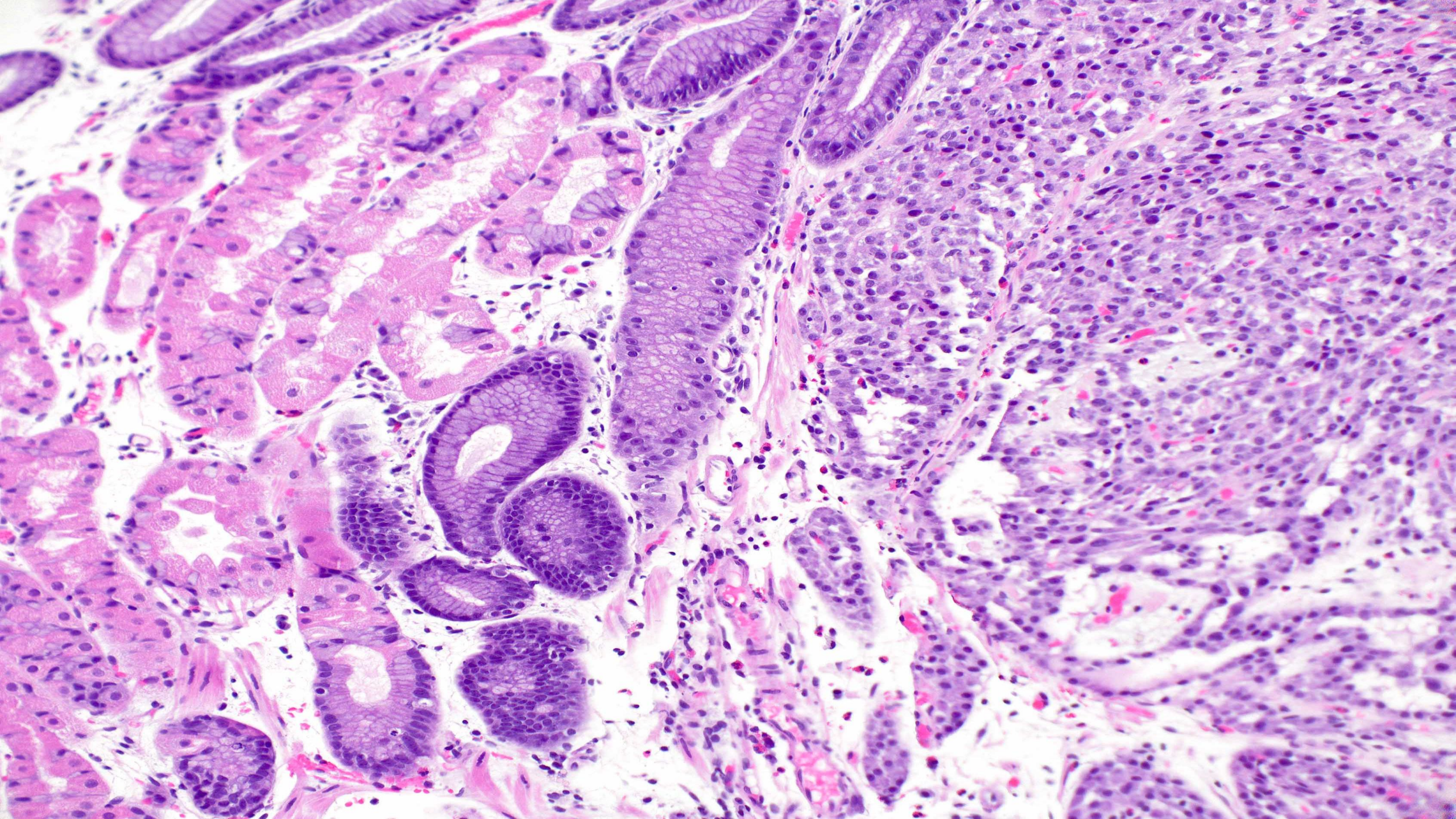

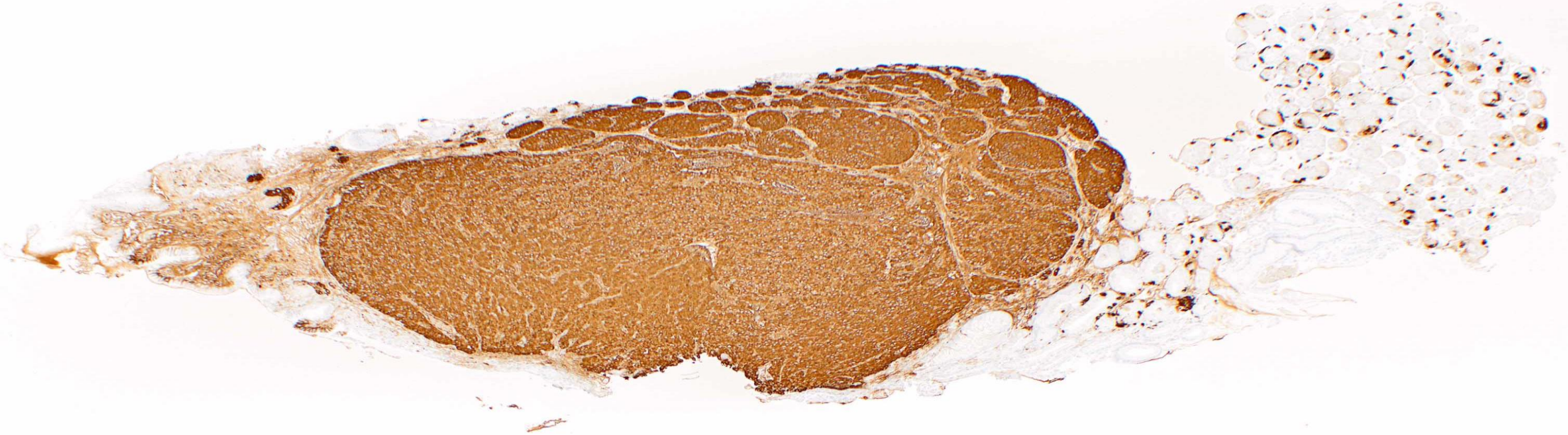

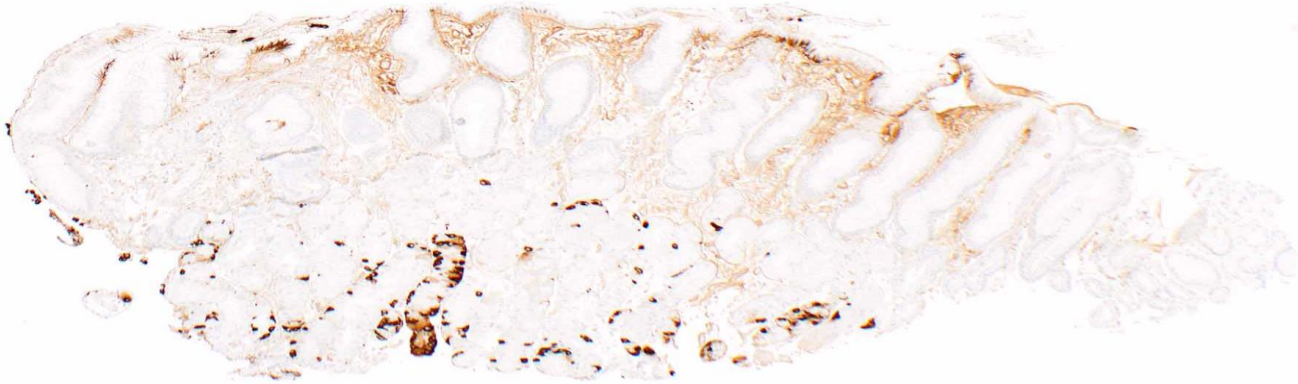

Chromogranin

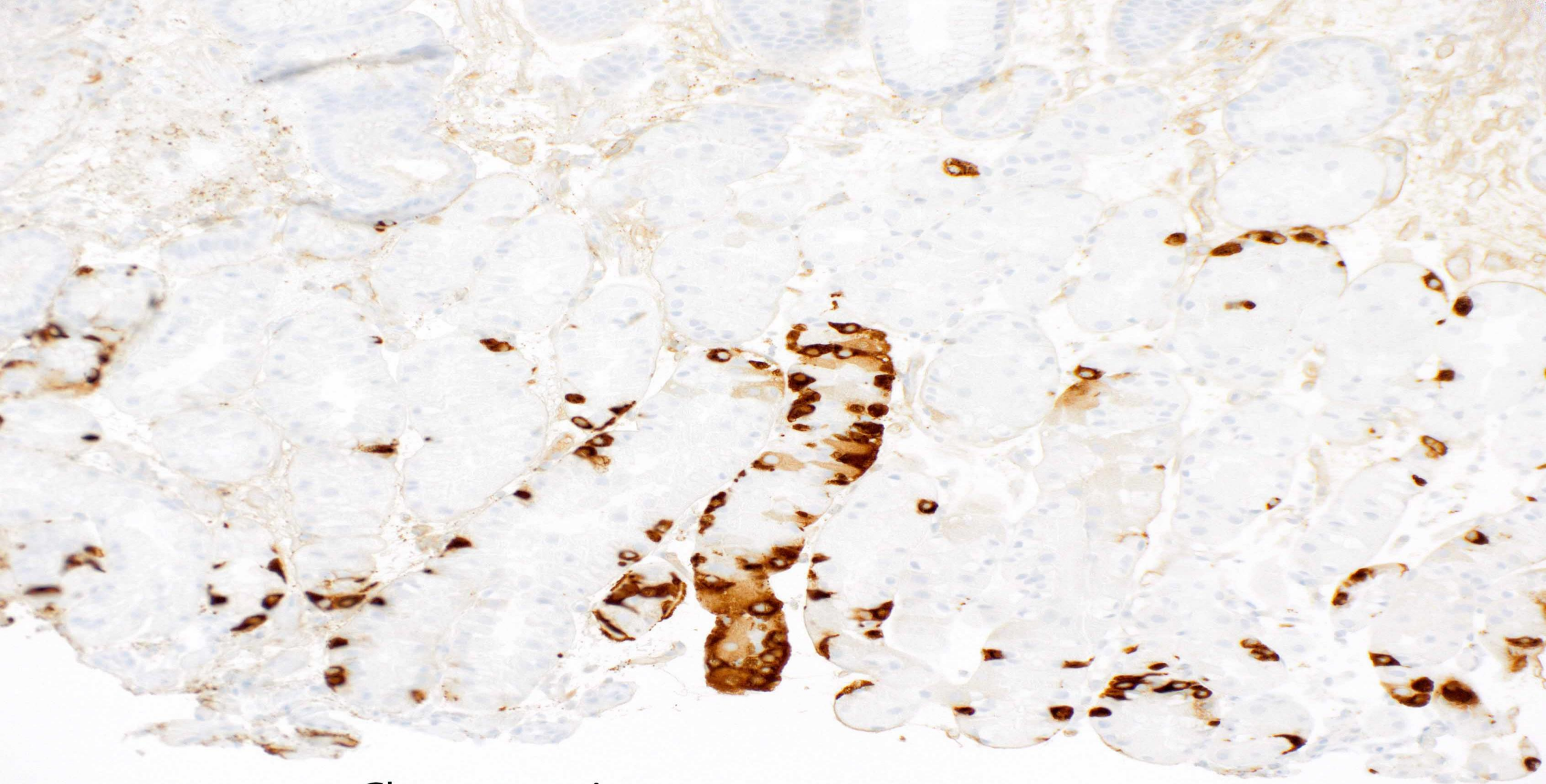

Chromogranin

Stomach biopsies from a 58 year old woman

- She does not take proton pump inhibitors
- She does not have parietal cell antibodies
- She does not have intrinsic factor antibodies.
- Her gastrin in 560 pg/nl (normal is about 50 pg/nl)

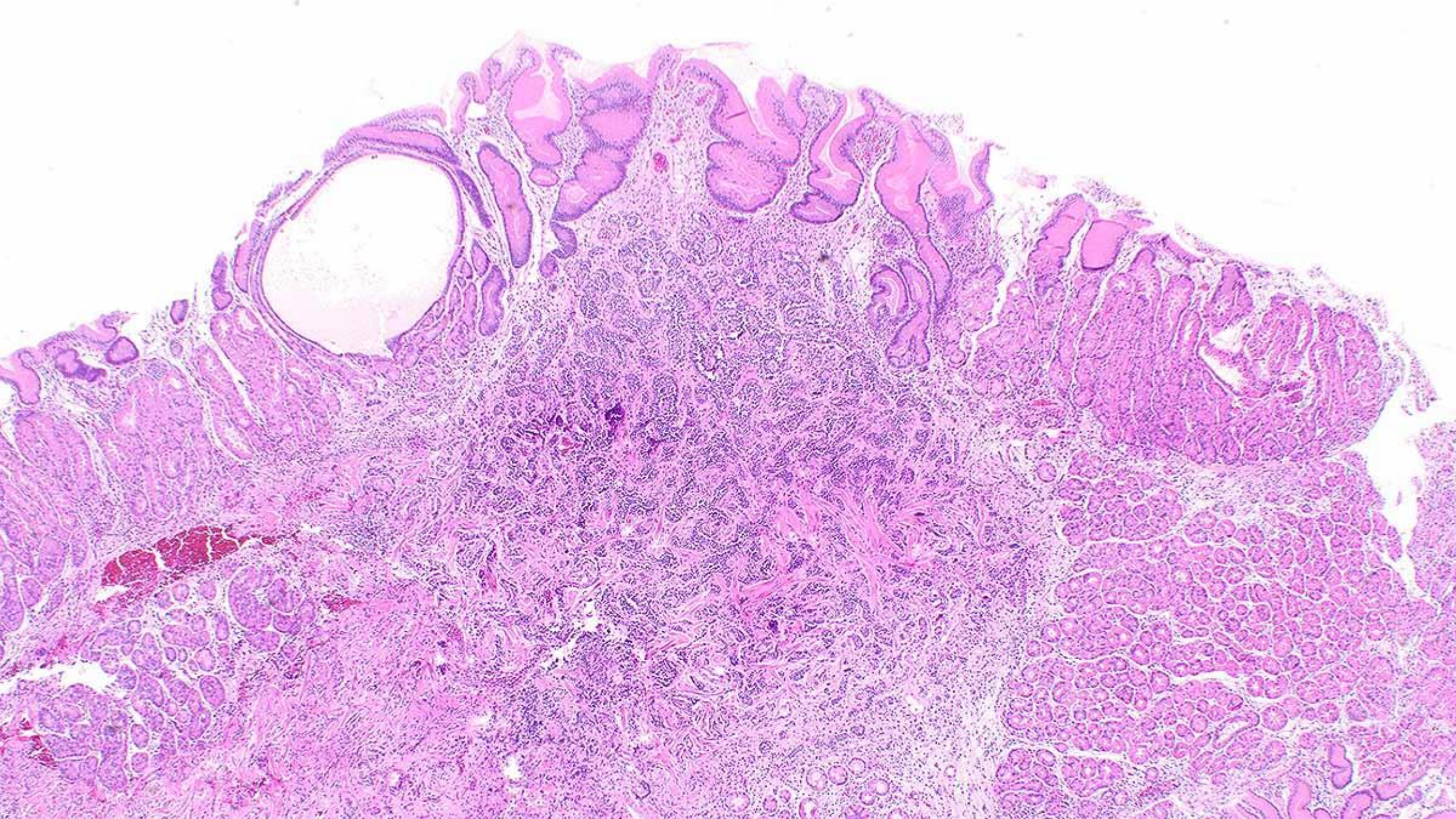

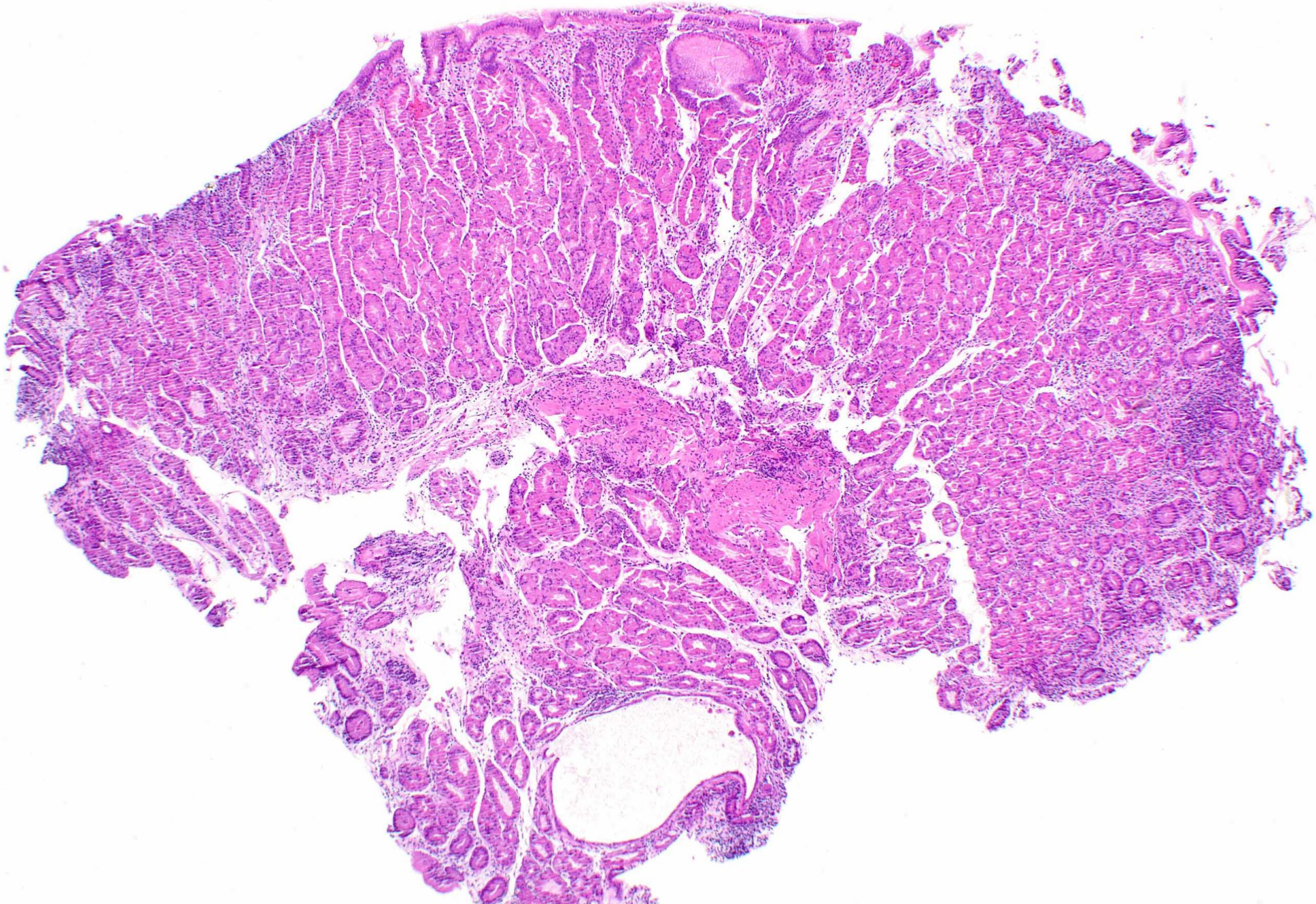

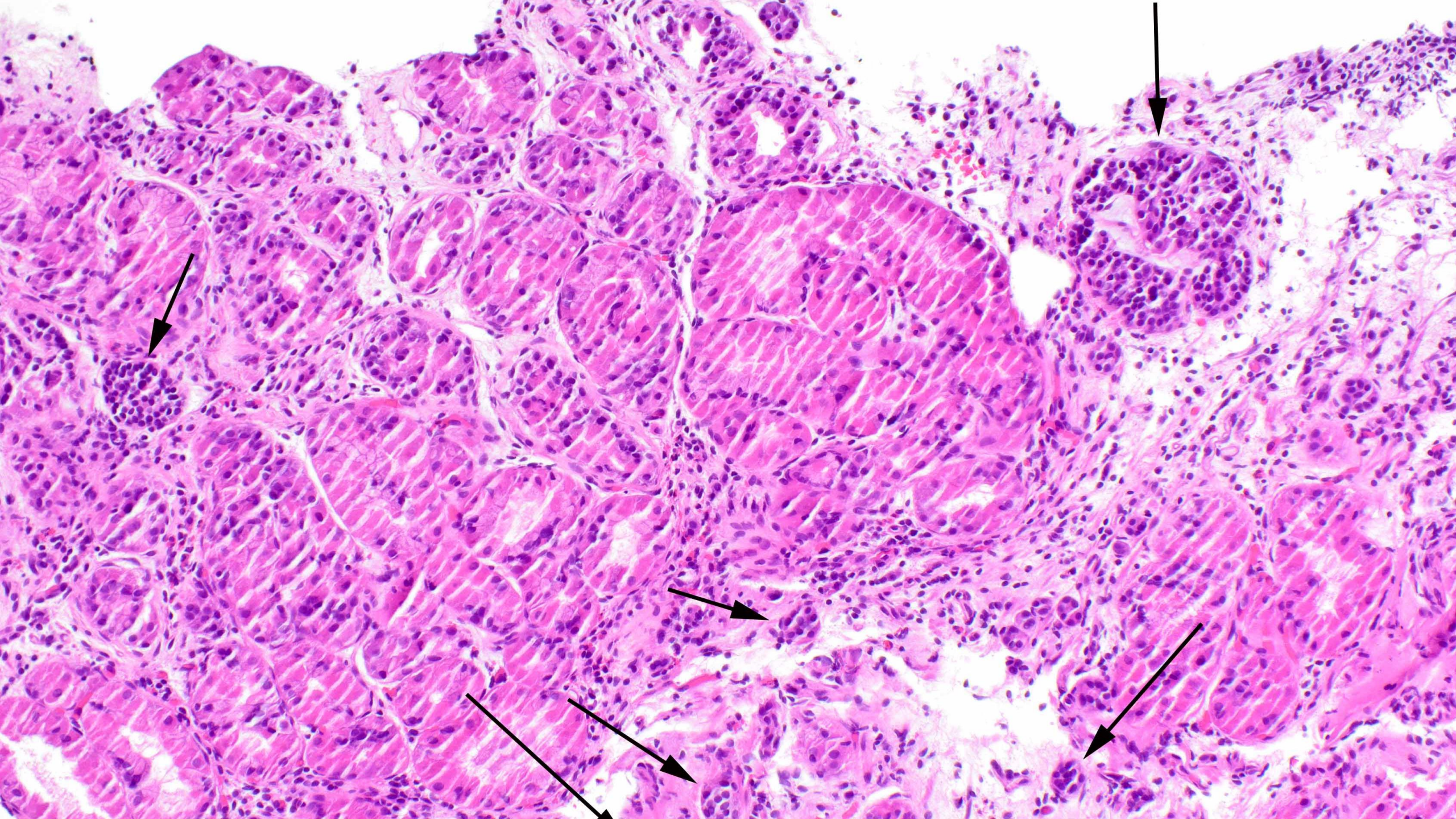

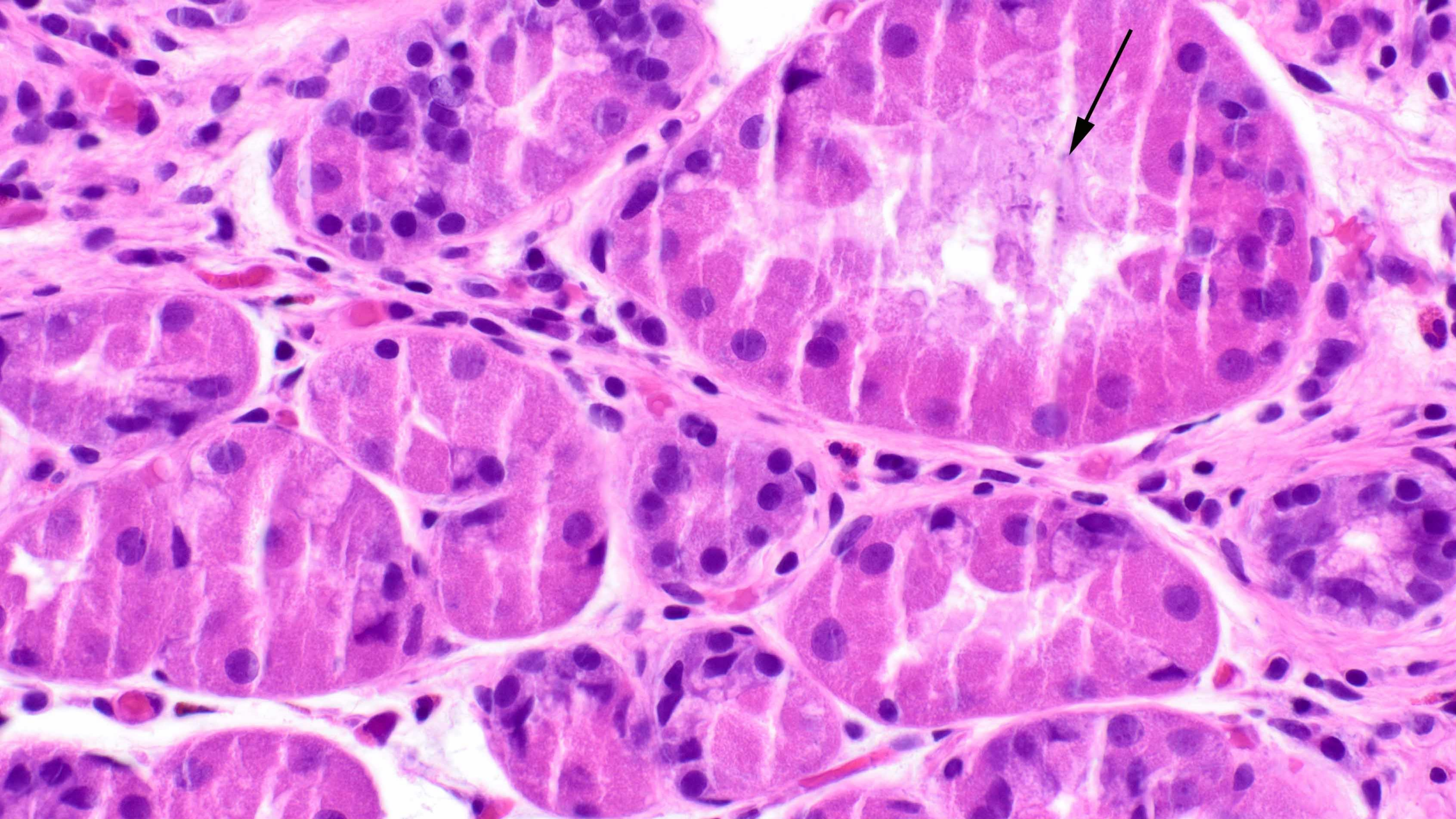

Stomach biopsies from a 58 year old woman

- She does not take proton pump inhibitors
- She does not have parietal cell antibodies
- She does not have intrinsic factor antibodies.
- Her gastric in 560 pg/nl (normal is about 50 pg/nl)

- PROBABLY a Type 4 carcinoid due to an intrinsic defect in the proton pump – no proof as of this moment (I tried to make the colleagues test her - https://www.fulgentgenetics.com/ATP4A

Gastric Neuroendocrine (Carcinoid) Tumors (NETs)

Gastric NET type	Expected gastrin levels (pg/nl)	Other findings
Type 1	Median 884 (range 200-3084) Reference 5	Autoimmune gastritis; parietal cell loss
Type 2	>1,000 with pH < 2	Gastrinoma of pancreas or duodenum
Type 3 (sporadic)	Normal (about 50)	Normal background oxyntic mucosa
Long term proton pump inhibitor-associated	About 100 Reference 1	Long term use of proton pump inhibitors
Type 4	189-3503 Reference 2	Germline *ATP4A* mutations; early data indicate autosomal recessive inheritance

1. Lundell L, Vieth M, Gibson F, Nagy P, Kahrilas PJ. Systematic review: the effects of long-term proton pump inhibitor use on serum gastrin levels and gastric histology. Aliment Pharmacol Ther. 2015 Sep;42(6):649-63. PMID: 26177572.
2. Calvete O, Reyes J, Zuñiga S, Paumard-Hernández B, Fernández V, Bujanda L, Rodriguez-Pinilla MS, Palacios J, Heine-Suñer D, Banka S, Newman WG, Cañamero M, Pritchard DM, Benítez J. Exome sequencing identifies ATP4A gene as responsible of an atypical familial type I gastric neuroendocrine tumour. Hum Mol Genet. 2015 May 15;24(10):2914-22. PMID: 25678551.
3. Trinh VQ, Shi C, Ma C. Gastric neuroendocrine tumours from long-term proton pump inhibitor users are indolent tumours with good prognosis. Histopathology. 2020 Dec;77(6):865-876. PMID: 32702178.
4. Rais R, Trikalinos NA, Liu J, Chatterjee D. Enterochromaffin-like Cell Hyperplasia-Associated Gastric Neuroendocrine Tumors May Arise in the Setting of Proton Pump Inhibitor Use. Arch Pathol Lab Med. 2022 Mar 1;146(3):366-371. PMID: 34283890.
5. Poveda JC, Chahar S, Garcia-Buitrago MT, Montgomery EA, McDonald OG. The Morphologic Spectrum of Gastric Type 1 Enterochromaffin-Like Cell Neuroendocrine Tumors. Mod Pathol. 2023 Apr;36(4):100098 PMID: 36913909; PMCID: PMC10121960.

Does anyone enjoy counting Ki-67s?

- No, you do not; it’s totally boring.
- Machines count lymphocytes – but so do humans.
- Machines are more patient than humans.
- AI is supposed to solve it, but who has that?
- There IS a poor man’s trick (and some machines seem to use it in their algorithms).

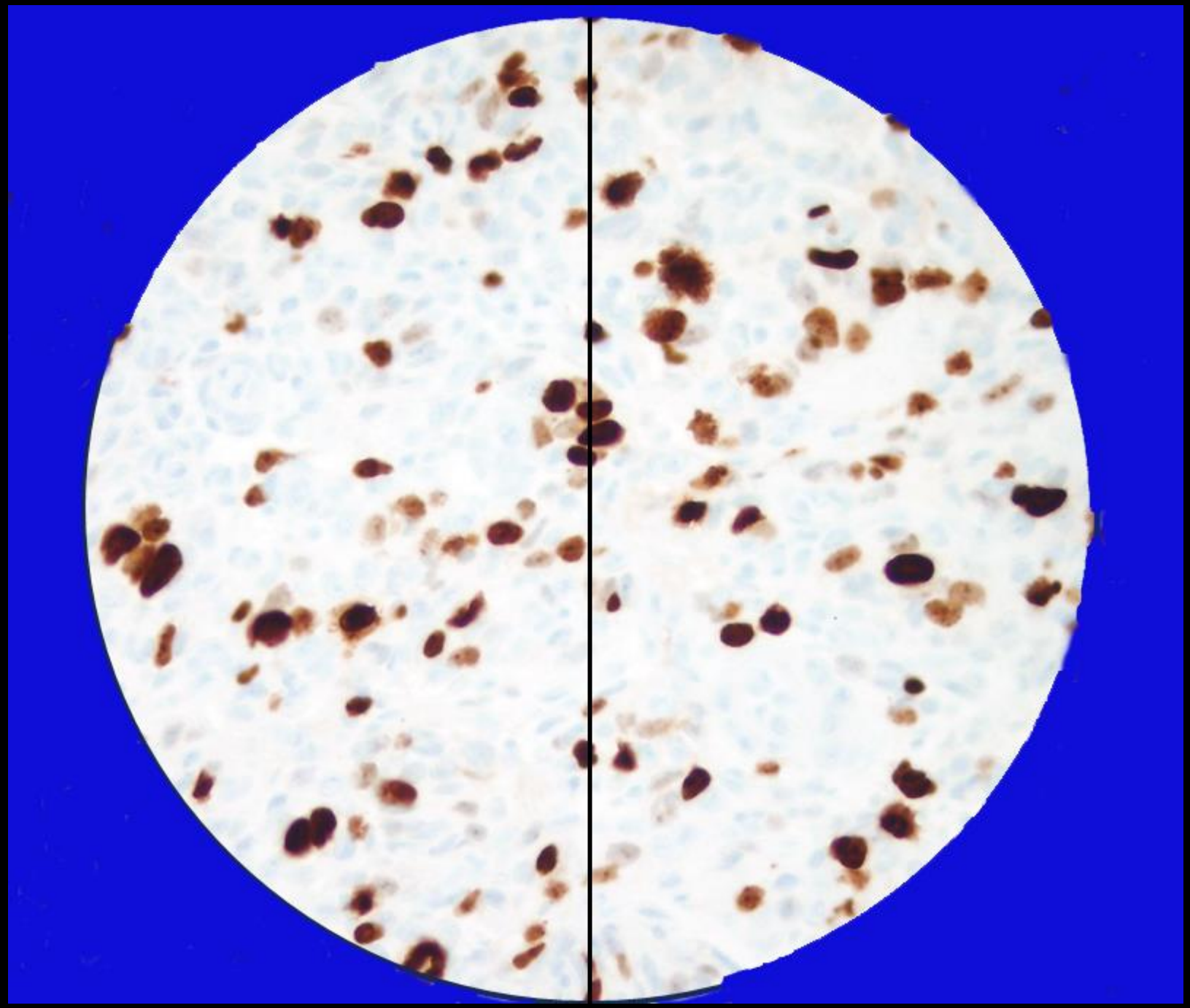

Estimation of proliferation index using the formula for a circle.

- All the nuclei are counted in a straight line in the middle of a circle (the microscopic field) from one end to the other; this becomes the “diameter” of the circle.
- Divide that number by 2 to get the “radius” (r).
- Use the formula for the area of a circle ($\pi \times r^2$) and calculate that value, which is the number of all cells in the circle.
- Staying in the same field, count the number of positive cells. Then calculate the number of positive cells divided by the number for the area of the circle to provide an estimate of the proliferation index.
- In this example, there are 18 nuclei in the line, so the “radius” is 9 cells. The total number of nuclei is thus 3.14 x (9x9) = 254.35. There are 90 positive cells, so the index is 35%.
- Society guidelines suggest counting 500 cells, so a “diameter” of 26 or more nuclei (and thus a “radius” of 13 cells) yields a large enough denominator of cells.

Small intestine

Small intestine

- Nearly every crypt has abundant Paneth cells. This differs from the colon and finding numerous Paneth cells in crypt bases can be a clue that a damaged sample is from the small intestine rather than the colorectum

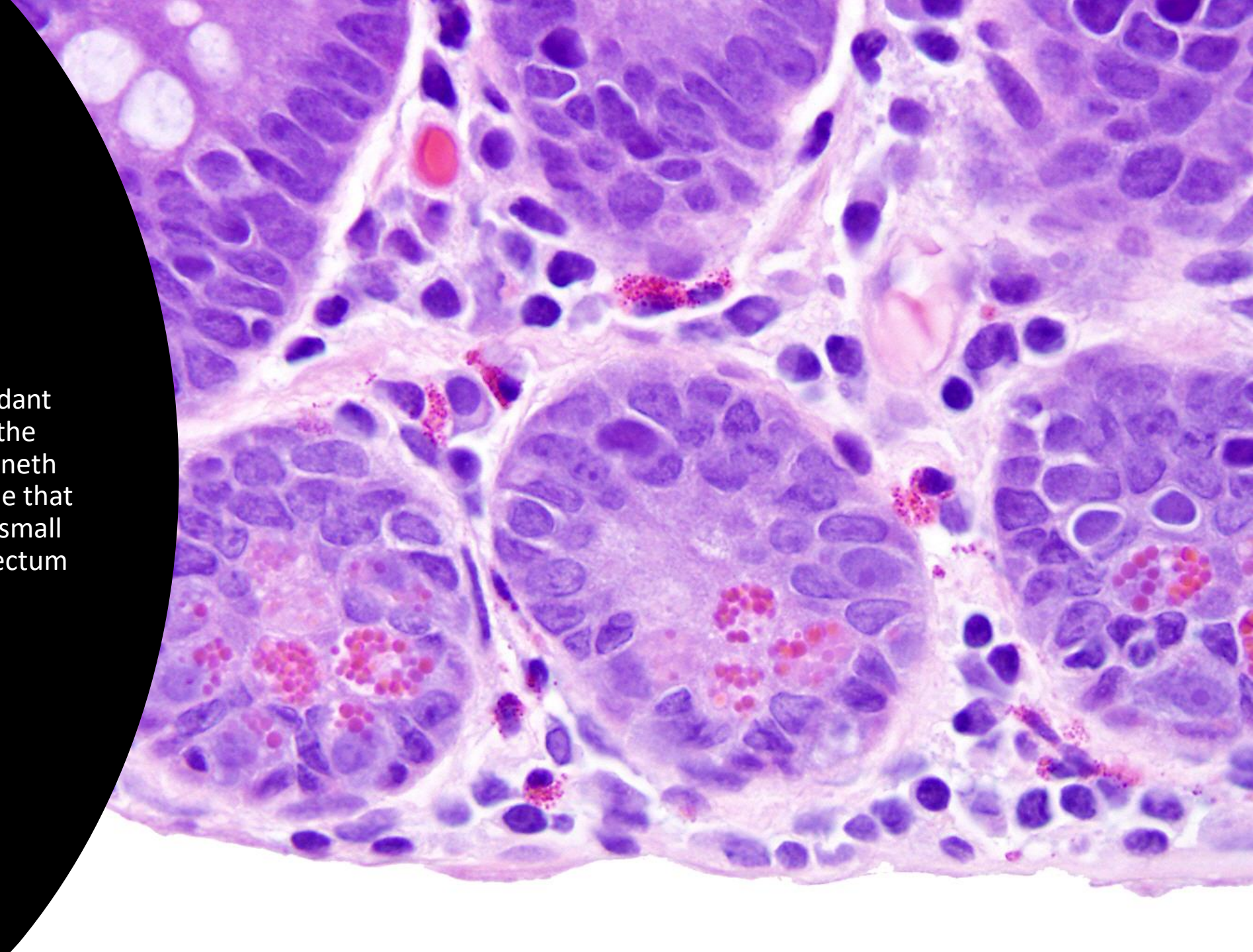

- There are delicate strands of smooth muscle in the core of each villus. This smooth muscle, which helps villi move to increase nutrient absorption, can be mistaken for an abnormal infiltrate (such as Whipple's or Gaucher's disease) in tangentially embedded villi

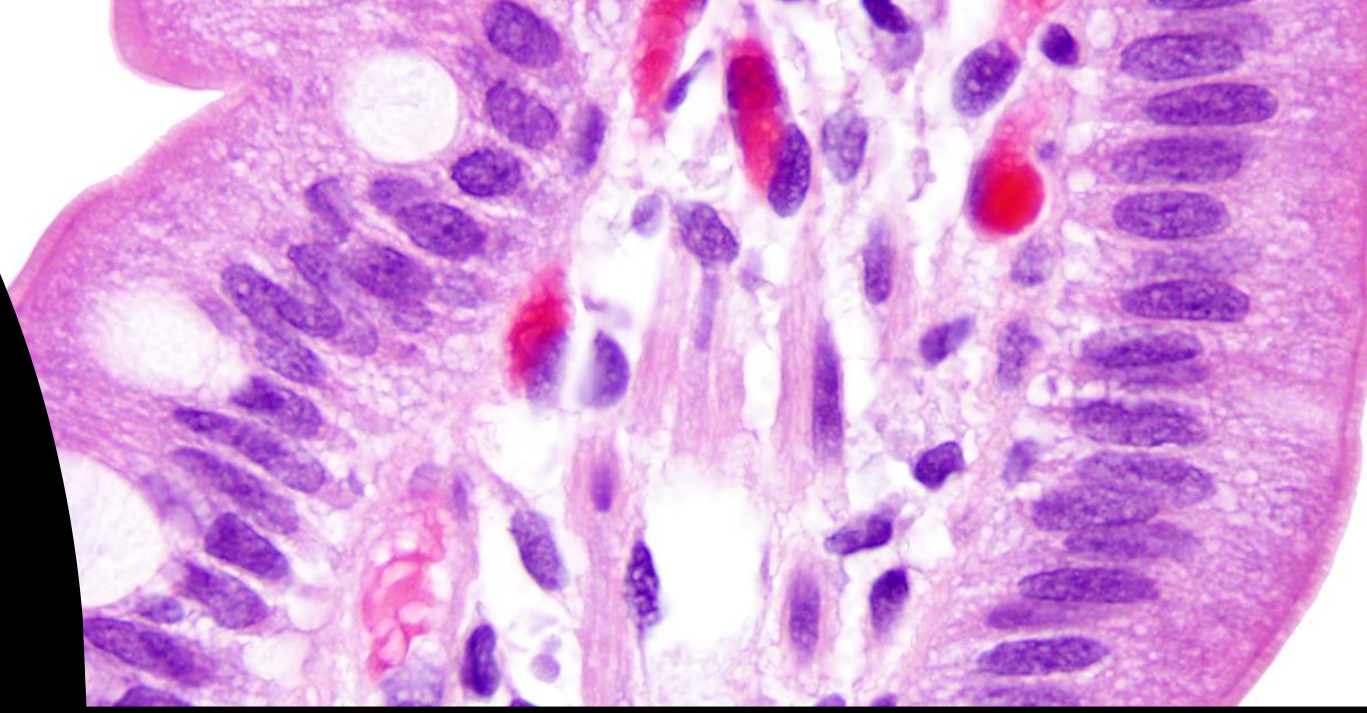

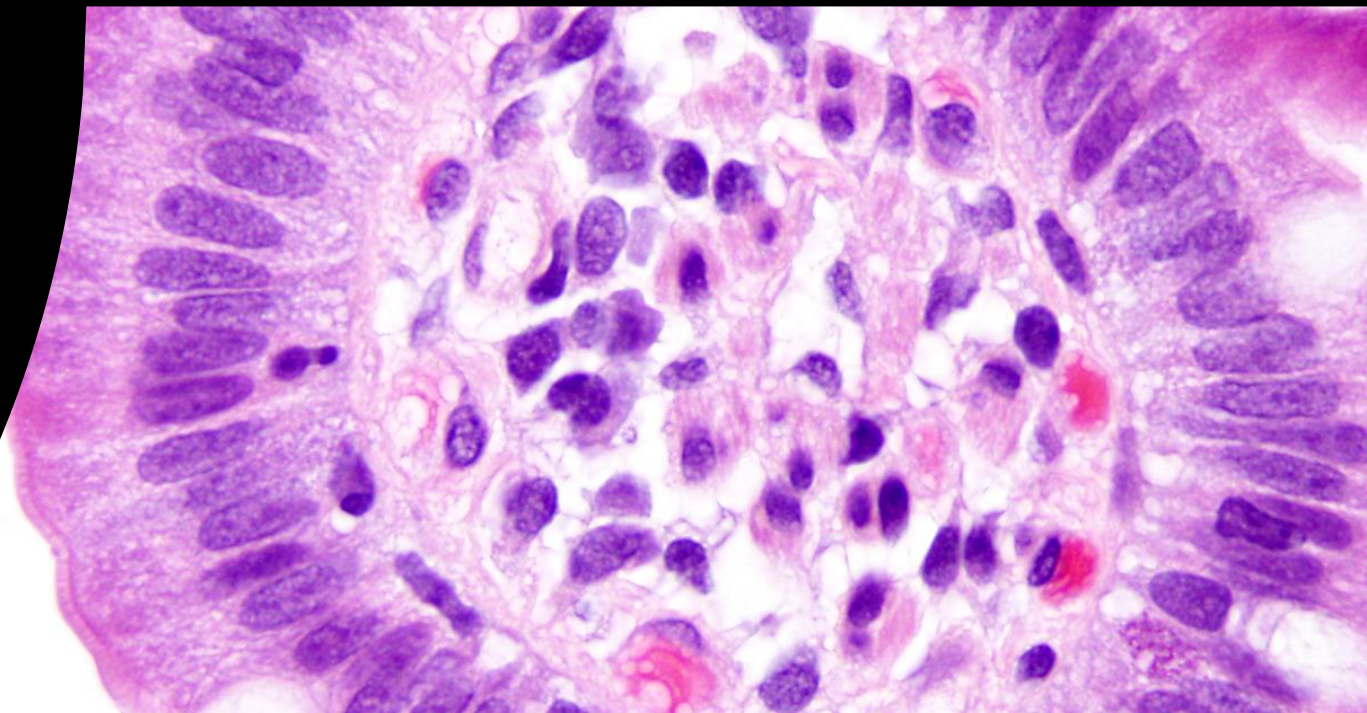

- Some duodenal samples contain crushed Brunner glands that can be mistaken for mesenchymal neoplasms and Whipple's disease. Brunner glands are strongly PAS –reactive, which can add to the confusion

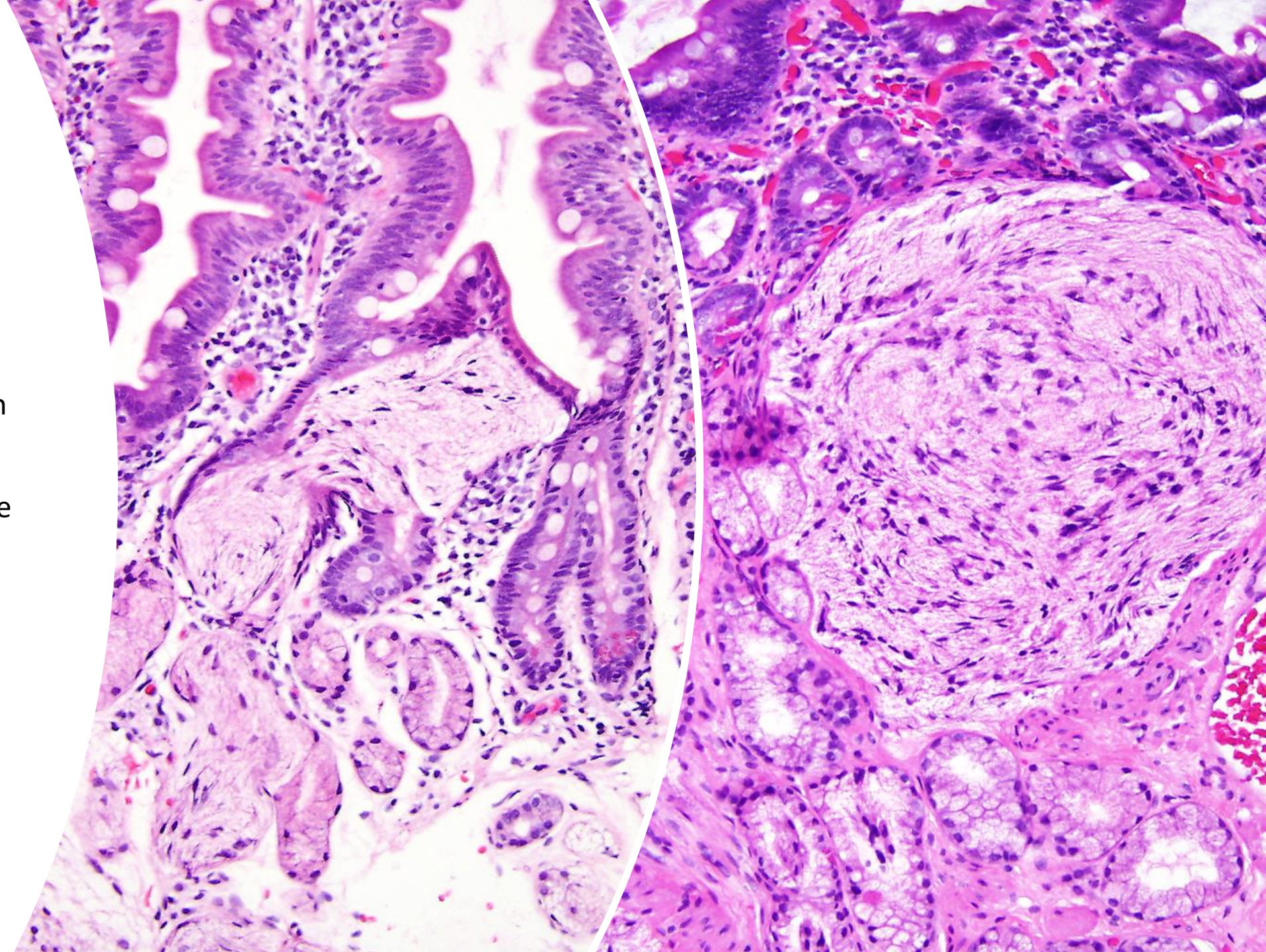

Whipple's disease

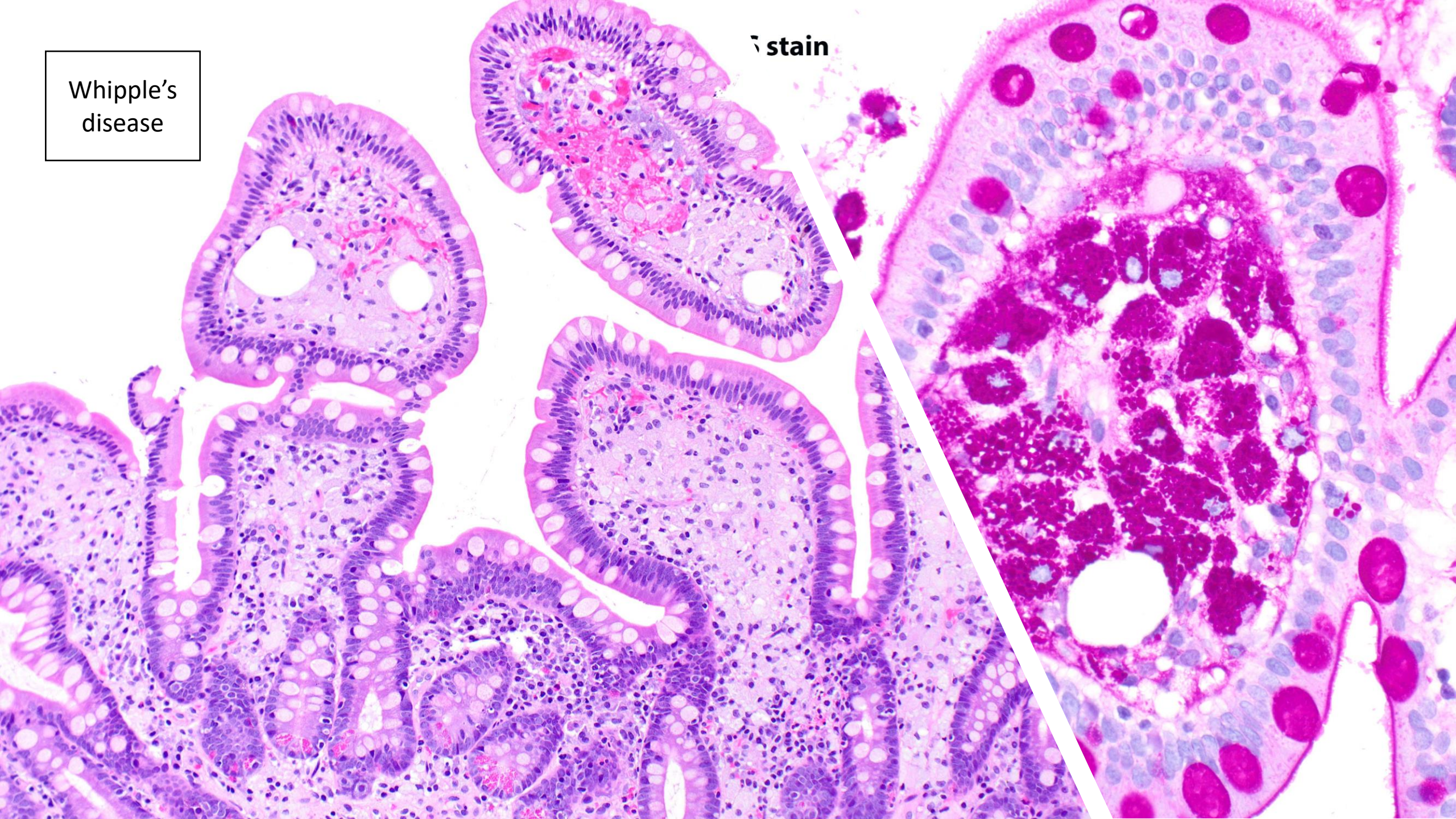

Mycobacterium avium complex

PAS/AB stain

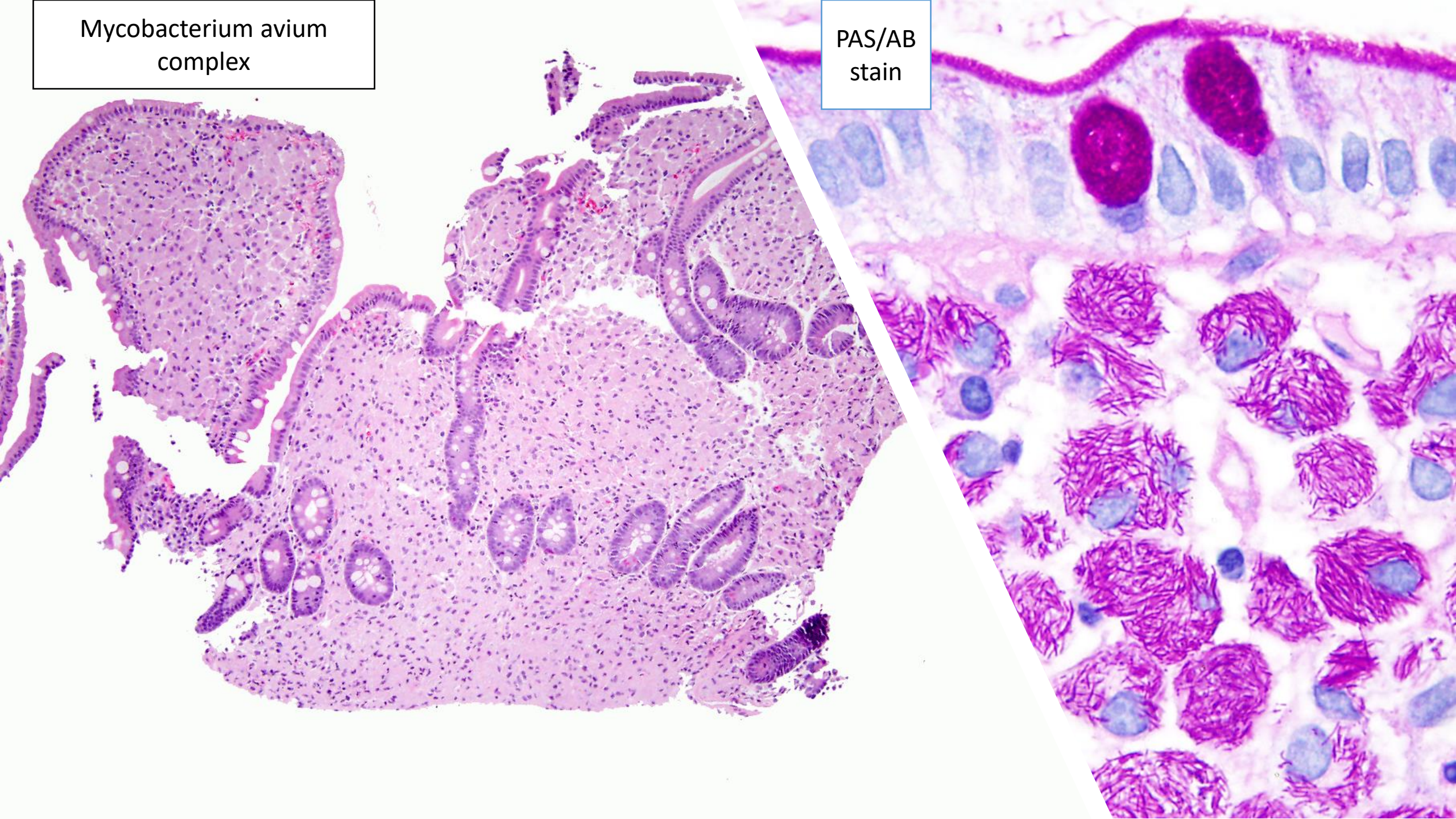

- Crushed samples frequently lose their epithelium (akin to squeezing sebum from the pores of nasal skin), which should not be mistaken for ischemia or lymphangioma (below)

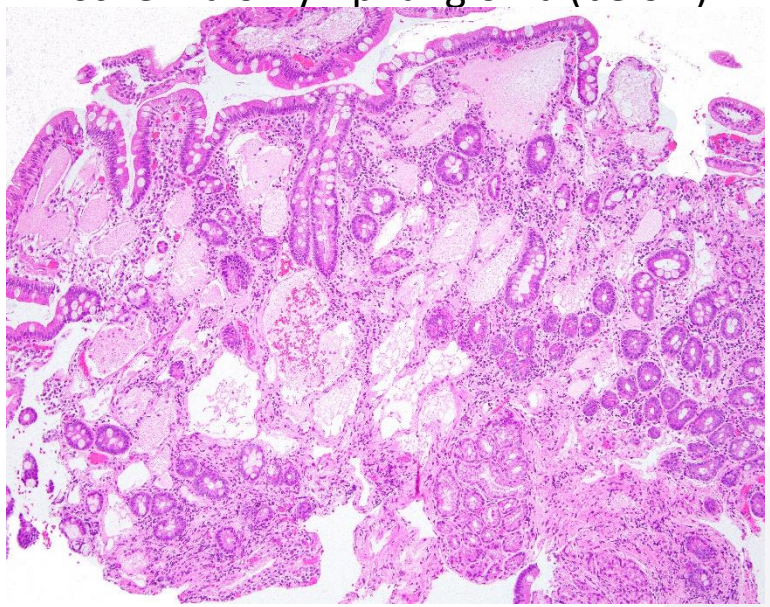

Titanium in the ileum

- The ileum often appears traumatized at scanning magnification because of the fragile nature of the prominent lymphoid aggregates (Peyer patches). Histiocytes in the ileal lymphoid tissue often contain black material that corresponds to titanium found in toothpaste and various foodstuffs

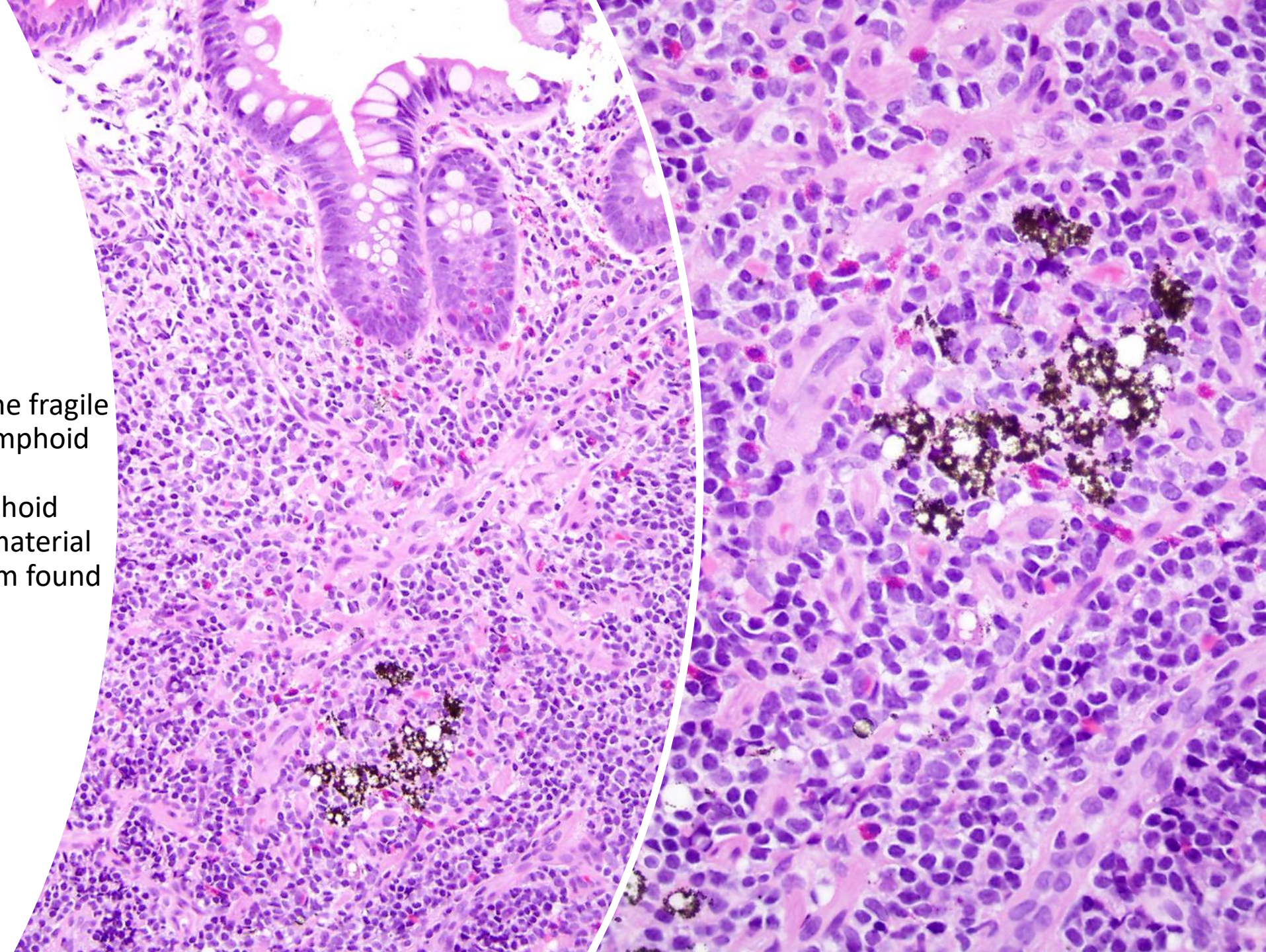

Titanium makes food white

Powell JJ, Ainley CC, Harvey RS, Mason IM, Kendall MD, Sankey EA, et al. Characterisation of inorganic microparticles in pigment cells of human gut associated lymphoid tissue. Gut. 1996;38(3):390–5

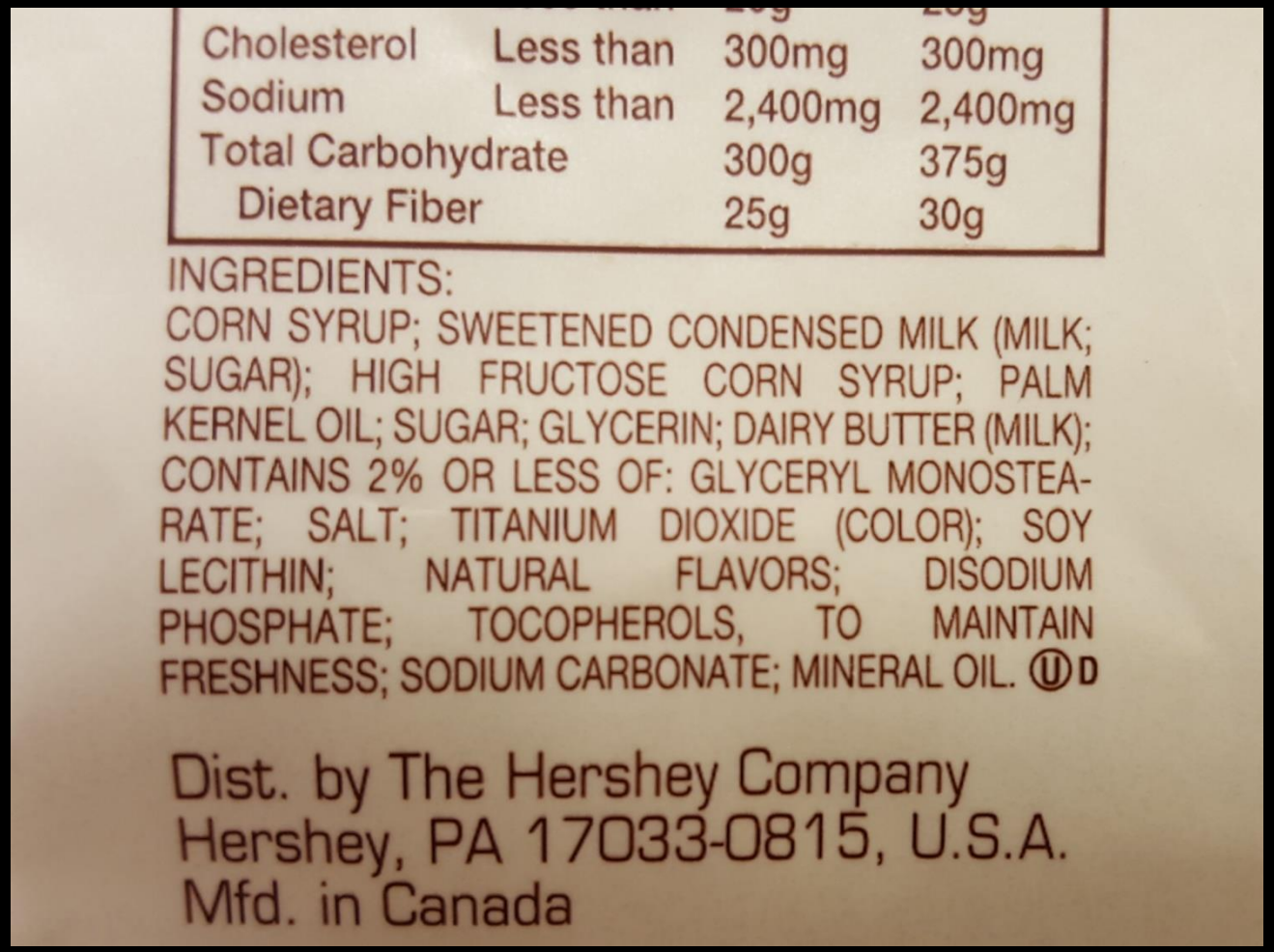

Cholesterol	Less than	300mg	300mg
Sodium	Less than	2,400mg	2,400mg
Total Carbohydrate		300g	375g
Dietary Fiber		25g	30g

INGREDIENTS:
CORN SYRUP; SWEETENED CONDENSED MILK (MILK; SUGAR); HIGH FRUCTOSE CORN SYRUP; PALM KERNEL OIL; SUGAR; GLYCERIN; DAIRY BUTTER (MILK); CONTAINS 2% OR LESS OF: GLYCERYL MONOSTEARATE; SALT; TITANIUM DIOXIDE (COLOR); SOY LECITHIN; NATURAL FLAVORS; DISODIUM PHOSPHATE; TOCOPHEROLS, TO MAINTAIN FRESHNESS; SODIUM CARBONATE; MINERAL OIL. UD

Dist. by The Hershey Company
Hershey, PA 17033-0815, U.S.A.
Mfd. in Canada

Small Intestine

- Ideally, a biopsy should be taken, the forceps then removed through the endoscope channel and swished in formalin to dislodge the biopsy, swished in saline to clean away the formalin, and then re-introduced through the endoscope channel to take the next biopsy.
- As endoscopists are sometimes in a hurry, instead of taking biopsies from the duodenum one at a time and placing them individually into formalin, they take multiple “bites” sequentially, thus compressing the first biopsies into the back part of the forceps and damaging the tissue (“bite on bite” technique).

This results in an artifact that can be mistaken for injury

“Bite” 1

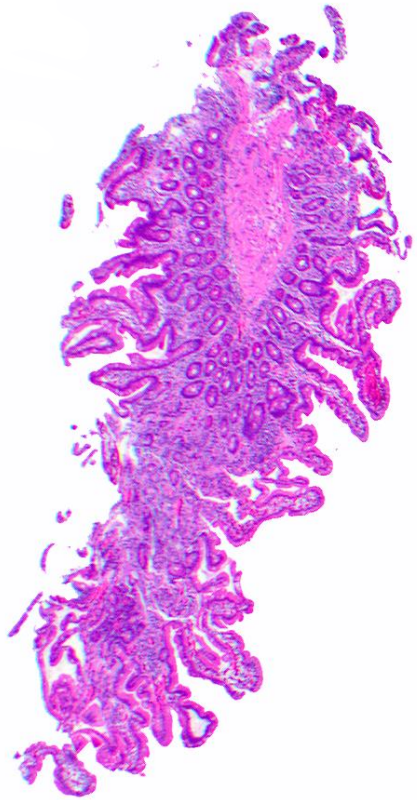

“Bite” 2

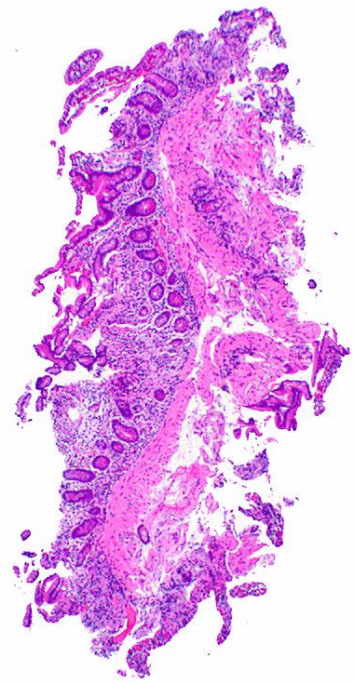

“Bite” 3

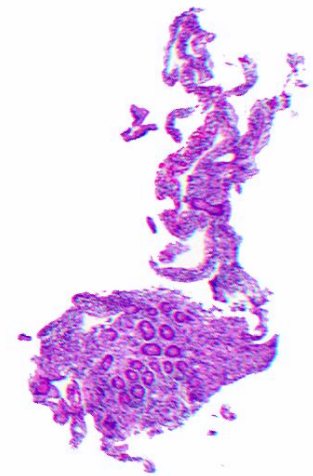

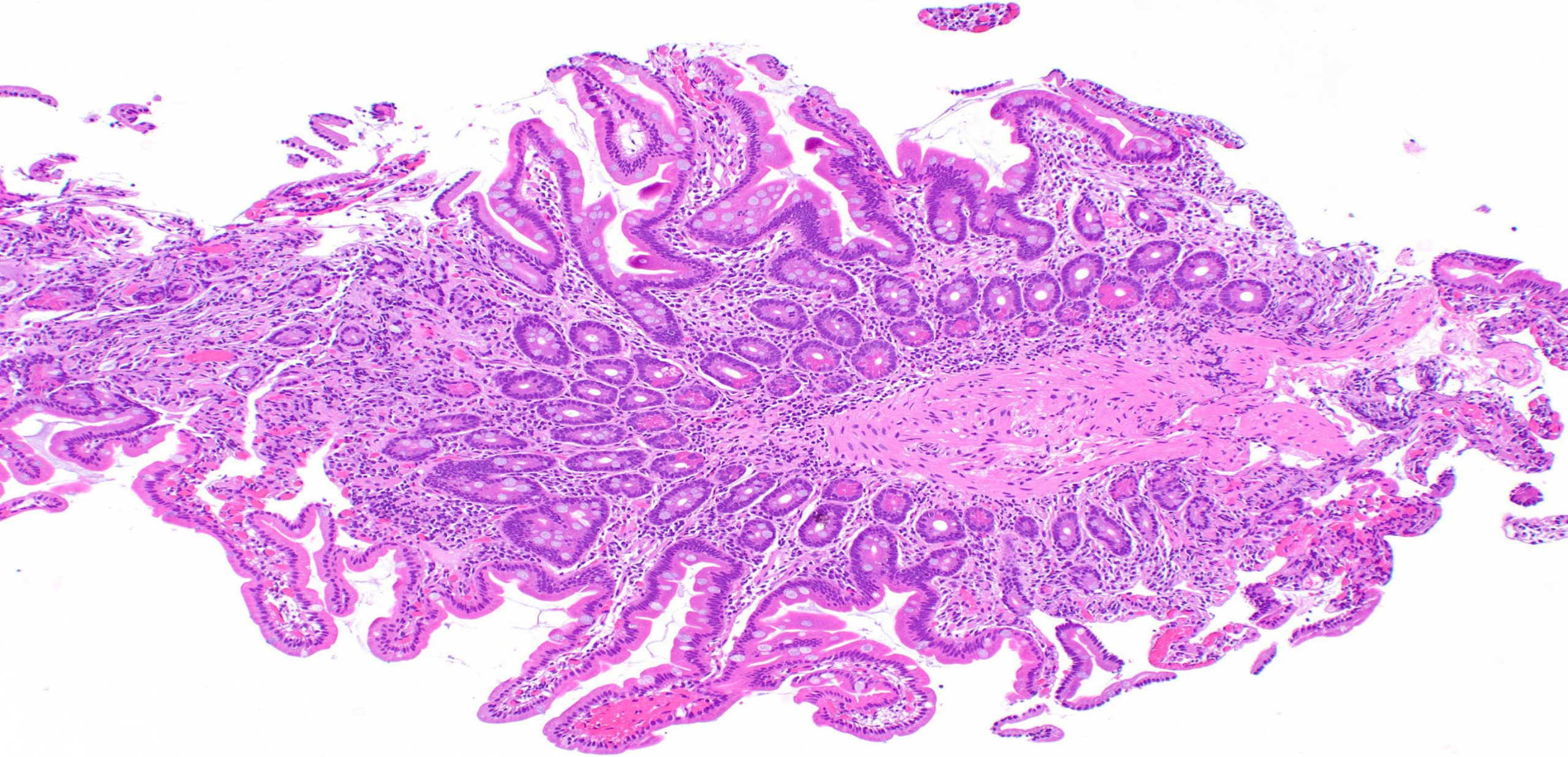

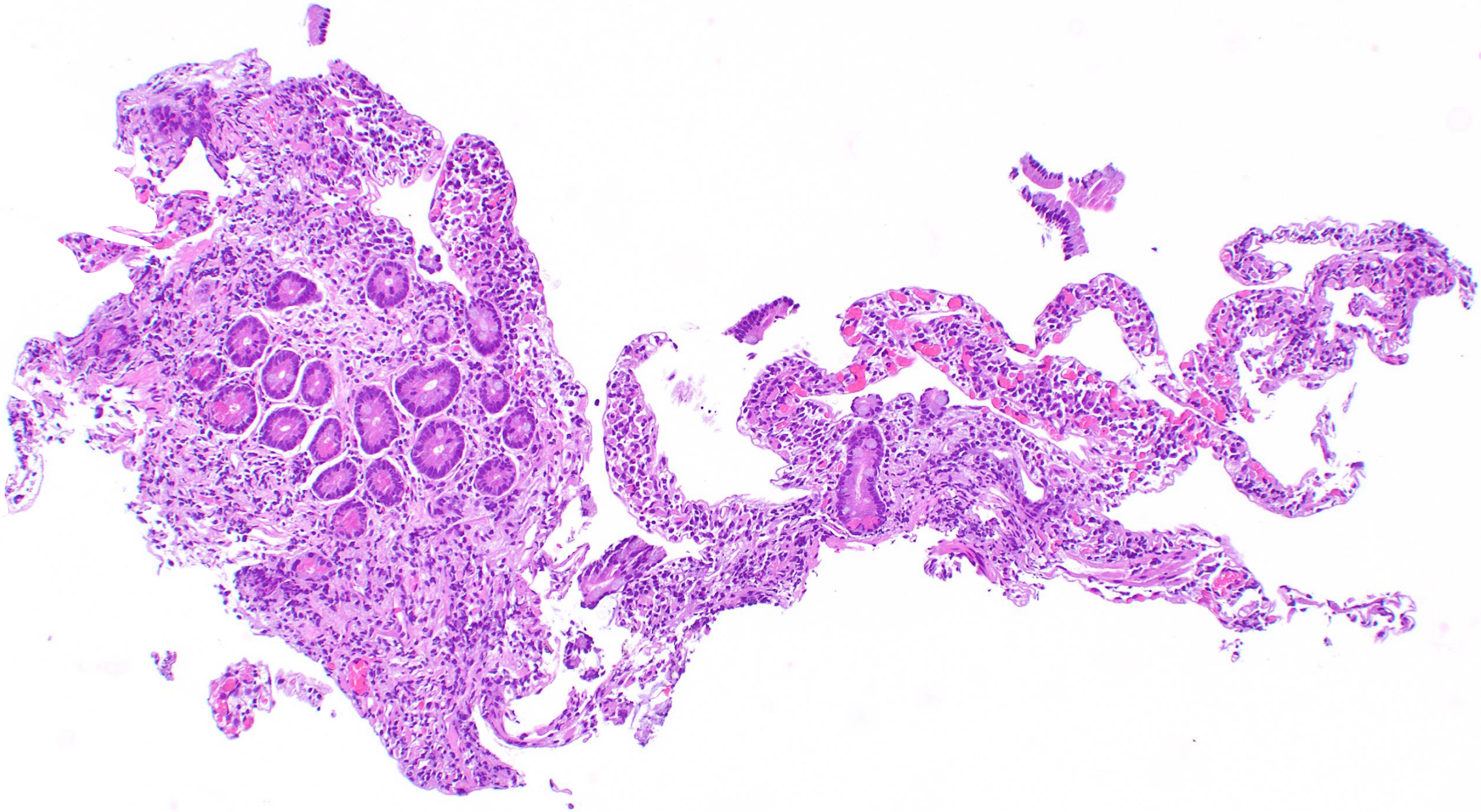

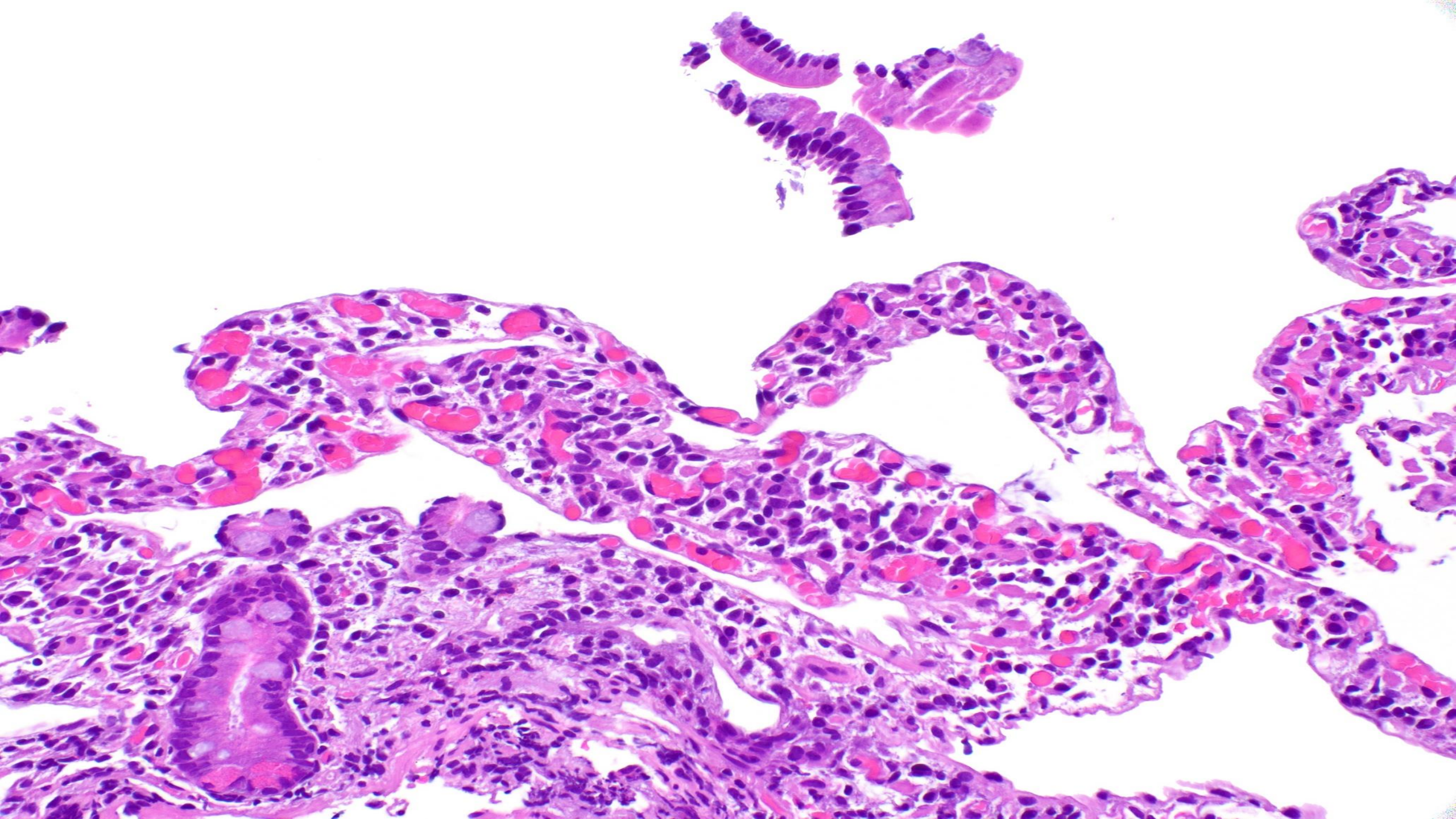

Yttrium spheres

- Y^{90}, a pure β emitter, is produced by neutron bombardment of yttrium-89 in a reactor. Y^{90} has a physical half-life of 64.2 hours ***(2.67 days)*** and decays to stable zirconium 90.
- The average/maximal penetration range of 2.5 mm and 11 mm, respectively, in tissue.
- In therapeutic use, in which the isotope decays to infinity, 94% of the radiation is delivered in 11 days.
- Y^{90} is the active moiety in a number of targeted radioimmunotherapies used in the treatment of a variety of solid organ and hematological malignancies.
- ***Injected through the hepatic artery but sometimes there is a little stray injection***

Yttrium-associated gastric injury
08:14:32
D.F:1
G:N
BI:A6

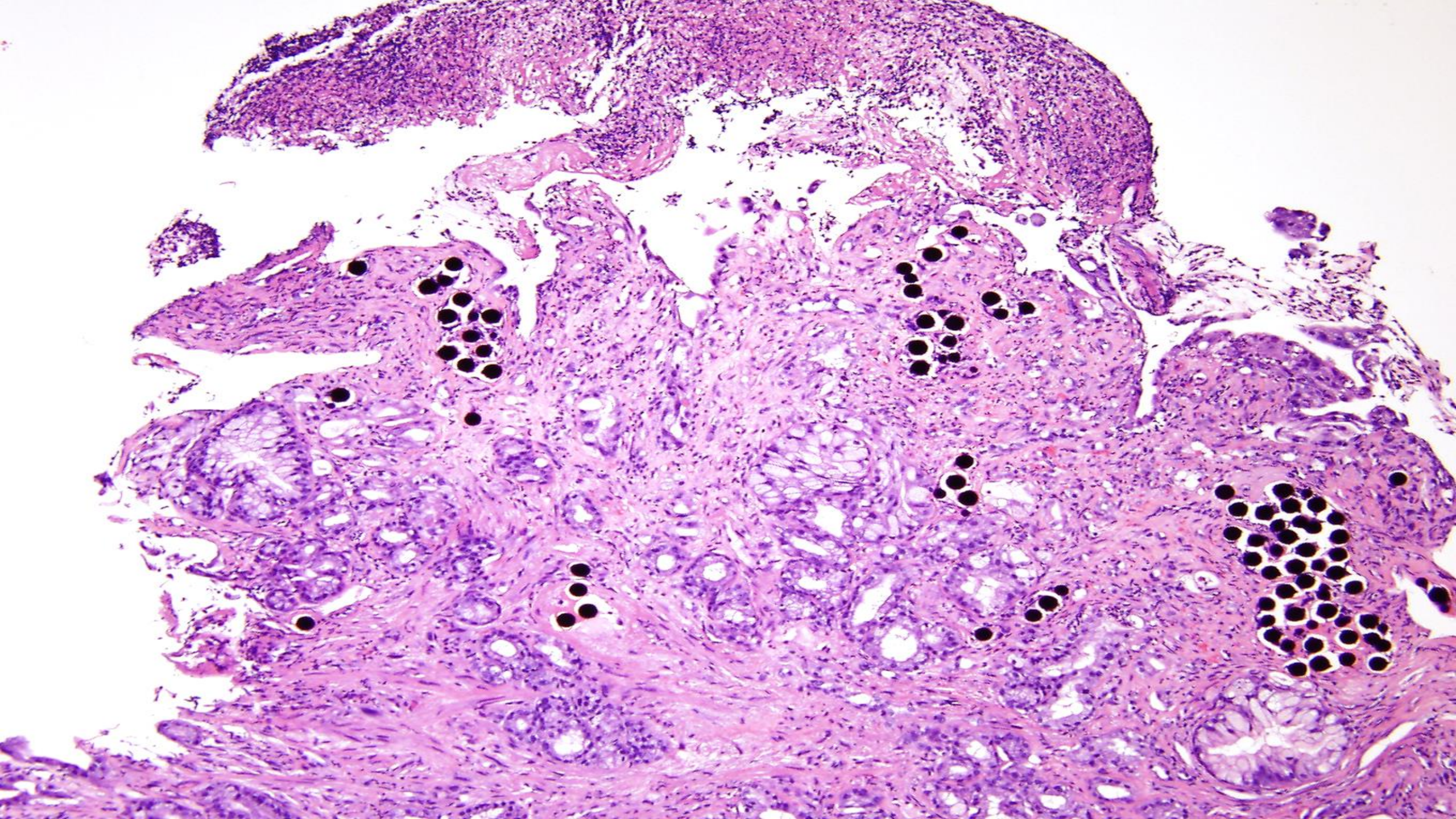

Yttrium – note the radiation change in nearby epithelium

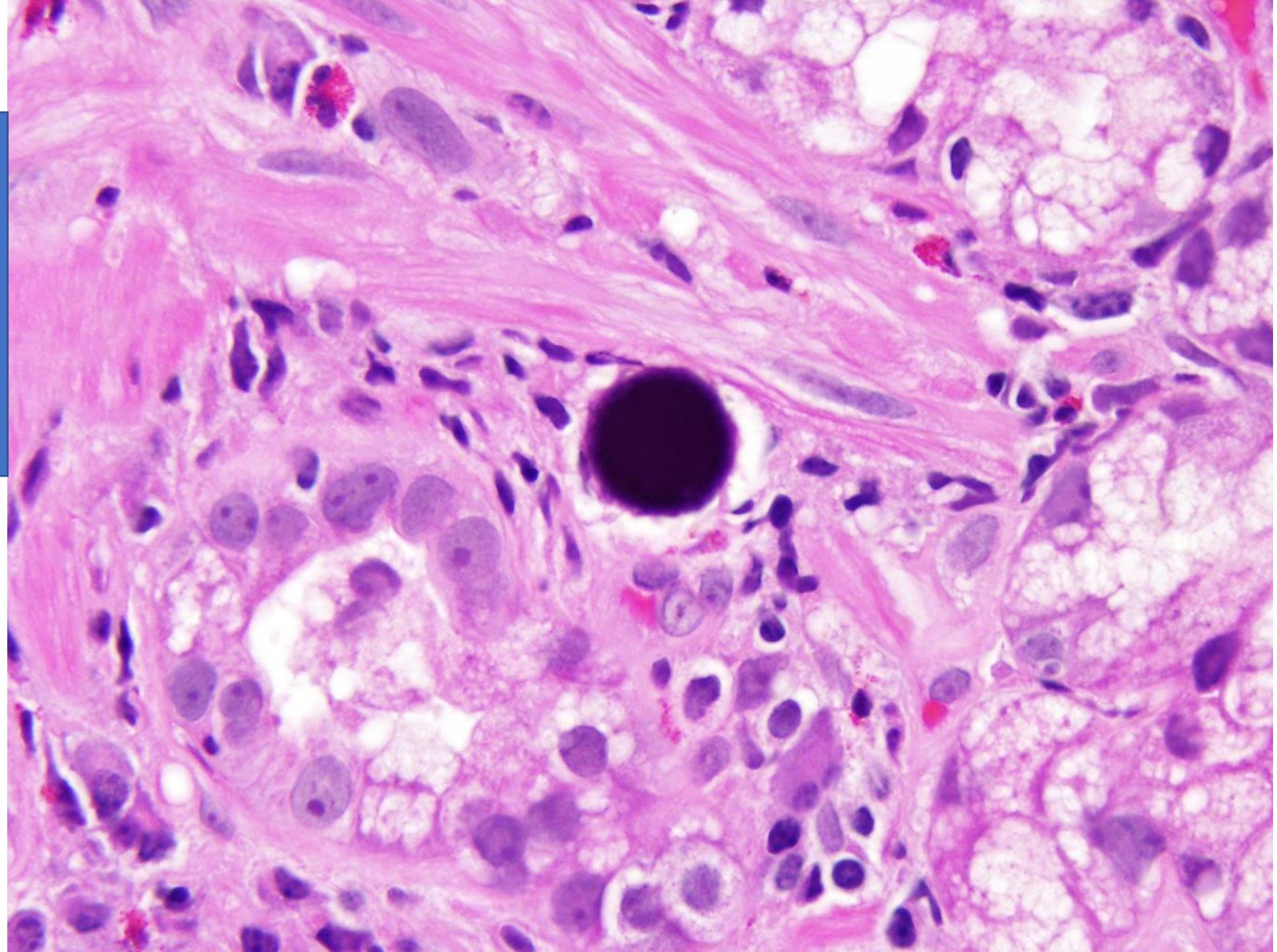

Gastric biopsy: Diagnosed as cancer

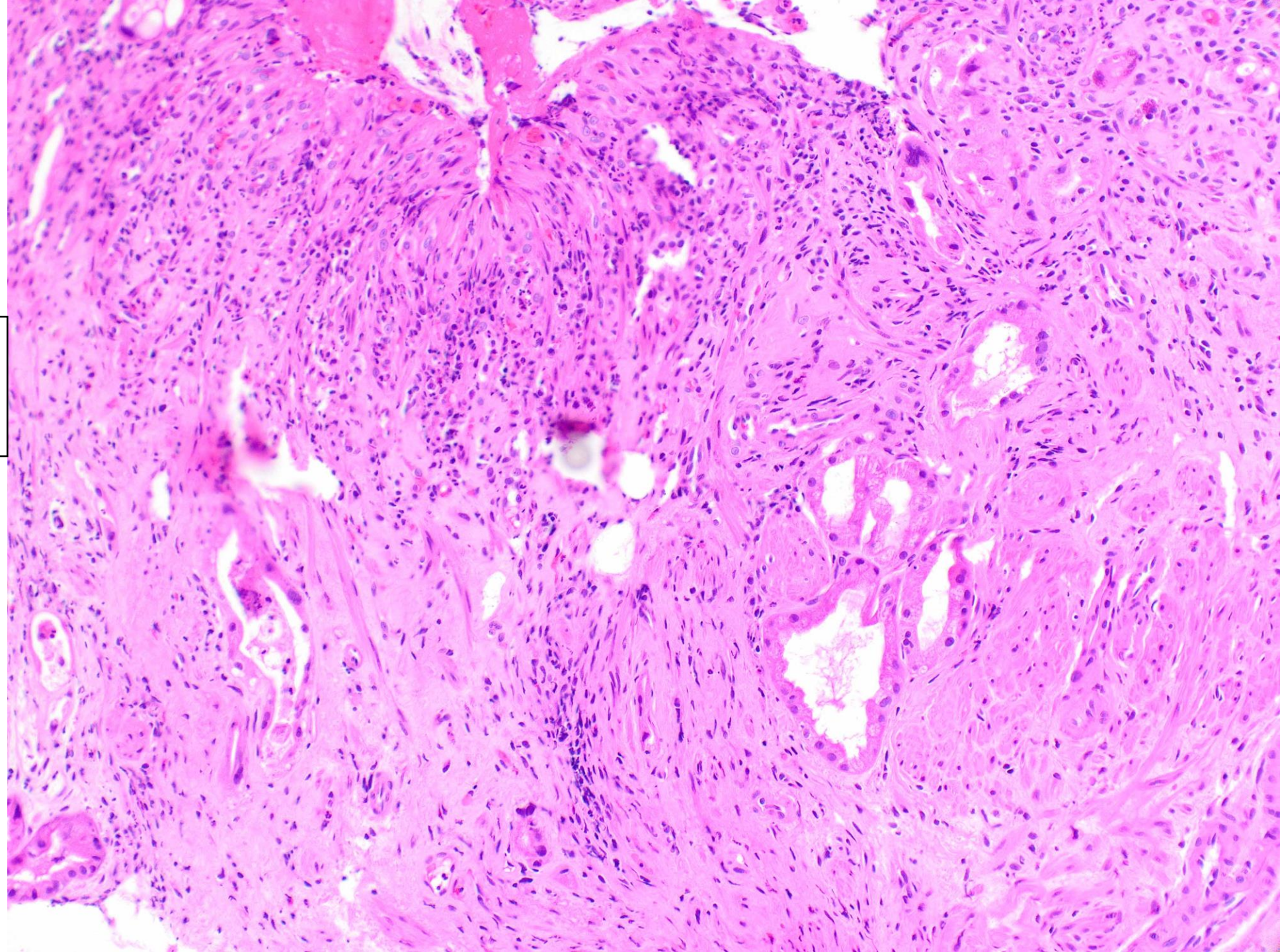

Diagnosed as cancer

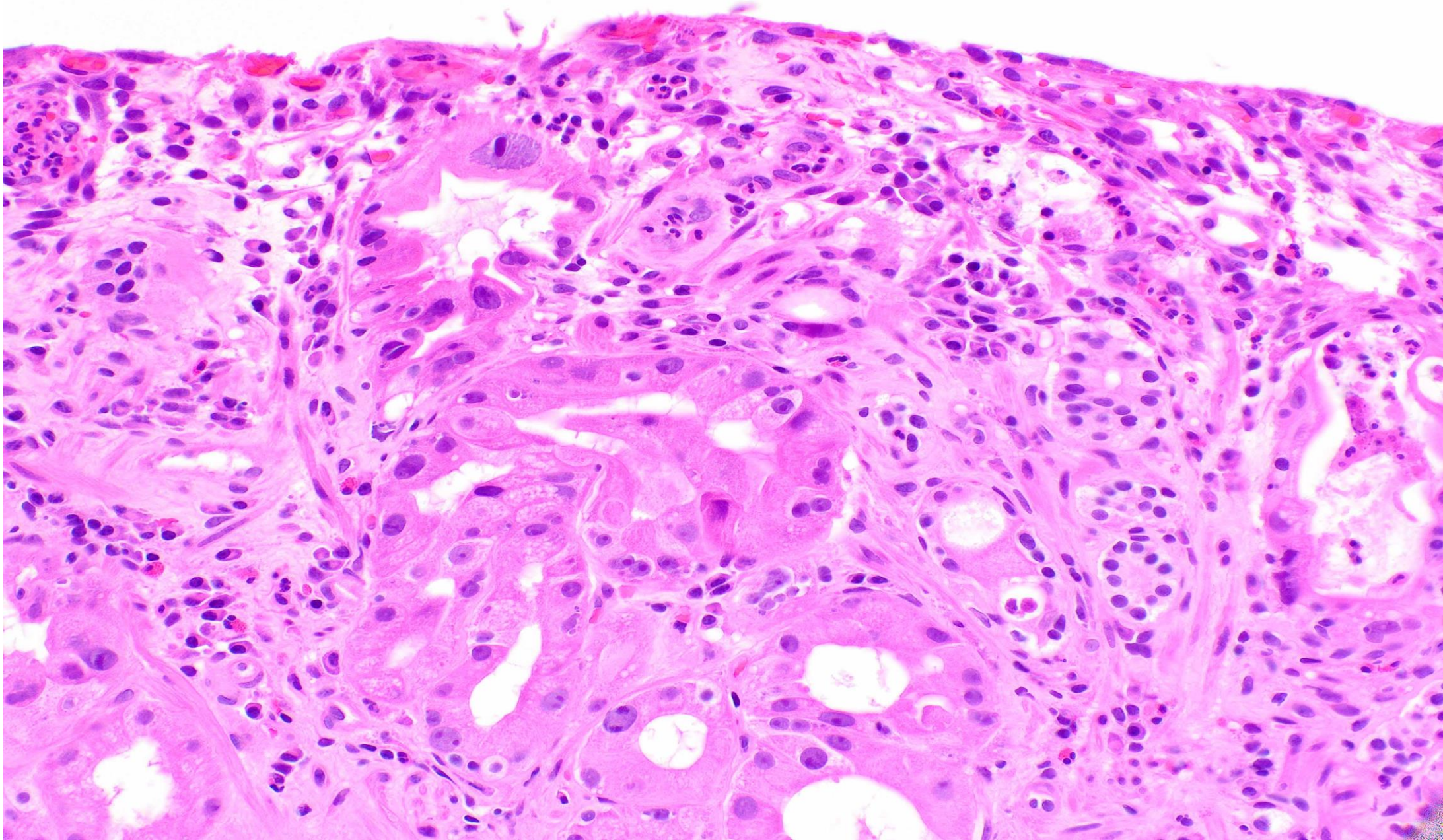

Radiation gastropathy associated with yttrium

Arnold CA, Pezhouh MK, Lam-Himlin D, Pittman ME, VandenBussche C, Voltaggio L. 90Y-TheraSpheres: The New Look of Yttrium-90. Am J Surg Pathol. 2019 May;43(5):688-694. PMID: 30720534.

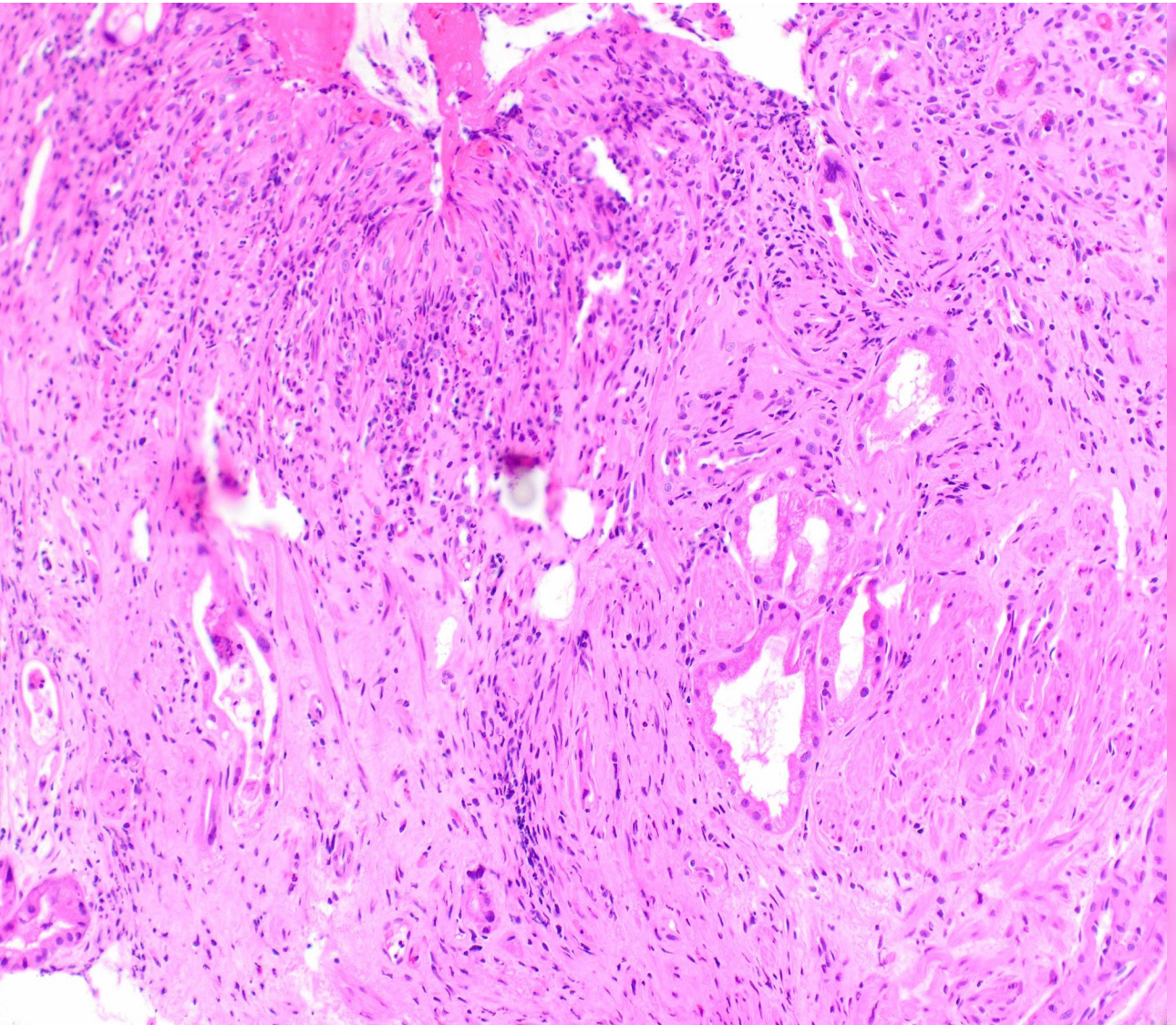

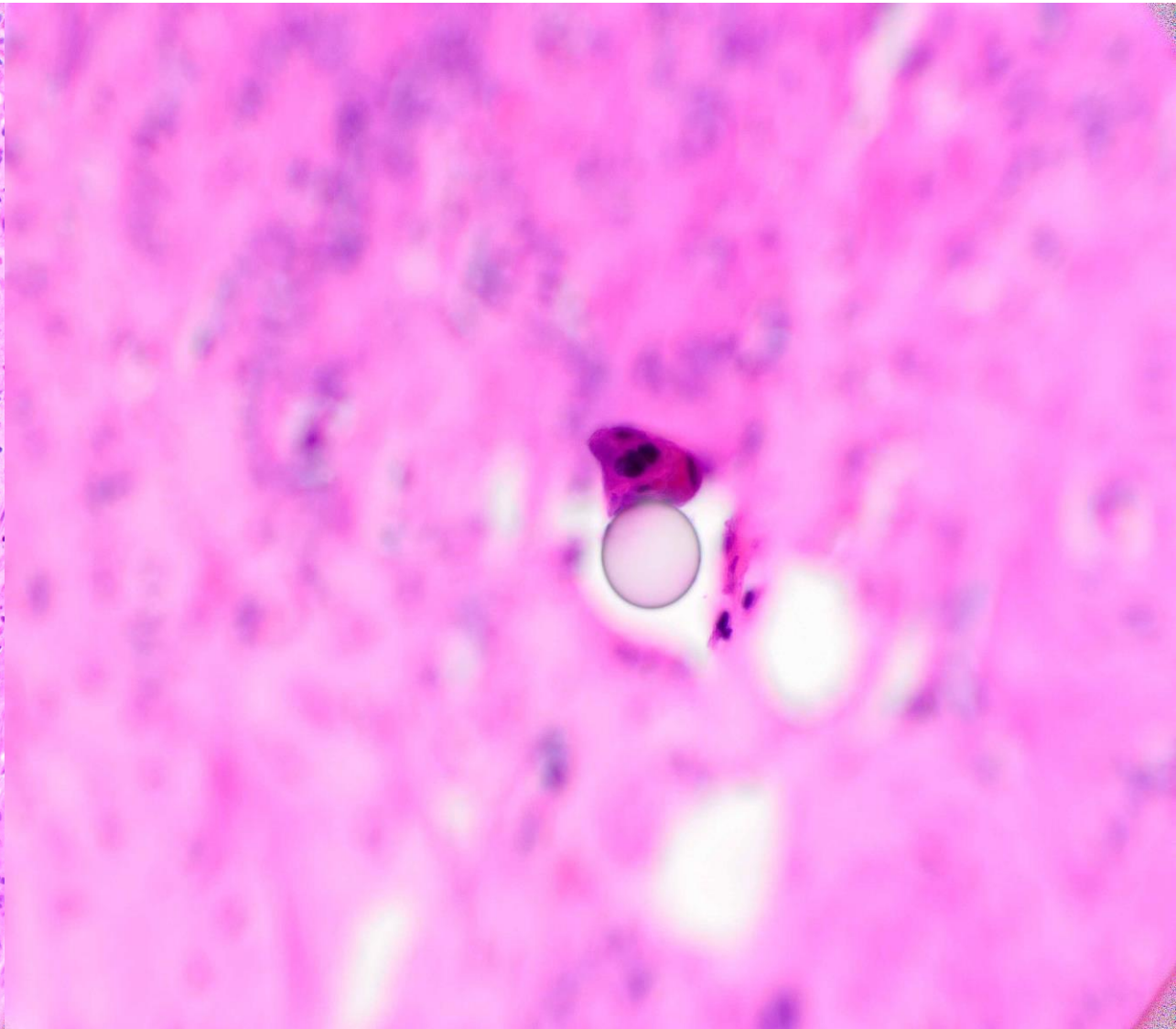

Classic yttrium beads – The new formula

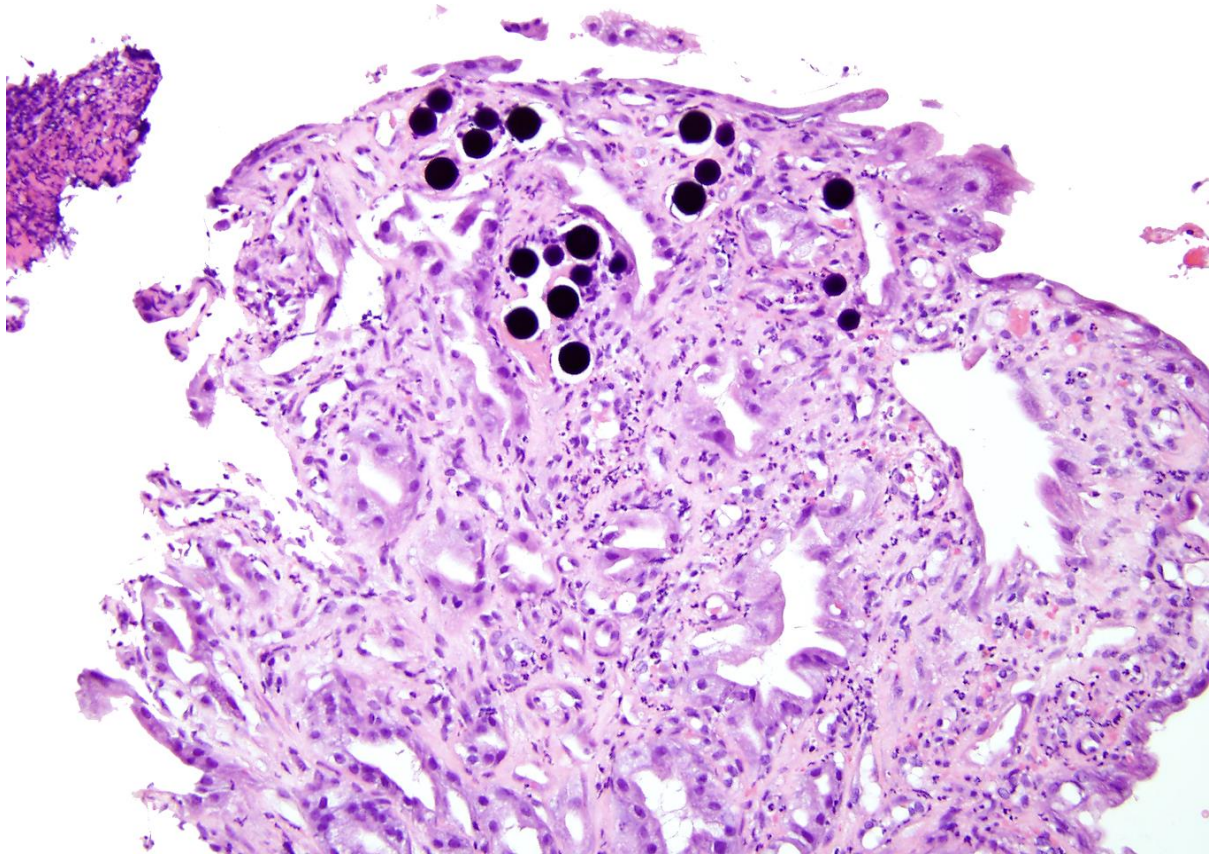

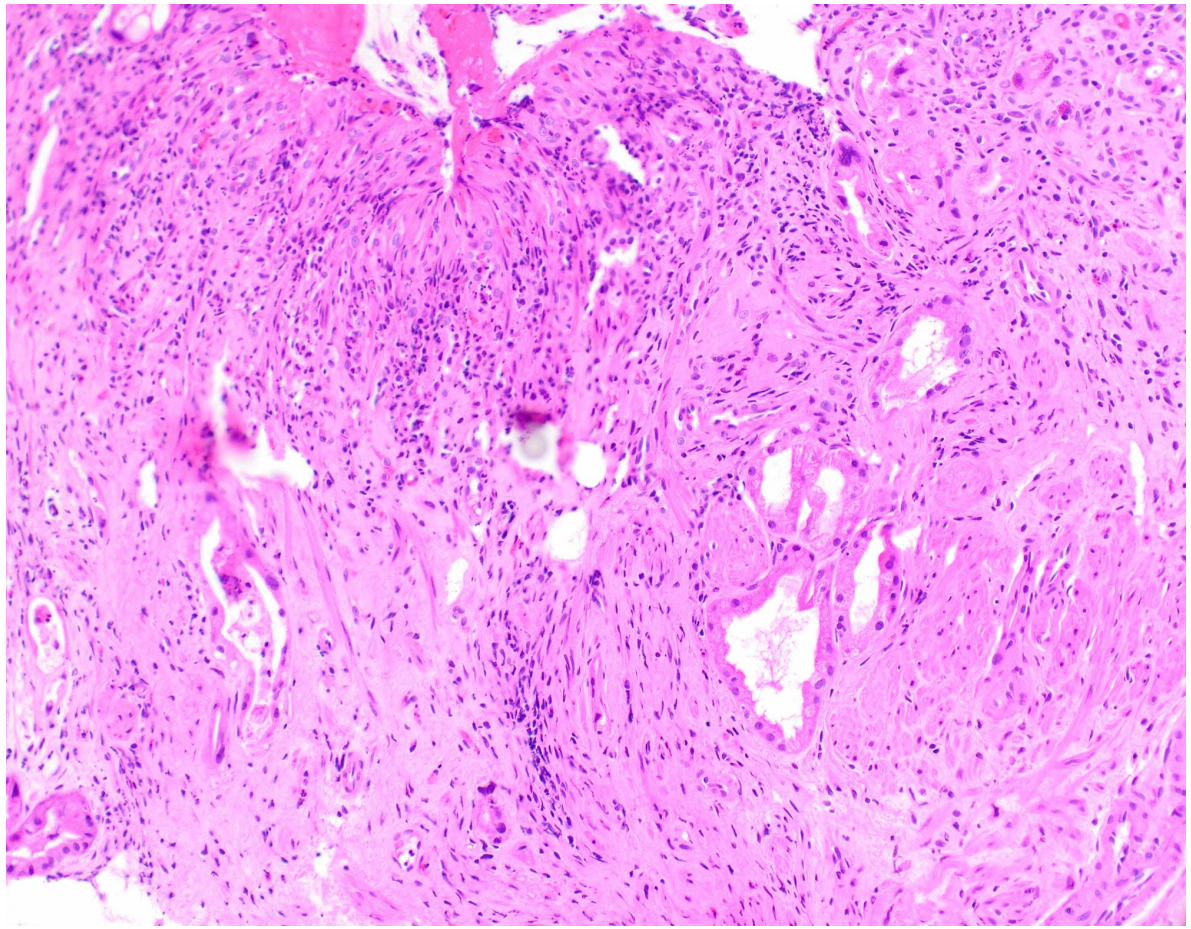

Summary

- We have considered normal esophagus, stomach and small intestine
- We have considered gastric neuroendocrine tumors
- We have reviewed a few mimickers and important upper tract patterns of injury
- THANK YOU